

ART. III.—*Hints on the Treatment of Lacerated Perineum from Parturition.*

By W. E. HORNER, M. D., Professor of Anatomy in the University of Pennsylvania; Senior Surgeon of the St. Joseph's Hospital, Philadelphia.

IN the year 1837, in a report of a tour of duty in the Philadelphia Alms-house Hospital, (see the *American Journal of Medical Sciences* for November of that year,) I offered a suggestion, founded on a case of lacerated perineum from parturition, of the propriety of dividing the sphincter ani muscle, where reunion was attempted in old cases. Owing to the intractable spirit of the patient, the experiment was defectively tried; but I remained disposed to make another trial of it upon a suitable occasion.

In October, 1848, I assumed the charge of a young married lady after her second accouchement, the accident under consideration having occurred in the first. The laceration was complete from vulva to anus; the parts were cicatrized over an inch or more deep, and but one fissure was apparent from near the os coccygis to the clitoris. The patient, of rather a full habit, and well organized in other respects, was rendered miserable and helpless by a constant tendency to diarrhœa, only to be restrained by the incessant use of opiates; and her life was unavoidably retired owing to her want of control over her natural discharges. Much of the fecal matter passed forward through the rima vulvæ, which added to the distress of her situation.

The operation was performed in the usual way, by paring off the cicatrix of each margin of the perineum, and then fastening it carefully with interrupted stitches along the rectal and along the vaginal edges of the cut; and, to secure more fully the permanency of contact, the sphincter ani muscle was divided on each side of the anus. Unfortunately, the menstrual flux came on prematurely; and it, with the natural discharges of the vagina, loosened everything like adhesion. The operation was a failure, though the bowels had been kept unopened for many days, so that no counteraction from fecal discharges had occurred.

This lady, with true feminine spirit and perseverance, not discouraged by the want of success, insisted on another trial, and, after a series of postponements for various reasons, I operated a second time, January 28, 1850, just fifteen months after the first trial. I need scarcely say that in the interval of the two operations her life had been of the same wretched kind as previously. I had now of course additional difficulties. The portion of perineum pared away in the former instance had reduced its extent; the slit from vagina into rectum had been elongated or deepened. If lateral adhesion had failed before, the failure now was still more probable. Under these considerations, I determined to modify the operation, so that if unsuccessful the patient should at least not be the worse off for my attempt. The following plan was accordingly arranged. Two flaps to be made from the perineum and adjoin-

ing part of the vulva, the one on the right of the patient and the other on the left, as follows:—

Fig. 1.

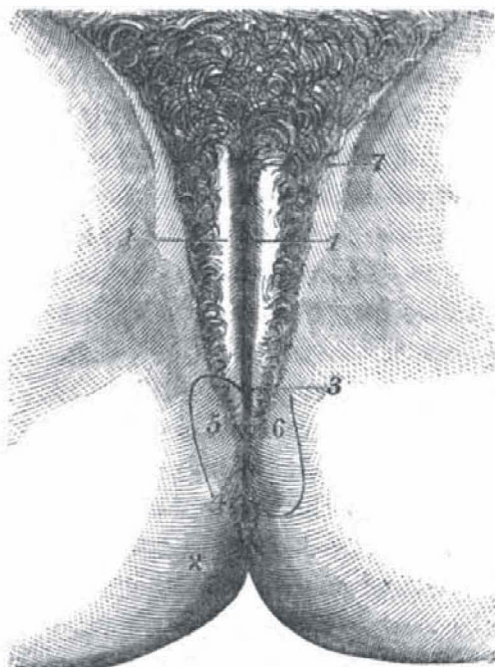


Fig. 1.

- 1, 1. Vulva.
- 2. Anus.
- 3, 4. Lacerated perineum.
- 5. Right flap.
- 6. Left flap.
- 7. Clitoris.

Fig. 2.

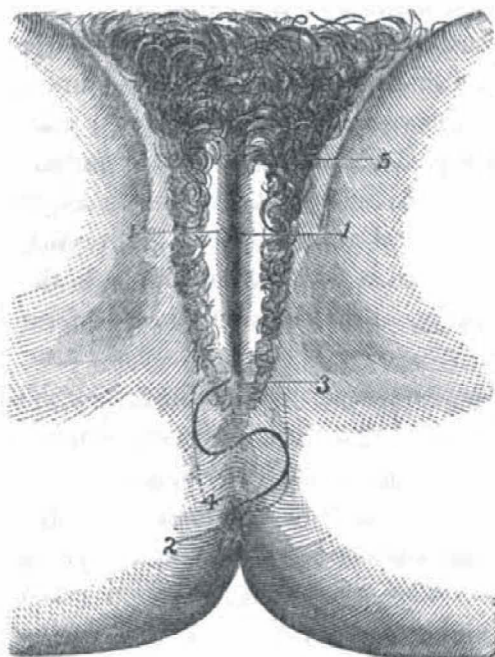


Fig. 2.

- 1, 1. Vulva.
- 2. Anus.
- 3. Upper or left flap.
- 4. Lower or right flap
- 5. Clitoris.

If, according to these figures, the base of the right flap be placed below, and the base of the left flap above, upon crossing the two flaps a partition will be formed between the rectum and vulva; there will be no loss of substance; the free side of the right flap will form the upper part of the rectum, and the free

side of the left the lower part of the vagina; and interrupted stitches along the rectum and along the vagina will secure the approximation of the flaps, and the contiguity of their raw surfaces.

In accordance with this plan, the operation was performed; the patient, as in the former instance, being under the influence of a mixture of chloroform and of ether. The right flap was fully and satisfactorily made. The left flap, owing to a sudden contraction, its transverse part being first made, was not as desired, but fell short of my intentions. The parts were adjusted and fixed with stitches. For the first ten days or so there was a strong indication of success. A large firm stool having then occurred, upon examining whether injury had been done, I found that either from it or from indisposition to unite the flaps had not adhered. But it pleased me much to see that they were in situ, so that the partition was kept up between the rectum and the vagina. The ligatures having all been detached, I found in a month after the operation that the left flap had shrivelled away almost to nothing; the right flap had lost one-half of its first size, but it still remained as a barrier between the two canals; and, with a linen compress introduced into the vagina and laid upon it so as to keep the flap in place, the discharge of feces was regulated, so that there was no diarrhoea, and no medicine was necessary to prevent it. The patient felt the call for defecation, could make timely provision for it, and was so much improved in her comfort that she considered herself a different being.

At this date, July 15th, 1850, on an examination of my patient, I find that things are improved very much. The appearance of an operation having been done has subsided, so that upon a superficial examination there appears to be a regular division between the anus and the vulva, a reproduction of perineum. The latter is, however, actually only the claustrum made by the operation; the edge of it is still loose, but yet it has the effect of directing the rectal discharges backwards, and the vaginal forwards. The recto-vaginal fissure has diminished much in depth, and the comfort of the patient has been vastly augmented. From having been for a long time in an absolutely helpless state, she began to participate in her house-work, and continued to do so until lately, when her diarrhoea was unfortunately reproduced by a visit to a region of limestone water. But with this disadvantage she says her feelings are more natural, and that she has a much better control of flatulent and fecal discharges than formerly, and is apprized of their approach. It yet remains to try whether, by a protracted application of the milder escharotics to the free edge of the new claustrum, a perfect adhesion of it may not be obtained. As the duration and success of this process are uncertain, the result may possibly be the subject of a future report.

It is sufficiently known that lacerations of the perineum in the female are easily treated when recent; after cicatrization, all candid writers view them as very serious and very intractable. If the preceding narrative should induce others to imitate this plan of operating, I would recommend the ver-

tical incisions of the flaps to be first made, as the relaxation of the tension of the parts affects much the state of the flap where the transverse cut is first made, and interferes with the plan of the operation. This is a matter of pure experience which had not entered into my first estimate of difficulties.