

## HYSTEROMYOMECTOMY, WITH A REPORT OF FOUR CASES.

BY HUNTER ROBB, M. D., *Associate in Gynecology to the Johns Hopkins Hospital, Baltimore, Md.*

(*Read before the Johns Hopkins Hospital Medical Society.*)

The removal of the uterus for large myomata becomes an operation of necessity in many cases, and the choice of a method will naturally be that securing the greatest amount of safety to the patient, and this hinges largely upon the treatment of the pedicle.

Many of the methods adopted in the past for the disposition of the pedicle neither secure asepsis at the time of operation nor afterwards: there is often, as well, an undue waste of time in carrying out the various steps of the operation. In passing judgment upon any operation of this kind one must think particularly of the dangers of sepsis and hemorrhage and of the length of time consumed. When the pedicle is dropped into the peritoneal cavity the hemorrhage has frequently been fatal, or sepsis has occurred from the stump. These two dangers have strongly militated against this method of treating the pedicle. Even in cases where the pedicle has been suspended, drainage has often been thought necessary to carry off fluid escaping from the stitch-holes and accumulating in the pelvis.

I do not believe that hemorrhage need ever occur with a proper careful treatment, any more than after the transfixion of an ovarian pedicle; nor should the dangers of sepsis be much greater.

In every case demanding operation I feel confident that the plan I have adopted and am about to describe can be followed. It is particularly suited to cases in which the uterus is involved throughout its substance, as it leaves the cervix for the most part intact, and permits the lower part of the uterus to be raised out of the pelvis.




FIG. 1.

Tumor *in situ* transfixed by needle carrying stout double ligature. Line of incision for removal of tumor indicated by .....

**Method.**—After opening the peritoneal cavity, the body of the uterus, the cervix and broad ligaments are carefully examined and the situation studied. The myomatous uterus is then grasped and lifted out of the abdominal cavity and wrapped in sterilized gauze, over which a sterilized salt solu-

tion at a temperature of 112° F. is poured from time to time. The broad ligaments on either side are divided close to the sides of the uterus, if possible, as far down as the utero-cervical juncture. This is accomplished either by passing a double row of ligatures of silk through the broad ligament, or by compressing it with a pair of long-nosed artery forceps on the side close to the uterus, and passing and tying a series of ligatures on the pelvic side. The broad ligament is cut through between these constricted portions and the uterus thus is separated from its lateral attachments. The tubes and ovaries are also removed, separately or with the uterus. (Fig. 1.) Where the cervix joins the body of the uterus a transfixion needle threaded with a double ligature is passed through the middle of the cervix, just as an ovarian pedicle is transfixed. This ligature is then tied both ways beneath the tubes and ovaries and the diseased mass. One of the ligatures is brought around the pedicle again to make the tie more secure. This should absolutely cut off all the active blood-supply. The constricted mass for a distance of 3-4 cm. above the ligature can then be rapidly and safely excised. It is cut off so that it leaves a cupped cavity surrounded by an abundance of peritoneum. Redundant tissue may be trimmed away afterward.

The position of the cervical canal is next noted, and the canal thoroughly burned out with a Paquelin's cautery, by plunging the fine point down it to prevent any possible infection from this source. Then a circular or rectangular (Fig. 2) ligature of silk or catgut is passed in and out of the

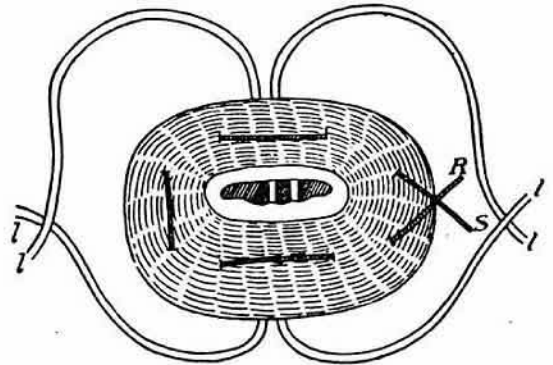


FIG. 2.

Tumor cut away. Looking down on cupped cervix from above. Ligatures shown loose. They should be tied before removing tumor. Rectangular suture in place.

cervical tissue and tied, closing the cervical canal, and another suture again outside of this, finally completely closing the canal. Interrupted sutures of silk or catgut now unite the peritoneal surfaces of the opposite sides of the pedicle, so as to invert the top of the pedicle and bring the peritoneal surfaces in apposition. (Fig. 3.)

The toilet of the peritoneal cavity is completed by pouring in one or two litres (one or two quarts) of a sterilized salt solution at a temperature of 112° F. This is both stimulating

and nutrient to the tissue-cells, injured during the manipulations. Blood-clots and serum are also thus flushed out. Finally the peritoneal cavity is dried by sponging. The ligatures encircling the pedicle are allowed to remain, the ends being cut short. (Fig. 4.)

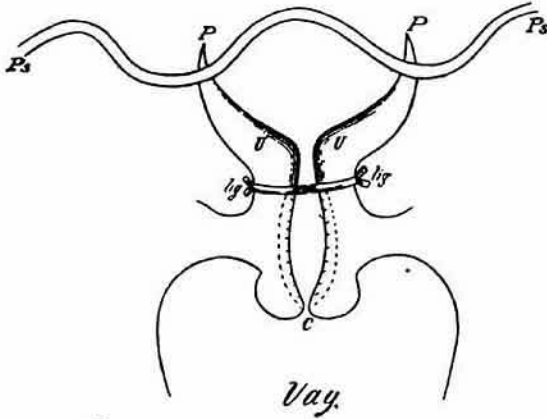


FIG. 3.

Vertical section through the pedicle, showing the extent of the cupping of uterus (U U), the application of the peritoneal suture (Ps) and the controlling ligatures (Lg) as before. Vag = vagina, c = cervix.

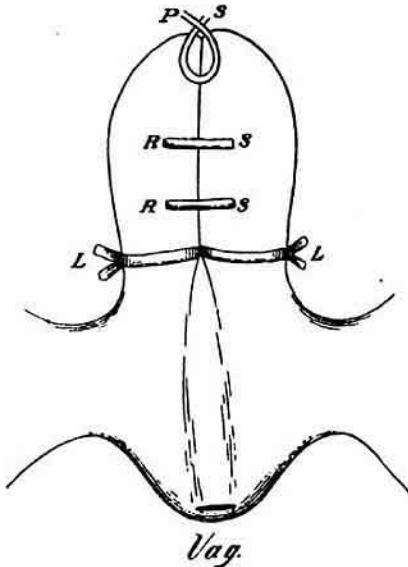


FIG. 4.

Shows stump completely closed with three sutures above the controlling ligatures. R s = rectangular cervical sutures, P s = peritoneal sutures drawn up.

The pedicle is not suspended but dropped, and the abdomen is closed without a drainage-tube. When a pedicle is treated in this manner there is no necessity for placing it in the lower angle of incision, to provide for hemorrhage; we also thus avoid the dangers of infection by contact with skin-surfaces which might contain virulent organisms. We further avoid the chances of bacterial invasion to which those cases in which the pedicle is allowed to slough off are subjected, as

well as the tedious and dangerous method of turning the pedicle into the vagina, which incurs the risk of infection from this surface. (Fig. 5.)

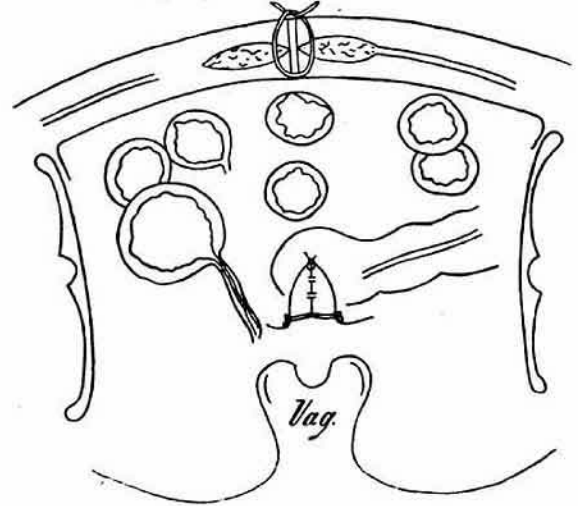


FIG. 5.

Shows coronal section of pelvis through crura of ilia, acetabula and tubera ischiorum; showing stump in situ after closure of abdominal wound.

*The ligatures must be carefully applied, and a sufficient stump made above them; if this precaution is observed there is no danger of the tissues shrinking sufficiently to draw away from the ligatures.*

In the four cases in which I have tried it, three were successful. The fatal result attending the fourth one was influenced by the low vitality of the patient preceding the operation, as shown by the autopsy. The first three cases convalesced as readily as the simplest ovariectomy; they were out of bed at the end of two weeks, and in three weeks and a half left the hospital well, the abdominal incision being perfectly healed, and no weak point remaining, as is the case when a drainage-tube is employed.\*

*Summary.*—This method of hysteromyomectomy recommends itself for the following reasons:

First—it is aseptic. A more consistent technique can be maintained after operation, and the dangers of subsequent infection can thus be avoided. *If septic material is introduced at the time of operation, the condition is not remedied at all by the suspension of the pedicle or the use of the drainage-tube, and in either case the patient may die if the organisms are of a virulent character.*

Second—hemorrhage is avoided. It controls bleeding efficiently both during and subsequent to the operation.

Third—drainage is not necessary. As there is no danger of hemorrhage, the drainage-tube can be dispensed with and the danger of infection by this means obviated and the increased liability to hernia in the incision prevented.

Fourth—time is saved. The details and steps of the operation are simple and may be rapidly carried out.

\*Since writing the above Dr. Kelly has operated three times after this manner. The patients recovered without any disturbance.

Fifth—convalescence is shortened. The period of convalescence should be no longer than after a simple ovariectomy.

#### DETAILED REPORT OF CASES.

CASE 1.—S. A. admitted to the Gynecological Department of the Johns Hopkins Hospital, August 4th, 1891, with the following history: Married 25 years; 10 para, oldest 21 and youngest 4 years old, no miscarriages; labors not difficult, except the first, which was instrumental. Menstruated first at 16, with much pain, compelling her to rest in bed for two days. Flow moderate in amount, lasting about one week. Last three years menses have been very regular, until the past six months, during which time the flow has been profuse, continuing for three or four days, without pain. Profuse leucorrhœa. Bowels inclined to be loose. No urinary difficulty. No history of serious illness. Complains of great pain in the left ovarian region, covering a space about the size of a silver quarter; pain paroxysmal, sharp and burning. Occasionally severe back-aches; scarcely able to be about at times.

Examination under anæsthesia, the following notes were recorded: Vaginal outlet relaxed, cervix pointing downward, lips soft and lacerated on the right side. Uterus reclines in the pelvis in ante-position. Just beneath the abdominal wall, above the symphysis pubis, a globular mass is palpated on the right side. The broad ligaments on either side are thickened by adherent masses, irregular in outline. This is most marked on right side.

*Diagnosis.*—Interstitial myoma with adherent tubes.

Urinary analysis, catheterized specimen, August 5th, 1891, cloudy and lemon-colored, sp. gr. 1011, reaction neutral, no albumen, but marked precipitate of phosphates. Epithelial cells and a few leucocytes.

*Operation.* August 15th, 1891, after the manner above described. Time of operation one hour and twenty minutes. Abdomen closed without drainage.

*Examination of Temperature Charts.*—The thermometer registered on the fourth day 101° F. by the rectum, 99.8° F. by the mouth, and 101.3° F. by the vagina. From this time on the temperature registered between 98.5° F. and 99.5° F. by the rectum, mouth and vagina.

The stitches were removed on August 23d. The line of union perfect, no suppuration. She was out of bed on the fourteenth day after the operation and was discharged from the hospital September 12th, thoroughly recovered.

CASE 2.—S. S. admitted to the Gynecological Department of the Johns Hopkins Hospital, August 20th, 1891, with the following history: Aged 35, married twice, first when 14 years old, married four years, widow seven years; second time married fifteen years; 2 para, oldest 19 and youngest 18 years old; two miscarriages, last miscarriage three months after the youngest child, with which she had "spasms" and was in bed two months with fever and swollen abdomen. First labor easy, second difficult. Menses appeared at 14, regular, lasting nine days, profuse, with great pain, obliged to be in bed three days. Pain all referred to lower abdomen. Has had profuse leucorrhœal discharges for the past five years. Frequent and painful micturition. Bowels constipated. Complains of continuous cutting pains in the lower zone of the abdomen, which are aggravated by any exertion, also has pain in right hypochondrium, back-ache and headache. Very nervous and unsteady. Patient fairly well nourished, anæmic, tongue pale and dirty. Examination under chloroform narcosis, August 20th, 1891. Examination of external genitalia: on left labia minora there is a small ulcer extending through the submucosa, and a larger one on the inner surface of the right labia majora, covered with a whitish fungus-like material. There are some small capillary-like projections along the right lower border of the posterior commissure. Vagina is bathed with a purulent-looking secretion, anterior vaginal wall prolapsing, cervix pointing downward, bilaterally lacerated, large, soft everted lips. Uterus reclining in the pelvis, the size of a fetal

head, movable, irregular in outline, especially noticeable on the posterior border. Right ovary prolapsed, slightly enlarged; left ovary thickened and adherent.

*Diagnosis.*—Myoma of the uterus with adherent left adnexa. Treatment advised, hysteromyomectomy.

*Urinary Analysis.*—Examination of catheterized specimen, clear amber color, sp. gr. 1020, acid reaction, no albumen, small amount of mucous sediment, leucocytes, epithelial cells, oxalates and amorphous urates.

Voided specimen, same characteristics with a heavy sediment, many leucocytes, and epithelial cells with granular debris.

*Operation* performed September 2d, 1891, according to method. The Fallopian tube and ovary on the left side were firmly adherent to the broad ligament. No drainage. Time of operation, one hour and fifteen minutes. Pulse after operation 108, full, regular and strong.

Sutures removed on the eighth day, line of union good, small amount of dark creamy fluid at the upper suture.

In this fluid at upper angle of incision one could easily demonstrate the skin-coccus, both microscopically and by agar-agar tube-cultures.

*Analysis of Temperature Chart.*—Temperature taken by mouth, rectum and vagina registered between 98.5° F. by the mouth and 101° F. by the rectum, and second day between 100.6° F. to 99.5° F. until the eighth day, when it increased to 102° F. by the mouth and 103° F. by the rectum, due in all probability to a small circumscribed abscess on the left buttock, after the opening of which the temperature declined. The patient sat up in bed on the sixteenth day and was out of bed on the seventeenth day following the operation. The wound was thoroughly united and she complained of no discomfort.

CASE 3.—G. Hoffman, aged 47, married, admitted to the Gynecological Ward of the Johns Hopkins Hospital, September 1st, 1891.

*Diagnosis.*—Interstitial myoma of the uterus. No satisfactory history could be obtained.

*Examination.*—Under chloroform narcosis. Vaginal outlet relaxed, cervix pointing downwards, deep bilateral laceration, anterior lip everted, thin and stretched out, uterus ante-flexed and reclining in the pelvis, lobulated, large as fetal head, movable, not adherent. Lateral structures cannot be clearly palpated, but there is no evidence of inflammatory trouble. Diagnosis of interstitial myoma of the uterus confirmed. Treatment advised, curettement. If hemorrhages persist, to perform hysteromyomectomy.

*Operation.*—September 4th, uterus was curetted and a small quantity of hemorrhagic fungosities removed. Churchill's tincture of iodine was then applied to the fundus and the vagina packed with permanganate gauze.

As the hemorrhage persisted, hysteromyomectomy was performed September 16th. Uterus was delivered from the pelvic cavity after the usual manner. The broad ligaments on either side were transfixed by a double row of ligatures and cut through. The steps of the operation as described were carried out. Time of operation, one hour. No drainage. Abdominal stitches removed on the eighth day, line of union good, skin at lower angle of incision reddened, but not indurated.

*Analysis of Temperature Chart.*—The temperature increased gradually on the third day following the operation; it registered 104.4° F. by the rectum, and 103.4° F. by the mouth. The abdomen and pulse were in good condition.

The physical signs of bronchitis and broncho-pneumonia existed in the upper portion of the left lung. The usual treatment was prescribed. The temperature decreased to normal until the seventh day, when it arose to 104.8° F. by the rectum and 102.6° F. by the mouth. On the eighth day the temperature was normal and continued so. She was allowed to be out of bed October 4th and was discharged October 22d. The wound was thoroughly united and the general condition good.

CASE 4.—J. H., admitted to Gynecological Department of the Johns Hopkins Hospital, September 14th, 1891.

*History.*—No children and no miscarriages; menses regular, lasting three to four days, with slight pain; no leucorrhœa; bowels irregular; appetite poor; frequent urination, rising two to three times a night; *complains of loss of blood, which has continued for the past three years*; has buzzing in the head; is very anæmic; has noticed the abdominal tumor for the past nine years.

*Examination.*—Vaginal outlet intact; cervix in the axis of the vagina; normal condition. The whole abdomen is distended with a large irregular mass, reaching above the umbilicus. In the right hypochondrium a tumor mass is outlined as large as an adult's head; this is attached by a narrow pedicle to the main tumor.

*Operation.*—September 23d, after the usual manner. The tumor attached to the right side of the mass was first removed in order to allow better manipulation of the main tumor mass. The uterus was then removed. Time of operation, one hour, fifteen minutes.

Patient's condition the first day following the operation good. On the third day the temperature rose to 105° F. by the rectum and the pulse became rapid, reaching 148. There was, however, no marked abdominal distension, and few indications of peritonitis. The abdomen became tympanitic, and she died September 25th at 4 A. M., on the third day following the operation.

*Autopsy.*<sup>1</sup>—Anatomical diagnosis. Operation, removal of uterus and appendages; peritonitis, apparently proceeding from abdominal wound, œdema and congestion of lungs; fatty degeneration of kidneys, heart and liver; anemia. Body 158 cm. long, strongly built, well nourished. In the anterior abdominal wall a linear incision in median line, 17 cm. long, closed by 11 sutures. The wound covered over with a dressing of iodoform and celloidin. Epidermis macerated along the edges of the wound, wound otherwise dry.

Abdomen slightly distended, omentum and intestines slightly adherent to abdominal wound. The anterior parietal peritoneum injected, cloudy and covered with slight exudation. Foci of ecchymosis in various places. Intestines somewhat distended, in places slightly adherent, cloudy, and covered with a very slight fibrinous exudation. Blood-vessels more injected than normal. In the peritoneal cavity about 50 cc. of bloody fluid. The entire pelvic cavity filled up with a bloody brick-dust colored fluid, and pretty well shut off from general peritoneal cavity by a projecting mass of tissue (the stump remaining from operation), and by adhesions of this to the intestines and peritoneal wall. In places between adherent loops of intestines there is considerable fibrinous hemorrhagic exudation.

*Lungs.*—Diaphragm on right side at lower border of third rib, on left side at fourth intercostal space. Both pleural cavities moist. Both lungs slightly adherent by a few old adhesions. Anterior borders of both lungs slightly emphysematous. The posterior

and inferior portions of left lung deeply congested and œdematous, with apparently small areas of more intense congestion, with very slight hemorrhage. Right lung shows essentially same condition.

*Heart.*—Both layers of pericardium smooth. Left ventricle firmly contracted. Myocardium pale, rather soft. In both ventricles fluid blood and dark clots. Thickness of left ventricle 18 mm., length 7.5 cm.; of right ventricle, 4 mm., length 8 cm. Aorta, 7 cm.; mitral, 9 cm.; tricuspid, 12.5 cm.; weight, 320 grms.

Liver and spleen free from adhesions. Liver weighs 1250 grms., small, size 23x15x7 cm. Surface smooth, border sharp, of light brown homogeneous color, with small opaque areas scattered over the surface. On section very pale, lobules not visible, opaque looking, the paler areas not so conspicuous as on surface. Bile-duct free. In gall-bladder a small amount of viscid dark bile.

*Kidneys.*—Weigh together 225 grms.; both have the same general appearance and size. Capsule easily stripped off. In both kidneys deep depressions from remnants of fetal lobulations, and in addition small irregular depressions. Color pale; stellate veins not injected. On section pale, markings very obscure. Cortex 6 mm. Distinction between cortex and pyramids not so clear.

Spleen of a pale red-brown color; capsule smooth; weight, 150 grms. Malpighian bodies not visible. Trabeculae visible, consistency firm.

Fundus of uterus, ovaries and broad ligament missing. A heavy ligature tied around the stump, at end of which there are interrupted ligatures. The whole permeated with iodoform. Stump is bloody and the numerous vessels enclosed in it are filled with coagula.

Adrenal glands and pancreas are exceedingly pale and opaque looking.

Intestines very pale in general. Opposite the portion where there was most peritoneal trouble there is an œdema of mucous membrane with considerable injection. Intestines filled with soft fluid contents. Stomach contains a large amount of chocolate colored fluid. Mucous membrane apparently slightly thickened, covered with large amount of mucus.

Microscopical examination of the kidneys shows most intense and diffuse fatty degeneration. Almost all the tubules are equally affected by the degeneration. This is especially marked in the convoluted tubules. Fat is in small drops and almost exclusively in the periphery of the tubes. The heart shows intense fatty degeneration; all the fibers affected. Section of the heart appears dark on examination. The fat is in very small drops and very diffuse.

The liver shows extensive fatty degeneration; all portions of lobules affected. Fat in small droplets.

Aorta small, smooth, with a few yellow foci. Bladder and vagina unchanged. Blood in heart and in the vessels generally very thin and pale. The peritonitis is most marked on the coils of intestines immediately beneath abdominal wound, and infection has probably taken place from this.

<sup>1</sup> From the Pathological Laboratory.