

WM. F. SMITH, M.D.  
238 MARLBOROUGH ST.  
BOSTON, MASS.

# ECTOPIC PREGNANCY

*ITS ETIOLOGY, CLASSIFICATION, EMBRYOLOGY,  
DIAGNOSIS, AND TREATMENT.*

BY


J. CLARENCE WEBSTER, B.A., M.D., F.R.C.P.ED.,

ASSISTANT TO THE PROFESSOR OF MIDWIFERY AND DISEASES OF WOMEN AND  
CHILDREN IN THE UNIVERSITY OF EDINBURGH.

*WITH EIGHTY ILLUSTRATIONS OF NAKED EYE AND  
MICROSCOPIC APPEARANCES.*

EDINBURGH AND LONDON:  
YOUNG J. PENTLAND.

1895.



A 25.C.1895.1

EDINBURGH : PRINTED FOR YOUNG J. PENTLAND, 11 TEVIOT PLACE, AND  
38 WEST SMITHFIELD, LONDON., E.C., BY SCOTT AND FERGUSON AND BURNES AND COMPANY.

[All rights reserved.]

TO MY FRIENDS

A. H. FREELAND BARBOUR

AND

D. BERRY HART.

## INTRODUCTION.

---

THE subject of Ectopic Pregnancy has received a great deal of attention during the last few years both in Europe and America. Though the importance of the subject might be considered a sufficient justification for the publication of a work which is an embodiment of the recent advances made in our knowledge of the nature and treatment of the condition, the author urges a stronger plea, viz., that he is able to bring forward for consideration a large body of original matter, based upon several years' clinical and laboratory work.

He desires especially to call the attention of the embryologist, and of the scientific teacher of Obstetrics, to the chapters on Development. The detailed observations therein presented are the outcome of a careful examination of a large amount of material taken from the operation room and *post mortem* theatre during the last six years. The investigations have been carried on in the Laboratory of the Royal College of Physicians, Edinburgh.

The author is also able, from an examination of the voluminous literature which he has collected, to bring to the light some interesting records of workers during the past three centuries, which have for a long time been overlooked.

Throughout the book, the word "Ectopic" is used in pre-

ference to "Extra-Uterine." The former term was first used by Robert Barnes in 1873. It includes all gestations developing outside the uterine cavity, being therefore more comprehensive than the term "extra-uterine," which, in strictness, cannot be held to include *interstitial* pregnancy.

Though *Cornual* pregnancy is considered in this work, it is not included in the classification of ectopic gestations, because, of course, this form of pregnancy is developed in relation to the cavity of the uterus, though the latter is mal-developed. It is necessary, however, to describe the condition in connection with ectopic pregnancy, because of the many resemblances between them.

The author is deeply indebted to Professor Simpson, Drs. Halliday Croom, Berry Hart, Freeland Barbour, and several other friends for the material which he has obtained from them; and also to Mr. Cathcart, Curator of the Museum of the Royal College of Surgeons, Edinburgh, for permission to investigate the specimens of ectopic pregnancy in his care.

Several illustrations are taken from the publications of Berry Hart, Orthmann, Bland Sutton, Sir Wm. Turner, and the author. The great majority of the plates, however, are from original water-colour drawings made by the author, and hitherto unpublished.

My thanks are due to Mr. James Y. Simpson, M.A., for his kind assistance in the revision of the proofs.

JOHN CLARENCE WEBSTER.

20 CHARLOTTE SQUARE,  
February 1895.

# CONTENTS.

---

## CHAPTER I.

### ETIOLOGY.

	PAGE
Place of fertilisation of ovum—Part played by epithelium of mucosa— Nature of menstruation—Changes in the non-pregnant tube—Decidual reaction—Improbability of ovarian pregnancy, . . . . .	1

## CHAPTER II.

### CLASSIFICATION.

Early described cases—Old classification—Opinions of old writers—Present views—Author's arrangement, . . . . .	16
---	----

## CHAPTER III.

### VARIETIES STUDIED IN DETAIL.

Ampullar tubal pregnancy—Extra-peritoneal pregnancy—Sub-peritoneo- abdominal pregnancy—Rupture into peritoneal cavity—Hæmatoma formation—Intestinal escape of fœtus—Tubo-peritoneal pregnancy— Cases of doubtful nature—Hæmorrhage into peritoneal cavity— Sequelæ of hæmatocele—Effect of blood on peritoneum—Tubal abortion—Hæmato-salpinx, . . . . .	38
--	----

## CHAPTER IV.

### VARIETIES STUDIED IN DETAIL—*continued.*

Interstitial tubal pregnancy—Changes in interstitial pregnancy—In- fundibular pregnancy—Cornual pregnancy—Wandering of ovum— Adipocere formation—Lithopædion formation—Placenta after fetal death, . . . . .	75
---	----

## CHAPTER V.

### GENERAL CONSIDERATIONS.

Age—Side of the gestation—Repeated ectopic gestation—Plural ectopic gestation—Intercurrent uterine gestation—Hernia of ectopic gestation, . . . . .	105
--	-----

## CHAPTER VI.

## DEVELOPMENTAL CHANGES.

	PAGE
Changes in the tube wall—Peritoneum—Muscular part of the wall— Decidua vera—Decidua serotina—Changes in decidua—Decidua reflexa —Relations between ovum and decidua—Fœtal epiblast—The chorion —Placental chorion—Villi and decidua—Non-placental chorion—The amnion, . . . . .	118

## CHAPTER VII.

## SYMPTOMS AND SIGNS.

Symptoms resulting from the pregnancy <i>per se</i> —Periodic colicky pains— Discharge of uterine decidua—Stirrage—Abdominal enlargement— Fœtal movements—Changes in the uterus—Phenomena occurring at full term—Spurious labour—Bimanual examination—Symptoms re- sulting from complications—Pressure effects—Pain—Hæmorrhage— Suppuration—Death of fœtus, . . . . .	158
--	-----

## CHAPTER VIII.

## DIAGNOSIS.

Uterine pregnancy—Retroversion of the gravid uterus—Ovarian tumours —Hæmatocele and hæmatoma—Inflammatory exudations—Malignant disease—Spurious pregnancy, . . . . .	190
--	-----

## CHAPTER IX.

## TREATMENT.

Injection of drugs—Compression of the gestation sac—Electricity— Elytrotomy—Modern treatment—Tubal pregnancy—Interstitial preg- nancy—Rupture into peritoneal cavity—Rupture into broad ligament —Extra-peritoneal development—Secondary rupture—After spurious labour—Suppuration, . . . . .	207
---	-----

## LIST OF ILLUSTRATIONS.

---

### I.—PLATES.

(From Drawings by the Author.)

#### PLATE

- I.—FIG. 1. Muscular wall of tube in full time pregnancy.  
2. Ampullary part of tube with abnormal mucosa, showing decidual formation.  
3. Another of the same.
- II.—FIG. 1. Ampullary part of tube with abnormal mucosa.  
2. A small portion of normal ampullary mucosa.  
3. A small portion of normal tube wall between mucosal fringes.
- III.—FIG. 1. Decidual formation in tubal mucosa.  
2. Normal fringe of mucosa.  
3. Fringe from tube showing decidual changes.  
4. Decidual tissue torn up by blood.
- IV.—FIG. 1. Decidual formation in tubal mucosa.  
2. Another of the same.
- V.—FIG. 1. Another of the same.  
2. Another of the same, showing spongy layer of decidua.
- VI.—FIG. 1. Decidual changes in tubal mucosa.  
2. Another of the same.  
3. Gland spaces in compact layer of decidua.  
4. Villus attached to decidua.
- VII.—FIG. 1. Villus embedded in decidua.  
2. Compact layer of decidua.  
3. Fœtal epiblast in relation to decidua.
- VIII.—FIG. 1. Another of the same.  
2. Villi in relation to decidua at full time.  
3. Another of the same.
- IX.—FIG. 1. Section through early placenta and tube wall.  
2. Decidua reflexa, with amnion and chorion.



## PLATE

- X.—FIG. 1. Decidua serotina.  
 2. Decidua serotina and trophospongia formation.  
 3. Another of the same.
- XI.—FIG. 1. Fœtal epiblast, absorbing decidual tissue.  
 2. Villus attached to serotina.  
 3. Changes in artery of decidua.
- XII.— Section through tube wall and edge of placenta.
- XIII.— Decidua reflexa and tube wall outside it.
- XIV.—FIG. 1. Endothelial changes in blood-sinus of decidua.  
 2. Another of the same.  
 3. Membranes in relation to blended vera and reflexa.  
 4. Another of the same.
- XV.—FIG. 1. Another of the same.  
 2. Villus in relation to decidua serotina.  
 3. Another of the same.  
 4. Another of the same.
- XVI.—FIG. 1. Another of the same.  
 2. Another of the same.  
 3. Another of the same.  
 4. Fœtal epiblast and early villus.
- XVII.—FIG. 1. Reticulated fœtal epiblast in relation to decidua.  
 2. Blood-sinus of decidua in relation to intervillous space.
- XVIII.—FIG. 1. Blood-space in decidua.  
 2. Amnion and chorion.  
 3. Another of the same.
- XIX.—FIG. 1. Another of the same.  
 2. Another of the same.  
 3. Another of the same.  
 4. Another of the same.
- XX.—FIG. 1. Early villus formation.  
 2. Another of the same.  
 3. Another of the same.  
 4. Section of early villus.  
 5. Another of the same.  
 6. Another of the same.
- XXI.—FIG. 1. Villi in full time placenta.  
 2. Villi in relation to decidua at full time.
- XXII.—FIG. 1. Superficial layer of uterine decidua in tubal gestation.  
 2. Deep layer " " " " "

## II.—FIGURES IN THE TEXT.

FIG.	PAGE
1. Sagittal lateral section (right) of pelvis, with subperitoneo-pelvic gestation in right broad ligament. (HART), . . . . .	36
2. Sagittal mesial section of pelvis, with subperitoneo-pelvic gestation. (HART), . . . . .	38
3. Sagittal mesial section of abdomen and pelvis, with advanced subperitoneo-abdominal gestation. (HART), . . . . .	40
4. Sagittal lateral section of abdomen and pelvis, with advanced subperitoneo-abdominal gestation. (HART), . . . . .	41
5. Another sagittal lateral section of the same subperitoneo-abdominal case. (HART), . . . . .	42
6. Another sagittal lateral section from the same case. (HART), . . . . .	48
7. Vertical mesial section of body, with tubo-peritoneal gestation, . . . . .	54
8. Transverse section of pelvis in tubo-peritoneal gestation, through fourth sacral vertebra and subpubic ligament, . . . . .	55
9. A higher transverse section in the same tubo-peritoneal case, made through the junction of the first and second sacral vertebrae and the upper part of symphysis, . . . . .	56
10. Another transverse section through abdomen in same tubo-peritoneal case, made at level of junction of third and fourth lumbar vertebrae, . . . . .	57
11. Left tubal pregnancy, 1-2 months, longitudinal section. (OETTMANN), . . . . .	71
12. Interstitial pregnancy. (BLAND SUTTON), . . . . .	77
13. Pregnancy in a rudimentary horn. (TURNER), . . . . .	88
14. Ruptured tubal pregnancy at end of second month. (BANDL), . . . . .	165
15. Sagittal mesial section of pelvis, with subperitoneo-pelvic gestation on right side. (HART), . . . . .	188

# ECTOPIC PREGNANCY.

---

## CHAPTER I.

### ETIOLOGY.

UNTIL recently the occurrence of Ectopic Gestation has been attributed to the following conditions :—

1. *Those mechanically interfering with the passage of the ovum to the uterus, e.g. :—*

- Peritonic bands constricting the Fallopian tube ;
- Polypi in the tube lumen ;
- Tumours of its wall ;
- Tumours of surrounding parts pressing upon it ;
- Abnormal foldings of its wall ;
- Diverticula from the lumen in the wall ;
- Displacements and hernia of the appendages.

2. *Those interfering with the peristaltic action of the tube, e.g. :—*

- Adhesions between the tube and neighbouring parts ;
- Thickening of its walls by inflammation.

3. *Those destroying the ciliary action of the epithelial cells lining the tubal mucosa, e.g. :—*

Endosalpingitis.

I think it is unnecessary to mention various mental and moral conditions, *e.g.*, fright, strong passion, &c., at time of

coitus, cited by Astruc,<sup>1</sup> Ramsbotham,<sup>2</sup> Baudelocque,<sup>3</sup> and others, as causes of ectopic gestation.

A careful analysis of these various conditions, hitherto described as the *causes* of tubal pregnancy, leads to the conclusion that the views current in regard to the subject are hazy and indefinite, their acceptance involving numerous contradictions as well as certain assumptions which are based entirely upon speculation, and, in some instances, not in accordance with facts. One of these assumptions is to the effect that in normal pregnancy the ovum becomes fertilised in the Fallopian tube; another, that this always takes place in the uterus. A very widely held view is that a fertilised ovum will grow in a tube with a *healthy normal mucosa* if it merely be prevented by some mechanical obstruction from reaching the uterine cavity; another assumption of more recent origin is that this cannot take place, but that development will only occur when the epithelium of the mucosa has been destroyed by inflammation.

That the above tabulated conditions have been founded upon observations is undoubtedly true. To associate them in some way with the occurrence of the tubal pregnancy is natural; *but to establish them as the ultimate or essential factors in its causation is anything but logical.*

It is my endeavour in this chapter to analyse carefully the relationship which these conditions bear to ectopic gestation, and to endeavour to allot to them their true proportional values as factors in its causation. In addition, I desire to bring forward some new observations in the hope of removing many of the difficulties connected with the subject, and of establishing a more scientific basis for its future investigation.

<sup>1</sup> "Traité des Maladies des Femmes," Paris, 1675, tome iv., p. 69.

<sup>2</sup> *Lond. Med. Gaz.*, 1849, N. S., vol. viii., p. 651.

<sup>3</sup> "Dict. d. sc. méd.," tome xix., p. 399.

It is necessary, in the first place, to consider one question which has an important bearing on the subject, viz., where the spermatozoa fertilise the ovum. It is generally believed that their meeting place is normally the Fallopian tube. Lawson Tait, Wyder, and a few others, believe that it is the uterine cavity; they hold that the ciliary action of the epithelium of the tubal mucosa prevents normally the spermatazoa from passing into the tubes.

Mr. Tait's words<sup>1</sup> are:—"The uterus alone is the seat of normal conception; as soon as the ovum is affected by the spermatozoa it adheres to the mucous surface of the uterus; the function of the ciliated lining of the Fallopian tubes is to prevent spermatozoa entering them, and to facilitate the progress of the ovum into the proper nest; . . . the plications and crypts of the uterine mucous membrane lodge and retain the ovum either till it is impregnated or till it dies or is discharged."

Without referring to the lower mammals, regarding which but scanty observations have been made, facts derived from the study of ectopic human pregnancy furnish evidence in favour of the view that spermatozoa can make their way from the uterine cavity into the tube lumen, whose lining epithelium may be healthy. It is not uncommon to find an early tubal pregnancy in the outer end of a tube whose inner end is perfectly normal. Such cases have been examined by Bland Sutton,<sup>2</sup> Martin,<sup>3</sup> Veit,<sup>4</sup> myself, and others. This being so, it is difficult to know why fertilisation may not take place in the tube in any number of cases where the parts are entirely healthy.

That it may also take place within the uterine cavity cannot, of course, be denied. The truth is probably that the sperma-

<sup>1</sup> "Diseases of Women and Abdominal Surgery," 1889, vol. i., p. 439.

<sup>2</sup> "Surgical Diseases of the Ovaries and Fallopian Tubes," 1891, p. 310.

<sup>3</sup> "Ueber ektop. Schwang." *Berl. klin. Wchnschr.*, 1893, Nr. 22.

<sup>4</sup> *Ztschr. f. Geburtsh. u. Gynäk.*, Stuttgart, bd. xxiv., p. 2.

tozoa are capable of working their way into both uterus and tubes, fertilising the ovum wherever they chance to meet it.

Another important question to be considered is the following:—*Is there any ground for supposing that a fertilised ovum can develop in the normal mucosa of the Fallopian tube?* That such a thing is possible has long been believed, especially by those who have insisted on the importance of mechanical obstruction as a cause of tubal gestation.

If the genital tract be studied phylogenetically, it is found that in the lowest animals there is no marked distinction between oviduct and uterus; that, in higher forms, each lateral tube becomes differentiated into an upper oviduct portion and a lower uterine portion; and that, in the very highest forms, the lowest portions blend into a single uterus. In these highest mammals only the uterus is able normally to furnish the place of development for the ovum; the upper ends of the original lateral tubes, *i.e.*, the oviducts or Fallopian tubes, though remaining in continuity with the uterus, retain only the power of carrying the ovum from the ovary to the uterus. The tubal mucosa and that of the uterus (*corpus uteri*) behave differently in the reproductive process—the former is passive, the latter active; the one undergoes no important changes, the other reacts markedly to the genetic influence, becoming transformed into the decidua, which is, it must be believed, essential to the attachment and development of the young ovum.

The differentiation is as well marked as that between the lining membranes of the œsophagus and stomach. There is no more authority for supposing that the normal tube can perform the function of the uterus than for believing that the œsophagus can perform that of the stomach. In each of these cases the evolution of structural differences has been accompanied by marked functional differentiation.

No doubt the resemblance between the epithelial cells of the uterine and tubal mucous membranes and their direct continuity have helped to establish the assumption that the ovum can develop in relation to one set as well as in relation to the other. Such an assumption is, of course, entirely unwarranted, because structural similarities do not necessarily imply physiological harmonies or identical reaction tendencies.

Moreover, all recent work, *e.g.*, that of Minot,<sup>1</sup> Hart and Gulland,<sup>2</sup> myself,<sup>3</sup> and others, goes to show that the lining epithelium of the mucosa, both in tubal and uterine gestation, plays an entirely negative part as regards the development of the ovum.

Next, what is to be said regarding the statements that the ovum can develop in the tube only when the lining epithelium has been destroyed by inflammation?

It might be sufficient, in refutation of this belief, only to mention those cases of tubal pregnancy in which no inflammatory or other diseased condition is found in the mucosa. Moreover, in some of the cases in which inflammation is found, there can be no doubt that it follows upon the disturbances in the tube attendant upon the development of the gestation. This has been strongly urged of late by Martin,<sup>4</sup> whose recent observations have led him to give up his older views<sup>5</sup> regarding the part played by endosalpingitis in causing tubal pregnancy.

Bland Sutton<sup>6</sup> is of the opinion that the so-called causal relation between desquamative salpingitis and tubal gestation is mere speculation which contains an element of truth, but does *not* hold in all cases. He points out that where the inflammation is so severe as to destroy the tubal epithelium,

<sup>1</sup> "Uterus and Embryo," *Journ. Morphol.*, Boston, April, 1889.

<sup>2</sup> *Rep. Lab. Roy. Coll. Phys.*, Edin., vol. iv.      <sup>3</sup> See Chapter on Development.

<sup>4</sup> *Op. cit.*, *vide supra*.

<sup>5</sup> *Ztschr. f. Geburtsh. u. Gynäk.*, Stuttgart, bd. xiii., p. 298.      <sup>6</sup> *Op. cit.*, p. 309.

stricture and occlusion of the outer end of the tube usually occur as well; it is very rare to find tubes denuded of their mucosal epithelium and with a patent fimbriated end.

One might also justly state that, whereas inflammation in the endometrium is not favourable to the development of uterine gestation, so inflammation in the tubal mucosa is *unfavourable to the development of a tubal pregnancy*.

I wish, however, to consider this statement as part of a more comprehensive idea which has been strongly urged of late, more particularly by Lawson Tait,<sup>1</sup> and also by Berry Hart,<sup>2</sup> viz., *that the human ovum can graft itself only on a connective tissue from which the covering epithelium has been removed*. Mr. Tait holds especially that in normal uterine pregnancy this supposed necessary raw surface is prepared by menstruation, as was first suggested by Pflüger, and in tubal pregnancy by endosalpingitis. In referring to the uterus he used the words "*a healthy mucous surface freshly denuded*;" and in reference to the tube he says that "*a desquamative salpingitis could put the mucous lining of the tube into a condition exactly similar to that of the uterus*." This statement is open to the criticism that, while a resemblance might possibly be pointed out between an endometrium partially denuded and an early acutely inflamed mucosa, there is not a very close resemblance in the case of chronic inflammatory surface.

That these authors are right in insisting upon the passive and unimportant part played by the epithelium of the mucosa, both in the case of tubal and uterine pregnancy, cannot be too strongly urged. All the latest embryological investigations give support to the view that the attachment and early development of the ovum takes place entirely in relation to the subepithelial connective tissue of the mucosa. I take excep-

<sup>1</sup> *Op. cit.*, p. 439.

<sup>2</sup> "Selected Papers," 1893, p. 61.



tion, however, to the explanation of the early establishment of this relationship in normal pregnancy, on account of the great difficulties in the way of believing that menstruation is the process essential to the removal of the epithelium and the consequent laying bare of the connective tissue. These difficulties are as follows:—

1. Pregnancy may occur in a girl before the onset of menstruation, at a time, therefore, when the mucosa cannot be denuded by that process.

2. It may occur late during the period of lactation when there is no menstruation and after the mucosa has been completely renewed.

3. It may take place at the menopause during a period of amenorrhœa.

4. Pregnancy may occur in the rudimentary horn of a malformed uterus, menstruation never having taken place in that horn (*vide* p. 92).

5. It may occur in periods of amenorrhœa associated with diseased conditions, *e.g.*, anæmia, phthisis.

6. Clinical experience of cases of pregnancy following a single coitus shows that the ovum may begin to develop at any time—not necessarily immediately after menstruation. (*Evidence in regard to this point, however, is of doubtful significance, owing to the uncertainty in our knowledge as to how long the spermatozoa may remain in the genital tract, and how long the ovum may take in some cases to reach the uterus.*)

7. In the great majority of the mammals menstruation does not take place, and in many of them we know that the early ovum develops in relation to the connective tissue of the mucosa, the superjacent epithelium being removed by the ovum itself.

Indeed, it is not at all necessary to look to menstruation as the process by which the epithelium is removed. The absorptive

power of the trophoblast or outer layers of the foetal epiblast is an important factor in bringing about its disappearance. My recent studies in early tubal pregnancy lead me to believe that this is also accomplished partly by another agency, viz., the rapid changes in the connective tissue of the mucosa leading to the formation of the *decidua vera*, causing the covering epithelium to be stretched and broken up.

Regarding the exact nature and significance of menstruation we are still ignorant. The opinion of Hirsch,<sup>1</sup> Slavianski,<sup>2</sup> Reeves Jackson,<sup>3</sup> Lawson Tait,<sup>4</sup> and others, that ovulation and menstruation are entirely independent of one another, can scarcely be disputed. The recent work of Heape<sup>5</sup> is confirmatory of this belief; he examined the genitals of *Semnopithecus entellus* in forty-two cases of menstruation, and found that only in two was there any evidence of a discharge of ova from the ovaries. It seems certain that ovulation does not necessarily take place during menstruation, and that menstruation is not due to ovulation.

The views of Leopold and Mironoff,<sup>6</sup> who have lately worked at this subject, are as follows:—

“Ovulation usually accompanies menstruation, though not always. Menstruation depends upon the presence of the ovaries and a well-formed uterine mucosa. Ovulation usually coincides with menstruation; it rarely occurs in normal conditions between the menstrual periods.”

There is considerable evidence in favour of the view that the menstrual function is connected with a special nervous mechanism. Christopher Martin,<sup>7</sup> in his recent paper on this subject, thinks that there is reason to believe:—

<sup>1</sup> *Schmidt's Jahrb.*, Leipzig, 1850.    <sup>2</sup> *Arch. de physiol. norm. et path.*, Paris, 1874.

<sup>3</sup> *Am. Journ. Obst.*, N.Y., Oct. 1876.

<sup>4</sup> *Op. cit.*, p. 300 *et seq.*

<sup>5</sup> *Proc. Roy. Soc. London*, vol. liv., p. 169.

<sup>6</sup> *Arch. f. Gynaek.*, Berlin, bd. xlv., hft. 3.

<sup>7</sup> “The Nerve Theory of Menstruation,” *Med. Press and Circ.*, London, 1893, vol. lv., p. 420.

- (1.) That menstruation is a process directly controlled by a special nerve centre.
- (2.) That this centre is situated in the lumbar part of the cord.
- (3.) That the changes in the uterine mucosa during the period are brought about by katabolic nerves, and during the interval by anabolic nerves.
- (4.) That the menstrual impulses reach the uterus either through the pelvic splanchnics or the ovarian plexus, possibly through both.
- (5.) That removal of the uterine appendages arrests menstruation by severing the menstrual nerves.

There can be little doubt that menstruation is not necessary to conception. The view of Hirsch, Lawson Tait, and others is that menstruation in the human female and rut in lower animals are different processes.

Regarding the extent to which menstruation occurs in the *primates* we are as yet ignorant, nor are we aware of the changes brought about by the change from the wild state to captivity. We are also in want of evidence in regard to menstruation among the lowest races of man, and also in regard to the variations which result when these races are civilised.

There is much difference of opinion regarding the anatomical changes in the uterine mucosa during menstruation. The latest evidence points clearly to the view that there is but a slight denudation, irregular in distribution in the superficial layers of the mucosa.

Having thus considered these important questions, I wish now to bring forward certain facts which seem to me of sufficient importance to suggest a sound basis for an explanation of the occurrence of ectopic gestation.

I have referred to the gradual evolution of the Fallopian tube

and uterus, and to the marked differences in function which exist between them in the human female.

Hitherto it has been believed that in every case of uterine gestation the decidual changes in the mucosa which are apparently essential to the early ovum, and which result from some sympathetic reaction following its fertilisation, take place only in the body of the uterus, the tubal mucosa remaining unchanged. This view is based upon the microscopic examination of the tubes in normal pregnancy. It is also held that in cases of single tubal pregnancy, while the uterine mucosa undergoes marked decidual change, the non-pregnant tube of the other side remains practically unaltered. Recent observations which I have made prove that the latter statement is not accurate, and throw some doubt upon the value of observations made upon the tubes in pregnancy. To study these points thoroughly it is necessary to examine serial sections of *every part of the tube, not of one part only, as is usually done.*

The observations to which I refer will be found on pp. 120, 121. They may shortly be recapitulated here. In examining a large number of tubal gestations, *I have found marked differences in the extent to which a decidua vera is formed.* In some cases only a small part of the mucosa undergoes this change, in others a large part. In no case is there an absence of decidual formation. In those instances in which I obtained the non-pregnant tube (only in *post-mortem cases*), I always examined a small part of it. In one case, however, in which the tube was enlarged in its ampullary portion, I made a thorough examination of every part of it, and found to my great surprise that an irregular ring-like portion of the ampullary mucosa, in its entire circumference, differed markedly from the rest of the mucosa, as well as from the mucosa of every tube that I had examined. The differences consisted, in the first place, in *a simpler arrange-*

ment of the folds than is found in the normal ampulla; they were much fewer in number, shorter, and only slightly branched. In the normal ampulla the delicate branching mucous fringes, as seen on transverse section, practically fill the tube lumen. In this case they formed thick projections, club-shaped, finger-shaped, wart-shaped, etc., extending inwards only for a short distance. In the second place, this part of the ampullary mucosa showed marked decidual formation, the large cells resembling exactly those found in the uterus in normal pregnancy.

The tube of the opposite side (the left one) was about two months pregnant, and the uterine mucosa showed marked decidual changes; the left ovary contained a *corpus luteum*, the right one (that on the non-pregnant side) containing none.

This case is most instructive. It emphasises most strongly that decidual formation is due to the influence of the *fertilised ovum* in the genital tract; that this influence can act at a distance, direct contact of the ovum not being necessary; that while in tubal pregnancy the uterine mucosa always undergoes this change, the tube of the other side may also sometimes be similarly affected.

In another case of an early tube pregnancy which I have recently examined, a large part of the non-pregnant tube possessed a mucosa entirely different from the normal tubal mucosa. Instead of consisting of a series of folds, it presented more of the appearance of the uterine mucosa, being of more or less uniform thickness, and filled with gland spaces lined with columnar epithelium. Only here and there did a partially formed fold exist. In the connective tissue stroma of the mucosa decidual cell formation was found in different places.

The uterus was well formed and normal.

All these facts, it seems to me, taken along with those relat-

ing to the evolution of the uterus and Fallopian tubes, suggest a hypothesis which lends itself to a satisfactory explanation of all the well recognised forms of ectopic gestation.

Among those animals (some non-mammalians) possessing a genital tract, the least specialised condition is that in which there is no distinction between oviduct and uterus, in which the tract is bilateral, and in which the ova may develop practically along its whole extent. In higher forms—certain mammalians—differentiation has occurred in the Müllerian ducts, as I have already described. In many of these, *e.g.*, cat, with bicornuate uterus, several ova develop in the whole extent of each horn, the mucosa undergoing the necessary decidual changes. In cases of human bicornuate uterus, usually only one ovum develops in one horn; in other cases, one may develop in both horns; in rare instances, two may develop in one and one in the other.

In other forms with bicornuate uterus, *e.g.*, cow, only one ovum, as a rule, develops in one of the horns, *but the mucosa of both horns undergoes, as a result of the genetic influence, marked decidual changes*; the same thing may be found in pregnancy in the *uterus bicornis* in the human female; these changes are, in the case of the non-pregnant horn, as far as we know, entirely unnecessary to the development of the ovum in the other horn. It is well known that pregnancy may go on perfectly well in cases where one horn is absent. When we come now to the human female, in which the single uterus exists, we find that the decidual changes induced by pregnancy in the great majority of cases take place only in the uterine mucosa where the ovum normally grows.

However, in some cases, as I have shown, the tubal mucosa can, in great or small extent, respond to the genetic influence, as well as that of the uterus. This is probably because of some developmental fault whereby there is reversion either of structure

or reaction tendency in the tubal mucosa to an earlier type in mammalian evolution—I mean that in which a larger portion of the Müllerian ducts showed decidual reaction.

Because of these occasional changes in the Fallopian tube, conditions are brought about capable of establishing with a fertilised ovum that relationship which is essential to its development.

If, then, the deduction be established that it is possible for a fertilised ovum to grow only in relation to that part of the genital tract, whether tube or uterus, in which the genetic reaction occurs, the explanation is evident, why in the human female a pregnancy may occur *sometimes* in a part of the genital tract outside the uterine cavity.

When the above mentioned conditions exist, in any case, several factors determine whether a fertilised ovum shall develop in the tube or uterus.

The place of fertilisation of the ovum is important. Ectopic gestation probably only occurs when this takes place in the tube above the part of the mucosa showing the decidual reaction. When it occurs in the uterus, the gestation will only take place there. Fertilisation may occur in that tube which does not show the decidual reaction; or it may occur in the tube showing the reaction, but at a point lower down. It is possible, however, that it may occur above the reacting part, and yet be carried down past it to the uterine cavity, if no conditions exist which can prevent this taking place. And, in this connection, we are able to understand the part played by such conditions as inflammation, displacements, tumours, &c., in the tube or outside it, which lead to some interference with the free continuity of the tube lumen. Given the fertilisation of the ovum high in the tube, the obstruction to its free passage to the uterus after this takes place, along with *the occurrence of the necessary decidual*

*reaction in the mucosa* with which the ovum comes in contact, and we have a satisfactory explanation of the pregnancy which develops.

The adoption of these views, which imply that the ovum can only begin its development on a tissue capable of a special genetic reaction, and therefore only in some portion of the passage derived from the original Müllerian ducts, makes it difficult to *believe in the possibility of the occurrence of a primary abdominal pregnancy.*

Though of late, owing to the writings of Bland Sutton, Lawson Tait, and Berry Hart, belief in the existence of such a gestation has been widely discredited, no well-founded reason has been raised to show why it should not take place. Indeed, considering the factor which the two latter authors had believed to be of chief importance in the development of tubal pregnancy, viz., inflammation destroying the mucosal epithelium, it does not appear, according to that view, why a fertilised ovum might not attach itself and grow on a part of the wall of the abdominal cavity which had lost its superficial covering of cells through the same pathological process. According, however, to the view which I have advanced, the primary intra-peritoneal development is improbable, because the peritoneal tissues cannot, as far as is known, undergo the changes required for the establishment of the necessary relationship with the young ovum.

As regards the ovary there is more difficulty. We have no reason to believe that the Graafian follicles can respond to the genetic influence, and there is no proof that a pregnancy has ever started in them.

Supposed cases of ovarian pregnancy require to be studied carefully, and in every instance must be distinguished from the following conditions which may be mistaken for it, viz., preg-



nancy in the outer end of the tube which has become intimately connected with the ovary; pregnancy in an accessory tube end which has become attached to it; pregnancy in the ovarian fimbria, which may be hollow sometimes, representing the extreme outer end of the tube; pregnancy in the tube which has extended into the ovarian sac of peritoneum, which occasionally occurs in women. (Also *vide* p. 45.)

*Primary* development of the ovum in the ovarian sac is as improbable as its development in any part of the peritoneal cavity.

## CHAPTER II.

### CLASSIFICATION.

IN studying the literature of Ectopic Gestation two names, viz., those of Dezeimeris and Lawson Tait stand out in such prominence that they serve to indicate its division into three distinct periods, which may be stated as follows:—

1. The period before Dezeimeris;
2. The period between Dezeimeris and Lawson Tait;
3. The present period.

1. *The period before Dezeimeris.*—Before the 16th century, while references are found in medical literature which prove that the occurrence of ectopic gestation was known, there are no detailed records of cases, nor any attempt whatever at classification.

The first case of which we have any clear account is one—described in the 11th century by Albucasis,<sup>1</sup> an Arabian physician living in Spain, in which he observed parts of a fetus escaping through the abdominal wall by suppuration. During the 16th century several cases were described, but so vaguely that their exact nature cannot be determined; among these may be specially mentioned the cases of Polinus,<sup>2</sup> Horstius,<sup>3</sup> Platerus,<sup>4</sup> and Primerose.<sup>5</sup>

<sup>1</sup> "De Chirurgia," cura J. Channing, Oxon., 1778.

<sup>2</sup> "Miscell. Nat. Curios," 1670. *Obs.* 110.

<sup>3</sup> "Opera Medica," Norimb., 1660.

<sup>4</sup> "De partium corporis humani structura et usu," Basil, 1597.

<sup>5</sup> "De mulierum morbis et symptomatis," lib. iv., Rotterodami, 1655.

During the 17th century, however, more exact descriptions were published, and distinct varieties mentioned.

In 1604 Riolanus<sup>1</sup> examined a case of tubal pregnancy, described by him in his "Anthropographia," the first accurately recorded case of the kind.

In 1614 Mercerus<sup>2</sup> examined the body of a woman who had died of a ruptured two months' ectopic pregnancy—described by him as right ovarian, but which was probably either a tubal or a tubo-ovarian, since he mentions the tube as much enlarged and ruptured.

As to who first described *abdominal gestation* I can find no record. Some of the 16th century writers, to whom I have referred, mention cases in which the foetus was said to have been found in the abdomen, but no special name was used by them to indicate this variety.

In 1682 St. Maurice<sup>3</sup> described a case which has always been regarded as the earliest noted case of ovarian pregnancy, that detailed by Mercerus sixty-eight years previously having been overlooked by most authors.

During the 17th century a clear distinction was recognised between *primary* and *secondary* abdominal gestations: one of the earliest cases of the former variety being mentioned by the Abbe de la Roque<sup>4</sup> in 1663; others are noted by De Monconys<sup>5</sup> and Courtial.<sup>6</sup>

During the 18th century, cases are noted by Martin (*le fils*),<sup>7</sup> Duverney,<sup>8</sup> Turnbull,<sup>9</sup> and others.

<sup>1</sup> "Anthropographia et Osteologia," Parisiis, 1626.

<sup>2</sup> Jo. Riolanus, *op. cit.*, p. 283.

<sup>3</sup> J. J. Mangetus "Theatrum Anatomicum," Geneva, 1717, tome ii., p. 140.

<sup>4</sup> "Ephemerides med. Gallicæ," Paris, 1663.

<sup>5</sup> "Itiner. Italicum," tome ii.

<sup>6</sup> "Nouvelles observations," &c., Leide.

<sup>7</sup> "Hist. de l'Acad. des Sciences," Paris, 1716.

<sup>8</sup> "Œuvres Anatomique," Paris, 1761.

<sup>9</sup> *The New London Med. Journ.* vol. i., 1792.

Secondary abdominal pregnancies are described by many during these three centuries, one of the earliest accounts being that of Berengarius Carpus.<sup>1</sup> It is interesting to note, however, that the most common cause supposed to give rise to this condition was rupture of the gravid uterus, the ovum escaping into the peritoneal cavity. The most complete account of abdominal pregnancies before the present century was that of W. Josephi,<sup>2</sup> whose Dissertation in Latin was published in 1784.

The occasional occurrence of uterine along with extra-uterine pregnancy was long ago noted. The case of Albucasis<sup>3</sup> already noted would appear to have been an example of this, though the description is not clear. Primerose,<sup>4</sup> Thomas Bartholin,<sup>5</sup> Buchner,<sup>6</sup> von Haller,<sup>7</sup> and several others described cases during the 17th and 18th centuries.

In 1779, Noel, a French physician of Lorraine, described a case<sup>8</sup> which he had attended in 1765 as one of *Vaginal Pregnancy*. Though this case, along with one or two others described during the present century, has been noticed by several writers, they have never been regarded as of any value, save as showing how far astray men can be led by imperfect observation.

In the same category must be placed the case observed by Ebersbach<sup>9</sup> in 1714, and named *Bladder Pregnancy*. He made a *post-mortem* examination of a woman who died after severe labour pains, and describes the bladder as being pregnant, the placenta being attached to its inner wall.

<sup>1</sup> "Isagogæ breves in anatomiam humani corporis," Venet., 1535.

<sup>2</sup> "De conceptione abdominali," Gottingæ, 1784.

<sup>3</sup> *Vide*, p. 1.      <sup>4</sup> *Op. cit.*

<sup>5</sup> "Epistolæ med.," 1740, p. 134.

<sup>6</sup> "Miscellan. physico-med.," Erf., 1730, iv., art. 2.

<sup>7</sup> "Disput. ad morb. historiam," Lausannæ, 1757-60, tome iv., p. 793.

<sup>8</sup> *Journ. de méd. de Paris*, 1779, tome i., p. 51.

<sup>9</sup> "Ephemer. Nat. Cur.," cent. v. obs., xx.

The first clear description of *Interstitial Tubal Pregnancy* in which the pregnancy developed in the uterine portion of the tube, was given by Dionis of France,<sup>1</sup> in 1718, though it appears that Mauriceau had previously recognised the condition. In the beginning of the present century similar cases were noted by Schmitt,<sup>2</sup> in 1801, by Albers of Bremen,<sup>3</sup> in 1811, and by others. During the same period another variety was first described, *Utero Interstitial*, in which the ovum was supposed in some way to pass from the tube into the very substance of the uterus, and there develop. There is some doubt as to who is responsible for this description. Albers had in his possession a specimen so named which he had bought, and which he described in an unpublished paper, but which first was noticed by Carus<sup>4</sup> in 1822. Meyer<sup>5</sup> mentions having seen in Lobstein's Museum in Strassburg a specimen of 2½ months' pregnancy in the posterior uterine wall. Similar cases were described by Dance, Hedrich, and others, all of which were considered by Breschet<sup>6</sup> in his memoir of 1824.

The first clearly described case of the extra-peritoneal development of the ovum between the layers of the broad ligament was that of Madame Lefort, published by Bergeret,<sup>7</sup> near the end of last century. Loschge<sup>8</sup> of Erlangen, in 1818, and Lobstein<sup>9</sup> of Strassburg, in 1824, described other cases. It was Dezeimeris,<sup>10</sup> however, who first gave the name *Sub-*

<sup>1</sup> "Traité générale des Accouchements," Paris, 1718.

<sup>2</sup> "Beobachtungen d. k. k. med. chir. Josephs akad. zu Wien," 1801, bd. iv., p. 1.

<sup>3</sup> Dezeimeris, *Journ. d. conn. méd.-chir.*, Paris, 1836, p. 243.

<sup>4</sup> "Zur Lehre von d. Schwangerschaft u. Geburt," &c., Leipzig, 1822, 1st Abt.

<sup>5</sup> "Beschreibung einer Gravid. Interstit. Uteri," Bonn, 1825, p. 5.

<sup>6</sup> *Rheinisch-Westphäl. Jahrb. d. Med. u. Chir.*, Hamm, 1824, bd. viii., p. 54.

<sup>7</sup> Baudelocque, "L'art des Accouchements," Paris, 6th ed., tome ii., p. 460.

<sup>8</sup> *Arch. f. die Erfahrung*, &c., von Horn, Nasse u. Henke, 1818.

<sup>9</sup> *Compt. rend. à la Faculté de Méd. de Strassburg*, &c., 1824, p. 48.

<sup>10</sup> "Grossesses extra-utérines," *Journ. d. conn. méd.-chir.*, Paris, Dec., 1836, p. 257.

*peritoneo-pelvic* to this variety, pointing out its importance, and showing that certain cases previously published, but never understood, had probably been of this nature.

The term *Tubo-ovarian* was first employed by Dezeimeris,<sup>1</sup> who was led to use it from having studied several published descriptions of *post-mortem* examinations of ectopic pregnancies, e.g., Giffard's<sup>2</sup> and Jackson's.<sup>3</sup> As I have already pointed out, the case observed by Mercerus in 1614 was probably a tubo-ovarian. Similarly, he introduced the term *Tubo-abdominal* from the study of imperfect descriptions by several older observers, e.g., Bianchi,<sup>4</sup> Buchner,<sup>5</sup> Rust,<sup>6</sup> and others.

*Utero-tubal* was the name given by him to those cases in which the ovum was supposed to develop partly in the tube and partly in the uterine cavity. The first case recorded is that of Guillemot,<sup>7</sup> in 1832.

*Utero-tubo-abdominal* was the term he used for certain cases which had been described by Patuna,<sup>8</sup> William Hunter and Hey,<sup>9</sup> and Hofmeister.<sup>10</sup> In these the foetus was described as being found in the abdomen, the placenta in the uterus, while the cord passed through the tube.

Before Dezeimeris' time the two chief systematic classifications of ectopic gestations were those of Bianchi<sup>11</sup> (1741) and W. Josephi<sup>12</sup> (1803).

<sup>1</sup> *Op. cit.*, p. 258.      <sup>2</sup> "Cases in Midwifry," &c., London, 1734.

<sup>3</sup> *Dublin Journ. Med. Sc.*, 1833, tome ii.

<sup>4</sup> "De naturali in humano corpore, vitiosa morbosaque Generatione historia," Geneva, 1741, p. 177.

<sup>5</sup> "Annonces littéraires," Gott. 1786.

<sup>6</sup> *Med. chir. Ztg.*, 1824, bd. iii., p. 440.

<sup>7</sup> "Mémoire sur la grossesse extra-utérine," *Arch. gén. de méd.*, Paris, 1832, tome xxviii., p. 298.

<sup>8</sup> "Epist. phys.-med.," &c., Vienna, 1765.

<sup>9</sup> "Med. Obs. Soc. Phys. London," vol. iii. pp. 341-355.

<sup>10</sup> "Mag. f. d. ges. Heilk.," Berlin, 1823, bd. xv., p. 126.

<sup>11</sup> *Op. cit.*, pp. 158-174.

<sup>12</sup> "Ueber die Schwangerschaft ausserhalb d. Gebärmutter," &c., Rostock, 1803.

Bianchi divided them (extra-uterine gestation was called by him *gestatio vitiosa*) into—

- External;
- Internal;
- Intermediate.

By *external* he meant abdominal or ventral. His definition of the other two is not clear—they embrace the tubal and ovarian varieties, the *intermediate* probably being those furthest from the uterus, and the *internal* those nearest it.

Josephi's classification was as follows :—

- Tubal;
- Ovarian;
- Abdominal;
- Primary;
- Secondary or False;
- Vaginal;
- Bladder;
- Extra-uterine combined with uterine.

During this period the possibility of the existence of certain of these forms was denied or considered doubtful by several writers. Thus, Duges<sup>1</sup> was one of the first to dispute the occurrence of a primary *Vaginal Pregnancy*.

Josephi<sup>2</sup> was one of the earliest to deny the possibility of a primary *Bladder Pregnancy*.

Hinze<sup>3</sup> was the first to call into question the occurrence of primary *Abdominal Pregnancy*.

Velpeau,<sup>4</sup> a few years before, first denied the existence of *Ovarian Pregnancy*.

<sup>1</sup> "Diction. de méd. et chir.," Paris, 1833, tome ix., p. 317.

<sup>2</sup> *Op. cit.*, p. 117.

<sup>3</sup> "Versuch eines systemat. Grundrisses d. theoret. u. pract. Geburtshülfe," Stendal, 1791, tome i., p. 38.

<sup>4</sup> "Traité complet de l'art des accouchements," Paris, 1835, tome i., p. 214.

2. *The Period between Dezeimeris and Lawson Tait.*—  
Dezeimeris' <sup>1</sup> (1837) well-known classification was as follows:—

Ovarian ;  
Sub-peritoneo-pelvic ;  
Tubo-ovarian ;  
Tubo-abdominal ;  
Interstitial tubo-uterine ;  
Interstitial uterine ;  
Utero-tubal ;  
Utero-tubo-abdominal ;  
Abdominal.

During this period several attempts were made to simplify the minute description of Dezeimeris, but, though many individual cases of ectopic gestation were recorded, no thorough investigation was undertaken for the purpose of establishing a scientific basis of classification.

Campbell <sup>2</sup> of Edinburgh, in 1840, van Cauwenberghe <sup>3</sup> of Gand, in 1867, and Hennig <sup>4</sup> of Leipzig, in 1876, in their important works were much more simple in their classification than Dezeimeris. Parry, in his well-known work, <sup>5</sup> mentioned almost all the varieties in the Frenchman's list, but arranged them differently.

During this period there was as well a good deal of criticism in regard to some of the varieties recognised by Dezeimeris.

Thus, in regard to the *Ovarian* variety, several able writers in support of Velpeau declared not only that it had never been

<sup>1</sup> *Op. cit.*, p. 254.

<sup>2</sup> "Memoir on Extra-Uterine Gestation," Edin., 1840, p. 17.

<sup>3</sup> "Des Grossesses extra-utérines," Bruxelles, 1867, p. 17.

<sup>4</sup> "Die Krankheiten d. Eileiter und d. Tubenschwangerschaft," &c., Stuttgart, 1876, pp. 109-121.

<sup>5</sup> "Extra-Uterine Pregnancy," &c., Philadelphia, 1876.



proven, but even that its occurrence was improbable or impossible. One of the strongest of these was Mayer,<sup>1</sup> who gives among various reasons the following, viz., that *the formation of a decidua which is indispensable to the young ovum cannot take place in the ovary*. This will be read with interest in relation to the views which I have advanced in regard to the etiology of Ectopic Gestation.

Among the others may be mentioned the name of Allen Thomson,<sup>2</sup>—who held that the ovum was not likely to be developed in the ovary, because after bursting of the Graafian follicle it would either pass into the tube or get into the peritoneal cavity, and also those of St. Hilaire, Pouchet,<sup>3</sup> and of Thomas.<sup>4</sup>

*Primary Abdominal Pregnancy* was also doubted or denied by many writers during this period. Merriman<sup>5</sup> was one of the earliest; he believed that the movements of the intestines offered a mechanical obstacle to the attachment of the ovum. Campbell,<sup>6</sup> Rokitsansky,<sup>7</sup> and Barnes,<sup>8</sup> also held that this form was not probable.

The extra-peritoneal development of the ovum, due to extension of a tubal pregnancy between the layers of the broad ligament, and named by Dezeimeris *Sub-peritoneo-pelvic*, was scarcely noticed by some of the ablest writers during this period.

Campbell,<sup>9</sup> in his work, does not consider this variety,

<sup>1</sup> "Kritik d. Extra-Uterinal-Schwang. vom Standpunkte d. Physiologie u. Entwicklungsgeschichte," Giessen, 1845.

<sup>2</sup> "Cycl. of Anat. and Phys.," vol. ii., p. 456.

<sup>3</sup> "Théorie positive de l'ovulation spontanée," Paris, 1847, p. 421.

<sup>4</sup> *New York Med. Journ.*, 1875.

<sup>5</sup> "A Dissertation on Retroversion of the Womb," Philadelphia, 1817, p. 67.

<sup>6</sup> *Op. cit.*, p. 136.

<sup>7</sup> "Handbuch d. pathol. Anat.," Wien, 1855.

<sup>8</sup> "Diseases of Women," London, 1873.

<sup>9</sup> *Op. cit.*, p. 20.

not having understood how it was possible for an ovum to get between the folds of the broad ligament. Hennig,<sup>1</sup> while recognising its importance, gives but slight attention to it. Parry<sup>2</sup> does not give it in his classification. Though Dezeimeris described this variety, he was not clear as to how it originated. He believed that it was quite distinct from tubal or any other described variety, but how the ovum got between the layers of the broad ligament he did not attempt to state. The following paragraph from his article<sup>3</sup> is of interest :—

“ Ces faits me paraissent suffisants pour légitimer l'admission d'une grossesse sous-péritonéo-pelvienne ; d'une grossesse qui n'est ni ovarique, ni tubaire, et qui, si l'on peut s'exprimer ainsi, est moins abdominale qu'aucune autre, puisque, placée, au premier temps de son existence, en dehors du péritoine, les progrès de son développement ne paraissent point devoir l'y faire pénétrer, mais au contraire le ligament large, en se développant à mesure que le produit de la conception grossit dans la cavité pelvienne, doit former une sorte de plancher qui l'y retient et qui lui ferme l'entrée dans la cavité abdominale.”

I have already referred to the observation of Madame Lefort,<sup>4</sup> who showed that this form resulted from the *extension of a tubal gestation into the broad ligaments (or ovarian as well)*. She described, for the first time, a case in which the peritoneum became gradually stripped from the uterus as the gestation sac extended upwards and towards the opposite side.

Lobstein's case<sup>5</sup> also seems clear as being the extension of a tubal pregnancy into the broad ligament. Jacquemier,<sup>6</sup> Decori and Pelvet,<sup>7</sup> and others, made similar observations.

<sup>1</sup> *Op. cit.*, p. 115.

<sup>2</sup> *Op. cit.*, p. 49.

<sup>3</sup> *Op. cit.*, p. 257.

<sup>4</sup> *Vide*, p. 5.

<sup>5</sup> *Op. cit.*, p. 48.

<sup>6</sup> “*Manuel des Accouchements*,” Paris, 1846, tome i., p. 374

<sup>7</sup> *Gaz. méd. de Paris*, 1864, p. 748.

Rosshirt<sup>1</sup> was the first to describe the development of this variety from the extension upwards of an *interstitial pregnancy*; in this case he noticed the placenta partly attached to the colon, *evidently displaced upwards*, and partly to the wall of the uterine gestation sac.

According to Hennig,<sup>2</sup> Bianchi was the first to describe *the bursting of a tubal gestation into the broad ligament* through thinning and rupture of the lower part of the tube wall.

3. *The Present Period.*—During the last twenty years the previously held views have been subjected to the most searching criticism, while, at the same time, most valuable information has been acquired from various carefully conducted researches in cases of ectopic gestation, and, as a result, we have departed from the other methods of classification.

The writer to whom belongs the honour of having first thoroughly dissected traditional beliefs, pointing out their untrustworthiness or inaccuracy, was Lawson Tait. His able consideration of the subject<sup>3</sup> from the year 1873, when he first brought it forward, until the year 1889, when he published in his well-known text-book<sup>4</sup> a complete account of his work, has been of the greatest value, and has been the means of stimulating other workers who have helped to add to our knowledge of the subject.

Mr. Tait criticised severely the classification of ectopic gestation as given by Dezeimeris and others, and pointed out how utterly unreliable was much of the evidence on which the older writers had based their views. He demonstrated the overwhelming importance of tubal gestation, and the conditions

<sup>1</sup> *Gaz. méd. de Paris*, 1844, p. 298.

<sup>2</sup> *Op. cit.*, p. 115.

<sup>3</sup> *Trans. Obst. Soc. London*, vol. xv., p. 156.

<sup>4</sup> "Diseases of Women and Abdominal Surgery," 1889, vol. i.

which might develop from it, especially the extra-peritoneal development of the ovum after rupture of the tube into the broad ligaments.

He very strongly insisted that the long described Primary abdominal variety had never been established, his own belief being that it is an impossible form. He also held that Ovarian gestation was not proved, though it was possible to have it.

In a recent paper<sup>1</sup> his conclusion in regard to this form is that it is not very likely to occur.

His well-known classification is as follows :—

I. Ovarian, possible but not yet proved.

II. Tubal, in free part of tube, is—

- a. Contained in tube up to fourteenth week, at or before which time primary rupture occurs, and then progress of the gestation is directed into—
- b. Abdominal or intra-peritoneal gestation, uniformly fatal (unless removed by abdominal section), primary by hæmorrhage, secondarily by suppuration of the sac and peritonitis.
- c. Broad ligament or extra-peritoneal gestation.
- d. May develop in broad ligament to full time and be removed at viable period as living child.
- e. May die, and suppurating ovum may be discharged at or near umbilicus or through bladder, vagina, or intestinal tract.
- f. May remain quiescent as lithopædion.
- g. May become abdominal or intra-peritoneal gestation by secondary rupture.

III. Tubo-uterine or interstitial in part of tube embraced by

<sup>1</sup> "Note on the alleged occurrence of Ovarian Pregnancy," *Med.-Chir. Trans.*, London, vol. lxxv.

uterine tissue, and so far as it is known, is uniformly fatal by primary intra-peritoneal rupture before fifth month.

These views were based chiefly on Mr. Tait's extensive clinical and operative experience. They have to a large extent been corroborated by *post-mortem* investigation by other workers. Thus, Berry Hart<sup>1</sup> clearly described the extra-peritoneal development of the ovum in two cases, one of which represented an advanced degree of pregnancy in which the peritoneum had been pushed upwards out of the lower part of the abdomen to a marked extent, and named by him *sub-peritoneo-abdominal*, *i.e.*, a far advanced sub-peritoneo-pelvic.<sup>2</sup> I have also been able clearly to establish a form in which the gestation is partly *extra-* and partly *intra-*peritoneal, to which I have given the name *tubo-peritoneal*—described by Mr. Tait 1889 as unproven. Bland Sutton's writings<sup>3</sup> also have gone to support several of Mr. Tait's views, especially disbelief in an ovarian or a primary abdominal pregnancy.

#### *Author's Classification.*

We may gain information regarding the varieties of ectopic gestation by the study of cases during life, *i.e.*, before and at the time of operation, and by ordinary *post-mortem* examination. The accumulated information acquired by these methods during the last two centuries is, as far as classification is concerned, to a large extent utterly untrustworthy, because the older observers were not aware of the fallacies associated with their employment. The difficulties in the way of accurately estimating the anatomy and pathology of several of the varieties

<sup>1</sup> *Rep. Lab. Roy. Coll. Phys.*, Edin., vol. i.

<sup>2</sup> "Tubo-Peritoneal Ectopic Gestation," Edin., 1892.

<sup>3</sup> "Surgical Diseases of the Ovaries and Fallopian Tubes," London, 1891.

of ectopic gestation have only recently been shown by Berry Hart<sup>1</sup> and myself.<sup>2</sup> We have demonstrated the great value of the sectional method of examination in determining topographical relationships which are essential to the clear recognition of specimens, especially those in which gestation is advanced. In advanced ectopic pregnancy the displacements of organs, along with peritoneal adhesions, render it practically impossible in many cases to determine the nature of the gestation sac, either by examination at the time of an operation or by ordinary dissectional study. It is necessary first of all to study the body with the parts undisturbed by means of frozen sections; in this way we get a correct idea of the arrangement of the peritoneum. Auxiliary to this method are dissection and microscopic examination of parts.

It was by following this plan that we demonstrated the true nature of cases which had always been described as primary intra-peritoneal, viz., Hart's *sub-peritoneo-abdominal* and my *tubo-peritoneal*; in both of these cases the peritoneal relations had become so altered by inflammation that it was believed, until careful examination had been carried out, that they were primary abdominal. The nature of our investigations has made evident the unreliability of all published accounts of primary abdominal pregnancy.

Two special cases have often been quoted as instances of abdominal pregnancy, viz., those of Lecluyse<sup>3</sup> and Koeberlé.<sup>4</sup> When examined carefully, however, it is found that this assumption is entirely unwarranted.

Lecluyse's case was one in which a woman became pregnant for the second time, her first pregnancy having ended in the

<sup>1</sup> *Rep. Lab. Roy. Coll. Phys.*, Edin., vol. i.

<sup>2</sup> "Tubo-Peritoneal Ectopic Gestation," Edin., 1892.

<sup>3</sup> *Bull. Acad. roy. de méd. de Belg.*, Bruxelles, 1869.

<sup>4</sup> Keller, "Des Grossesses extra-utérines," &c., Paris, 1872, p. 23.

performance of Cæsarean section. The second pregnancy was ectopic, and after the death of the fœtus at the eighth month abdominal section was performed for its removal. The woman died, and on *post-mortem* examination the uterine scar of the old Cæsarean operation was partly unclosed, and it was supposed that the ovum had escaped into the peritoneal cavity and there developed. Nothing is said about the nature of the gestation sac or the appendages, and it is most likely that the gestation was tubal or tubo-ligamentous, the opening in the uterus having nothing to do with it. Moreover, all the evidence that we possess in reference to the fate of an early ovum placed in the peritoneal cavity points to the conclusion that death and absorption always follow.

Koeberlé's case was that in which a full time pregnancy occurred in a woman in whom part of the uterus had been removed along with a fibroid tumour by abdominal hysterectomy, the appendages having been left. We are not sure as to how much of the uterus was taken away. Koeberlé says that only part of the cervix was removed. As we know that the uterus is elongated with big fibroids, more of it may have been left than was believed. Enough may have been left to be in communication with a tube, or the tube may have become adherent to the uterine stump after operation, their cavities communicating, so that the gestation may have started in the uterus. It is also possible that the ovum may have been fertilised in the tube, the gestation being thus tubal. It is an unwarranted assumption to suppose that it had passed into the peritoneal cavity. As I have stated in the chapter on Etiology, it is extremely probable that no gestation can begin its development except in some part of the genital tract derived from the Müllerian ducts which forms the uterus and tubes.

Regarding *Ovarian pregnancy* there has been much discussion during this century, and at the present time it must be admitted that there is no proof that a gestation can start in a Graafian follicle. In the chapter on Etiology I give the ground for this statement. Bland Sutton's and Lawson Tait's views on this point have already been alluded to.

In the present state of our knowledge a classification of Ectopic Gestation must necessarily be incomplete. As more exact methods of examination are employed, and doubtful ones abolished, it will be more and more perfected and extended.

The following table indicates the range within which we should limit our attention. Beyond this is uncertainty and speculation. It is evident, then, that the study of ectopic gestation is but the study of pregnancies of tubal origin:—

#### ECTOPIC GESTATION.

*Primary Tubal in all cases as far as is known.*

I. AMPULLAR, in which the gestation begins in the ampulla of the tube. This is by far the most common origin.

1. Persistent. In rare instances the tubal gestation may go on to full time.
2. Rupture may take place early into the broad ligament—subperitoneo-pelvic, tubo-ligamentous, extra-peritoneal, broad ligament gestation.
  - (a). The gestation may continue to develop. Subperitoneo-abdominal.
  - (b). A secondary rupture of the sub-peritoneo-pelvic gestation may take place into the peritoneal cavity.



- (c). The gestation comes to an end :—
- ( $\alpha$ ). By the formation of a hæmatoma.
  - ( $\beta$ ). By suppuration.
  - ( $\gamma$ ). By mummification, adipocere or lithopædion formation.
3. Rupture may take place into the peritoneal cavity.
- (a). Tubo-peritoneal gestation in which escape of the fœtus in the membranes occurs into the peritoneal cavity, the placenta remaining in the tube, its development continuing.
  - (b). The gestation terminates in various ways :—  
By the formation of a hæmatocele, the patient dying from the shock and loss of blood, or from peritonitis. In some cases, absorption of the mass may occur. In others, mummification, adipocere or lithopædion formation, may take place in the fœtus. Or suppuration may result.
4. The gestation may be destroyed :—
- (a). By the formation of a tubal abortion, and its passage through the fimbriated end of the tube into the peritoneal cavity.
  - (b). By the formation of a hæmato-salpinx.
  - (c). By the formation of a mole.
  - (d). By suppuration resulting in a pyo-salpinx.
  - (e). By absorption after early death, by mummification, adipocere or lithopædion formation.

II. INTERSTITIAL. The gestation may develop in the interstitial portion of the tube :—

1. The gestation may go on to full time.

2. Rupture of the gestation into the peritoneal cavity may occur.
3. Rupture into the uterine cavity may occur.
4. Rupture both into the uterine and peritoneal cavities may occur.
5. Rupture may occur between the layers of the broad ligament.
6. After the death of the foetus it may remain in its sac, and (possibly may undergo the same changes as in the other forms), *e.g.*, mummification, adipocere or lithopædion formation.

III. INFUNDIBULAR. The gestation begins in the outer end of the tube, or in an accessory tube ending. Under this heading are to be included the forms described as Tubo-Ovarian and Tubo-Abdominal, names which appear to me to be unnecessary since the gestation is a tubal one in origin, the end of the gestation sac merely becoming adherent to the abdominal wall, the ovary, or other of the viscera.

(CORNUAL PREGNANCY will be considered, though it is not, strictly speaking, ectopic in nature.)

## CHAPTER III.

### VARIETIES STUDIED IN DETAIL.

#### AMPULLAR.

##### 1. PERSISTENT.

THOUGH the development of the tubal gestation to full time, without rupture taking place either into the broad ligaments or peritoneal cavity, is extremely rare, there can be no doubt that it does sometimes occur. Recorded cases are few. Some of these, *e.g.*, Lamm's,<sup>1</sup> Sobelschtsihoff's, and one in Guy's Hospital Museum (No. 2517<sup>50</sup>) are doubtful. One case recorded both by Spiegelberg<sup>2</sup> and Galezowski<sup>3</sup> seems beyond dispute. This case was that of a post-mistress, aged thirty-two, four-para, who was first seen in Spiegelberg's clinic, 14th April 1869, complaining of abdominal pains. She had menstruated last in August 1868. She had not suffered previously save from weakness, sickness, and occasional frequency of micturition during the preceding four months. The pains complained of were labour-like. Shortly after she had a seizure of an eclamptic nature. On examination the uterus was found enlarged (12 c.m.), pushed down in the pelvis, the cervix being in the left fornix. After a series of fits she died on 17th April. On examination after death by Waldeyer, there was found a large

<sup>1</sup> *Monatschr. f. Geburtskunde*, Berlin, 1855, bd. v., p. 145.

<sup>2</sup> *Arch. f. Gynaek.*, Berlin, 1870, p. 406.

<sup>3</sup> "Eine ausgetragene Tubenschwang.," Breslau, 1869.

thin walled sac containing a dead full time fetus. It was adherent in parts to surrounding structures; the enlarged uterus was close to it and under it, on the left side. The upper part had a small tear from which hæmorrhage had taken place into the peritoneal cavity. A considerable amount of blood was also in the sac, the placenta being found partially separated. On close examination the sac was found to be the right tube enormously distended; the right broad ligament was unaffected.

Another very probable case is described by Saxtorph,<sup>1</sup> also one by Martin.<sup>2</sup>

Werth<sup>3</sup> has collected thirteen other cases, in which the pregnancy had lasted for six months or more. Four of these were full time cases, and have been described by Litzman,<sup>4</sup> Henningsen,<sup>5</sup> Litzmann and Werth,<sup>6</sup> and Cooke.<sup>7</sup>

As regards the relationships of the gestation sac in tubal gestation, the following facts are to be noted:—The swelling is more or less pedunculated, and is consequently movable unless prevented by adhesions or incarceration in the pelvis. Mobility is especially noticeable in the early months. The position of the sac varies. It may be found in its own side of the pelvis in the normal position of the tube; it may fall in front or behind the broad ligament; it may be turned inwards and lie in the pouch of Douglas; or forwards and lie in the utero-vesical pouch. As the sac increases in size, it tends to grow mainly upwards out of the pelvis, though it grows also to a varying extent in the pelvis, sometimes to a considerable extent. It may sometimes

<sup>1</sup> *Acta nova regie Soc. med. Havniensis*, 1818, vol. i.

<sup>2</sup> *Berl. klin. Wchnschr.*, 1881, Nrs. 51, 52.

<sup>3</sup> "Beitr. z. Anat. und z. operativen Behandlung d. Extra-uterinschwang.," Stuttgart, 1887, p. 34.

<sup>4</sup> *Arch. f. Gynaek.*, Berlin, bd. xvi., p. 96, and bd. xix., p. 343.

<sup>5</sup> *Arch. f. Gynaek.*, Berlin, bd. i., p. 335.

<sup>6</sup> *Arch. f. Gynaek.*, Berlin, bd. xviii., pp. 1 and 14.

<sup>7</sup> *Trans. Obstet. Soc. London*, vol. v.

develop into the pouch of Douglas, giving rise to a condition very like retroversion of the gravid uterus. In the abdomen the sac is usually on the side from which it arose, but sometimes it may be on the other side fixed by adhesions. The long axis usually lies more or less obliquely, sometimes vertically.

The uterus takes up various positions. In some cases it lies retroverted; sometimes it lies very deeply in the pelvis; sometimes it is pushed towards the side opposite to that in which the pregnancy began; rarely is the fundus directed towards the gestation side; sometimes it may be considerably rotated. When the gestation develops in the pouch of Douglas, the uterus is pushed to the front, and may be considerably elevated.

It is important to note that in the absence of adhesions, the uterus is usually in this form more or less distinct from the gestation sac. When adhesions occur, it may be closely united to the sac, and so its position may be greatly changed; thus, it may be markedly elevated or drawn towards the gestation side.

The ovary in the affected side is usually easily recognisable. It is not markedly displaced as a rule, and corresponds in its alterations pretty much to the uterus. It may often be found distinct from the gestation sac, though it may be close to or in contact with it. Sometimes, as a result of adhesions, it may become intimately connected with the sac.

It is possible that full time tubal pregnancy occurs somewhat more frequently than is believed. When marked adhesions take place between the gestation sac and surrounding structures, especially in the pelvis, it is practically impossible to say by ordinary examination whether the case was purely tubal or tubo-ligamentous. Frozen sections will doubtless help to clear up the nature of difficult specimens.

## 2. CASES WHICH RUPTURE INTO THE BROAD LIGAMENT.

Sub-peritoneo-pelvic.	Tubo-ligamentous.
Extra-peritoneal.	Broad ligament gestation.

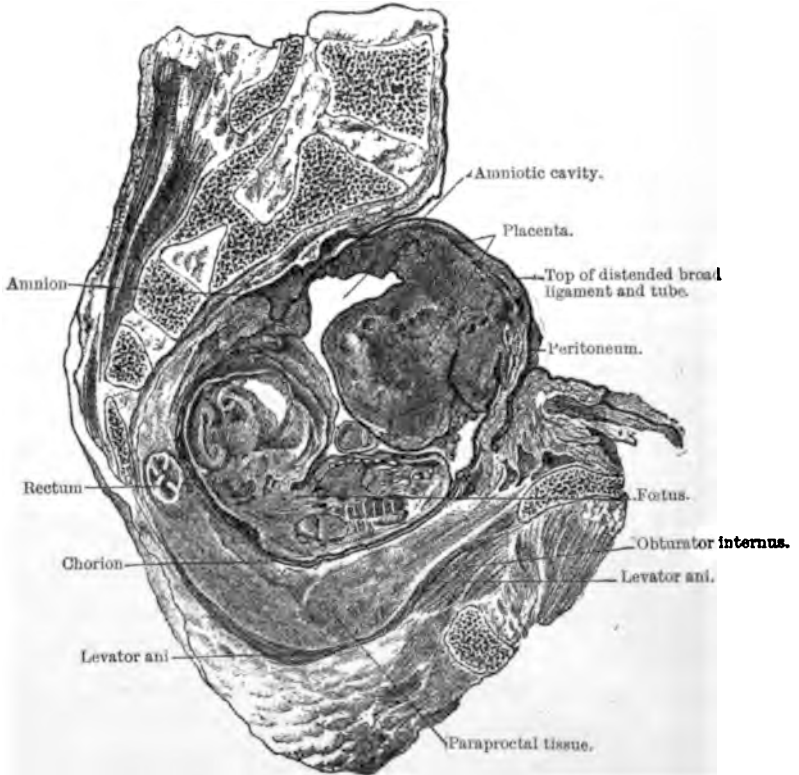
(a.) *Persistent. Sub-peritoneo-abdominal.*

FIG. 1.—Sagittal lateral section (right) of pelvis, with sub-peritoneo-pelvic gestation in right broad ligament. (HART.)

A large number of ampullar pregnancies rupture into the broad ligament and continue to develop. Several names have been applied to this variety—viz., “Extra-peritoneal,” “Tubo-ligamentous,” “Sub-peritoneo-pelvic,” and “Sub-peritoneo-

abdominal." The term "Extra-peritoneal" really includes the purely tubal as well as this form, since in both the gestation goes on outside the peritoneum.

"Tubo-ligamentous," "Broad ligament gestation," and "Sub-peritoneo-pelvic" should be limited to early cases where the gestation sac is within the pelvis. "Sub-peritoneo-abdominal" to the later stages of development when it has extended higher up than the pelvis.

The rupture, which occurs usually from the eighth to the fourteenth week or earlier, may take place suddenly or very gradually. It probably results from a gradual thinning and stretching of the lower part of the tube wall on account of the absence of a peritoneal covering. A large hole may be formed quickly, but probably most commonly only a small one, through which the ovum gradually works its way.

In some cases the process causes no disturbance of any kind to indicate that it is taking place.

The ovum, as it grows, occupies more and more of the ligament, which thus early helps to form, along with the tube, the walls of the gestation sac. The laminae of the ligament become condensed in parts, owing to the compression of their loose connective tissue. They may also become thickened, as a result of the irritation of the growing ovum, and may form adhesions with surrounding structures. The ovum may gradually extend down to the pelvic floor and out to the side wall resting on the bladder, obturator internus, and other structures. Occasionally, however, it may not extend down through the whole ligament, part of which may then remain unaltered below the sac. The gestation tends to increase in all directions, and, as a result, displacements of the uterus, bladder, and rectum may take place, along with stripping of the peritoneum from them and the pelvic wall. Displacement is chiefly noticed in the uterus. It

tends to be pushed more or less over to the side opposite to that in which the pregnancy has taken place. It may also be elevated and pushed against the anterior wall of the pelvis and lower abdominal regions, or it may be pushed behind and below the gestation sac remaining low down in the pelvis. The position of the uterus depends mainly on whether the gestation develops in the first place mainly under the peritoneum be-

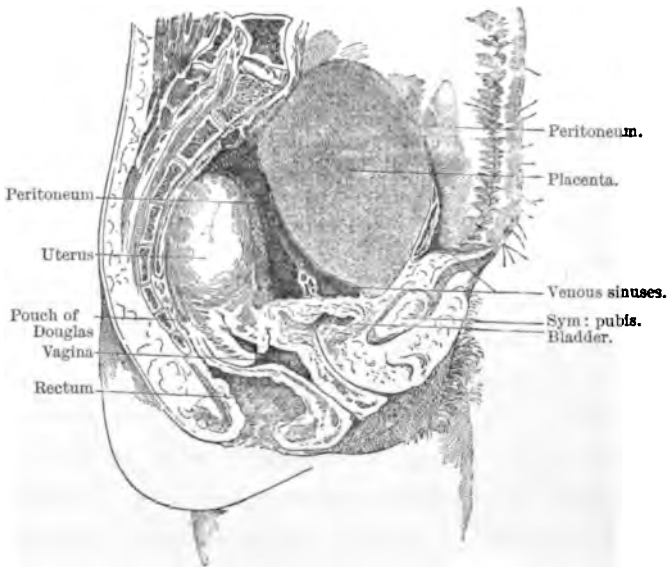


FIG. 2.—Sagittal mesial section of pelvis, with sub-peritoneo-pelvic gestation. The placenta is seen to be extra-peritoneal, and to be partly above the pelvic brim. The fetus, in this case, had ruptured into the peritoneal cavity. (HARR.)

hind or in front of the uterus. These different relationships between gestation sac and uterus may be well seen in Figs. 2 and 3. In the majority of cases the gestation develops posterior to the uterus.

As the gestation extends upwards into the abdomen, it remains always extra-peritoneal, the peritoneum being gradually



stripped from the abdominal parietes and viscera. Berry Hart conclusively showed this by means of the frozen sections he made in the case of a woman who died while still pregnant. Figs. 3, 4, 5, 6, which give the appearances seen in various sagittal sections, show at a glance the altered relationships of parts. The diaphragm, in this case, in which the gestation began in the right side, was higher than in normal pregnancy, owing to the greater relative vertical growth. The stomach was displaced, and also the intestines, which were pushed over to the left. The ureters had evidently been pressed on, the kidneys and ureters being increased in size, the left one being irregularly dilated. The uterus lay mainly above the brim, against the anterior abdominal wall, and mostly to the left of the middle line.

The most marked alterations had taken place in the arrangement of the peritoneum. It was raised upwards out of the pelvis, entirely from the bladder, from the posterior surface and from the upper part of the anterior surface of the uterus. On the right side it was stripped from the anterior abdominal wall for a distance of seven and three-eighth inches above the brim. Behind, its lowest dip lay at the level of the junction of the fourth and fifth sacral vertebræ.

The gestation sac was thus composed of a variety of structures, viz., pelvic floor, bladder, uterus, expanded tube, abdominal wall, connective tissue, surface of the elevated peritoneum, &c. The peritoneal cavity was obliterated in different parts by inflammation, and several adhesions between the bowels and peritoneal surface of the sac had occurred.

Of great importance in regard to the development of the sub-peritoneo-abdominal gestation, as Berry Hart has pointed out, is the position of the placenta. When the placenta lies below

the foetus in the tube and rupture takes place into the ligament, without death of the foetus occurring, it (*i.e.*, the placenta) in its further growth descends and spreads in the extra-peritoneal tissues, becoming attached, it may be, to bladder, uterus, fascial,

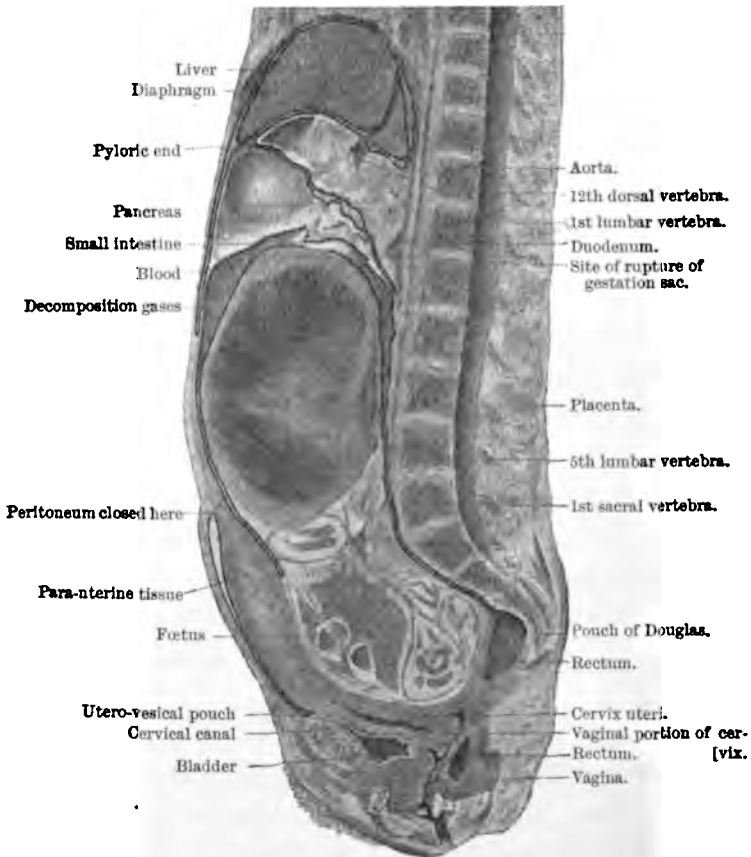


FIG. 8.—Sagittal mesial section of abdomen and pelvis, with advanced sub-peritoneo-abdominal gestation. (HART.)

and other structures in pelvic floor, and on the side wall. At full time one edge may extend to several inches above the brim, where it is somewhat laterally situated.

*SUB-PERITONEO-ABDOMINAL PREGNANCY.* 41

As the gestation sac enlarges in such a case, the placenta does not tend to become displaced.

When the placenta lies uppermost in the tube, a different state of matters results. The upward growth of the gestation

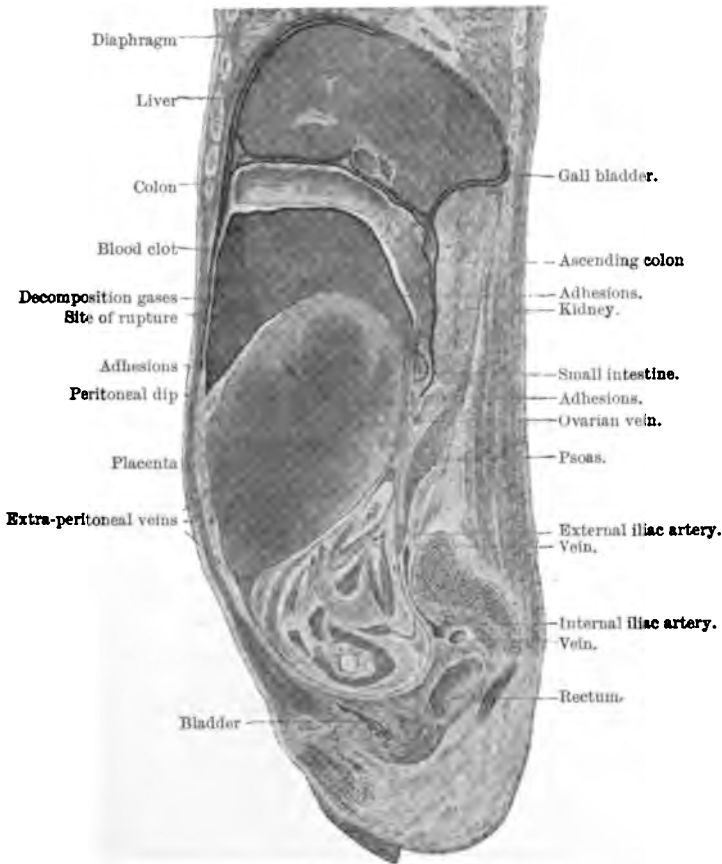


FIG. 4.—Sagittal lateral section of abdomen and pelvis, with advanced sub-peritoneo-abdominal gestation. (HART.)

sac causes the gradual elevation of the placenta, which is attached to its upper wall. In Hart's full time case (Figs. 3, 4, 5) the placenta was displaced upwards for ten inches, being

attached to the anterior abdominal wall outside the stripped off peritoneum, and also to the latter. This displacement is accompanied by gradual destruction of placental tissue owing to blood extravasation, so that the nutrition of the foetus is

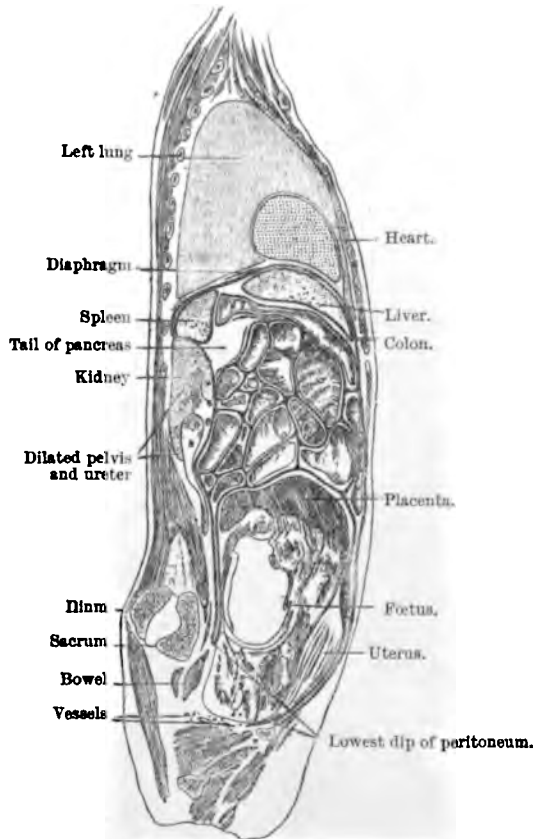


FIG. 5.—Another sagittal lateral section of the same sub-peritoneo-abdominal case. (HART.)

impaired. Such cases, therefore, are not so favourable to the full time development of the gestation as those in which the placenta is lowermost from the beginning.

As regards the extension of the gestation into the broad

ligament, Werth<sup>1</sup> says that it most commonly spreads downwards in the outer part of the ligament, gradually advancing inwards towards the uterus. In two cases of about 4 to 4½ months' duration, the uterus was still separated from the gestation sac

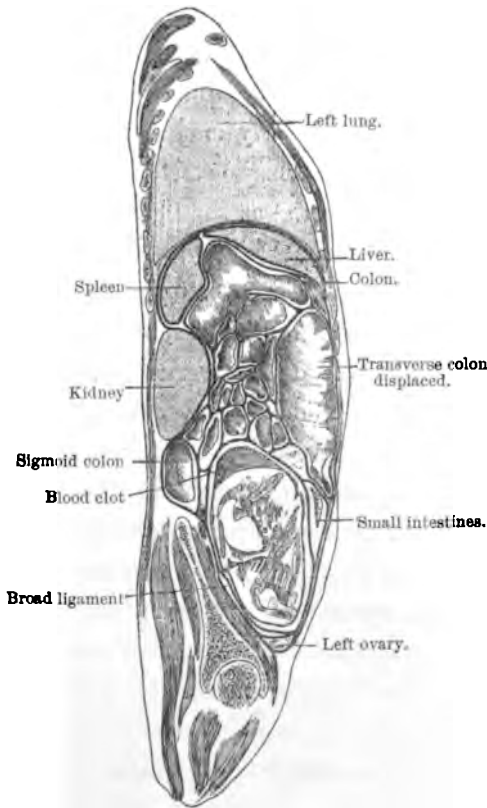


FIG. 6.—Another sagittal lateral section from the same case. (HART.)

by a small piece of broad ligament, though in the outer part of the ligament the sac had reached the floor. The part of the tube internal to the pregnant portion comes to lie on the

<sup>1</sup> *Op. cit.*, p. 27.

gestation sac and to form part of it. It may be gradually opened up, remain as a ridge, or be flattened out so as to be unrecognisable. It may sometimes become stretched and hypertrophied with the development of the gestation. Its lumen may remain pervious or become obliterated. After the early months the fimbriated end can rarely be recognised; it gets flattened out and incorporated with the gestation sac, or hidden by inflammatory deposit. The thinnest part of the gestation sac appears to be, in the early months at least, the posterior upper portion; the wall seems to stretch and bulge most in this part. According to Werth,<sup>1</sup> as the ligament is split up by the ovum, more of the subserous tissue goes with the anterior lamella.

The relations of the uterus are similar to those found in the case of other intra-ligamentous tumours. As the ligament gets more and more distended the uterus is pushed towards the opposite side. By the middle of pregnancy it is usually part of the wall of the sac. It usually also is found well to the front and elevated; the fundus may reach as high as the umbilicus, and it may become plastered over with adhesions.

The large size to which the uterus may attain in this form of pregnancy is due partly to sympathetic increase, but also to its being stretched through its attachment to the gestation sac; the latter explains especially the increased length often found.

The ovary is found in various conditions. Sometimes it is found attached to the sac by the hilum, as in the normal state. Usually it becomes incorporated with the sac wall, and may be considerably increased in size and sometimes greatly flattened out. This increase may be due in some cases to inflammation, but in others to its better nourishment, from the increased vascular supply of the parts, or to being irritated by the stretching of the growing sac. The flattening and blending

<sup>1</sup> *Op. cit.*, p. 28.

of the ovary with the sac wall may be so marked that all trace of it as a distinct body is lost.

In such a condition it is easy to see how the pregnancy might wrongly be described as "ovarian." Occasionally it may be found lying on the top or anterior wall of the sac, owing to the marked bulging of the posterior wall of the broad ligament below the ovary. The intimate relation of the ovary to the sac in broad ligament gestation has no doubt led to the description of several cases as having been in the beginning ovarian pregnancies.

The disposition of the ovary is very similar to what is found in various broad ligament cysts.

*(b.) Rupture of the sub-peritoneo-pelvic form into the peritoneal cavity.*

After the rupture of a tubal gestation into the broad ligament there may be an almost immediate rupture of the sac into the peritoneal cavity. Owing to the extensive laceration of vessels, this occurrence is almost sure to end fatally unless the patient be operated upon.

If rupture does not take place thus early, it may take place at any period during the continued development of the gestation, even shortly before or at full time. This is probably most apt to occur in cases where the placenta is uppermost, because of the following reasons:—First, the hæmorrhage that tends to occur as a result of the upward displacement of the placenta is apt to burst the sac wall. Secondly, the wall to which the placenta is attached is sometimes greatly thinned, and being very vascular may easily rupture from some sudden change in intra-abdominal pressure or from a placental hæmorrhage of only a small size. It is possible, also, that in these cases the non-placental part of the wall may tend to give way more than

where the placenta is lowermost in the pelvis. In the latter form the greater part of the sac is uniformly stretched as growth proceeds. In the former variety the resistance of the wall varies to a greater extent; and possibly that part not situated in the pelvis and supported by the surrounding walls and floor, nor attached to the placenta which may help to steady and support it, may tend to burst more easily. On carefully examining a series of cases, I find no special frequency of rupture through the placental part of the wall.

According to Werth<sup>1</sup> the place of rupture is most frequently the postero-superior portion of the sac wall.

As to the extent and results of rupture I shall speak later on when discussing rupture of pure tubal gestations into the peritoneal cavity. As regards both the ovum and the peritoneum, both tubal and sub-peritoneo-pelvic varieties may be considered together.

(c.) *Disappearance in various ways.*

(a) *By the formation of a hæmatoma.*—The rupture of the tube into the broad ligament may be accompanied with such destruction of placental tissue and pouring out of blood between the layers of the ligament that the gestation ceases to develop farther. This is most apt to occur when the placenta is situated on the lower aspect of the tube. When situated uppermost it may escape tearing altogether, though even in such a case considerable blood may accompany the rupture; when placed laterally, the edge only may be torn through. The placenta in some cases, therefore, may only be partially destroyed, but in others it may be completely torn up by the blood. In these cases the amniotic cavity may be ruptured, or it may be greatly compressed along with the fœtus, by the pressure of the blood

<sup>1</sup> *Op. cit.*, p. 28.



outside it. If much of the placenta be destroyed, whether there be much blood effusion or not, the foetus must nearly always die. If only a small part be destroyed, it will very probably die if the blood mass be of any size. If the placenta be only slightly affected, death may also be caused by some injury to the cord or foetus. We thus see how the ovum may get embedded in a mass of blood, known as a hæmatoma or extra-peritoneal hæmatocele. This varies greatly in size in different cases, *e.g.*, from a small orange to the size of a new-born child's head, or even larger. Usually the mass is localised on one side, rarely rising above the brim. If a large amount of blood is poured out it tends to spread in various directions. Thus, sometimes it may burrow in the connective tissue around the pouch of Douglas, enveloping the rectum, giving rise to a swelling known as a peri-rectal or retro-uterine hæmatoma (Fig. 15). Sometimes the blood burrows deeply into the broad ligament by the side of the vagina and bladder; it may pass out in some cases to the side of the pelvis, and tend to follow the psoas-iliacus, or it may even spread through the round ligament. The displacements of the uterus vary according to the size and distribution of the hæmatoma. In a well-marked case it is always pushed to the opposite side, the upper surface of the blood mass being irregularly convex, the lower irregularly concave. The blood, at first fluid, very soon clots and becomes a solid though elastic mass, which gradually gets smaller, as it is absorbed along with the torn up parts of the foetus.

Complete disappearance may take place, nothing being left after a few months save a slight thickening in the broad ligament. As to the age limit for the absorption of a foetus we know nothing. It is certain that three or three and a half months' gestations may entirely disappear after rupture.

( $\beta$ ) *By suppuration.*—In a few cases very shortly after

rupture into the broad ligament, suppuration may occur in the blood mass, and an abscess be formed which runs the usual course of parametric collections of pus. This early suppuration occurs, however, but rarely.

More commonly this termination is found after the gestation has progressed to mid term or beyond. This is to be associated with the closer relation of the gestation sac to the bowel in the late months as a result of the stripping upwards of the peritoneum which takes place. After pus formation, the patient may die before the matter escapes, or, if not, the abscess may discharge itself in various ways, viz., through the bowel, bladder, vagina, abdominal wall, perineum, buttock, or groin.

There is some difference of opinion as to the most frequent manner in which the abscess contents escape. Taking all kinds of ectopic gestation together, we have the following statistics:—

1. In 29 cases published by Lusk<sup>1</sup>:—

16	discharged by the rectum.
6	„ „ abdominal wall.
4	„ „ vagina.
3	not clearly described.

2. In 85 cases published by van Cauwenberghe<sup>2</sup>:—

48	discharged by the intestinal canal.
24	„ „ abdominal wall.
10	„ „ bladder.
3	„ „ vagina.

3. In a series of cases published by Mattei<sup>3</sup>:—

38 per cent.	discharged by the abdominal wall.
30	„ „ „ intestinal canal.
8	„ „ „ bladder.
7	„ „ „ vagina.

<sup>1</sup> *Brit. Med. Journ.*, London, 1886, vol. ii., p. 1086.

<sup>2</sup> *Op. cit.*, p. 260.

<sup>3</sup> *Gaz. d. hôp.*, Paris, 1860, No. 110.

4. In a series of cases published by Parry<sup>1</sup> :—

26·20	per cent.	discharged into the intestinal canal.
16·12	”	” through the abdominal wall.
4·83	”	” ” vagina.
3·62	”	” ” bladder.

5. In 137 cases published by Puech<sup>2</sup> :—

69	discharged through the intestinal canal.
28	” ” abdominal wall.
23	” ” vagina.
17	” ” bladder.

*Intestinal Escape.*—With the exception of Mattei, authorities agree that the escape of a suppurating ectopic gestation takes place in most cases through the large intestine, chiefly through the rectum or sigmoid flexure. The gestation sac and bowel may communicate by one or several openings.

The fœtus has been expelled entire through the bowel in a short time, but in most cases the process is a very long one, and may go on for months or years. In one instance the discharge is reported to have lasted for twenty years. A patient has been known to fall pregnant in the uterus while passing the remains of an old ectopic gestation. Dezeimeris and others have considered the intestinal escape most favourable for the mother, but statistics show that it is the most unfavourable. Thus, in 48 cases collected by van Cauwenberghe, death occurred in 30. In 30 cases mentioned by Mattei, 19 deaths took place. Petit,<sup>3</sup> Moreau,<sup>4</sup> and Chailly-Honore,<sup>5</sup> state that rarely the sac may open into the stomach and the contents be vomited. Darby<sup>6</sup> has

<sup>1</sup> *Op. cit.*, p. 164.

<sup>2</sup> Courty, “*Traité pratique des maladies de l’utérus*,” Paris, 1866, p. 996.

<sup>3</sup> “*Traité des Maladies des Femmes*,” Paris, tome i., p. 90.

<sup>4</sup> “*Traité des Accouchements*,” Paris, 1841, tome ii., p. 366.

<sup>5</sup> “*Traité pratique de l’art des Accouchements*,” Paris, 1867, p. 135.

<sup>6</sup> *Trans. South Car. M. Ass.*, 1872, p. 97.

described an interesting case in which the contents were discharged through the abdominal wall, and in which there was also a communication between the gestation sac and the stomach.

*Abdominal Wall Escape.*—The opening is formed in the great majority of cases at or below the level of the umbilicus, and near the middle line. This method is very favourable for the mother. Out of 53 cases collected by van Cauwenberghe only 8 deaths took place, and in 21 described by Mattei only 1 death occurred.

*Vaginal Escape.*—This occurs so rarely that little can be said regarding it. The maternal mortality is high. Out of 12 cases collected by Parry 5 were fatal, and out of 7 mentioned by Mattei 2 deaths took place.

*Bladder Escape.*—This is a very infrequent occurrence. The maternal mortality is likewise high. Out of 10 cases collected by van Cauwenberghe 3 died. Out of 9 cases collected by Parry 5 died. Puech mentions, however, 17 cases in which only 3 died. The ureter also may be opened into. The bladder may secondarily open into the vagina.

*Uterine Escape.*—Gervis<sup>1</sup> has recorded a case in which the pus burst into the uterus and escaped through the cervix.

*Perineal Escape, &c.*—Escape through the perineum is extremely rare. Yardley<sup>2</sup> describes a case.

As far as is known, the child is always dead before communication is established between the gestation sac and the part into which it opens.

This may take place before the full term of pregnancy or afterwards. If after, the opening is established in most cases within the first six months. In several it may not take place

<sup>1</sup> *Med.-Chir. Trans.*, London, vol. lxx., p. 35.

<sup>2</sup> *Am. Journ. Med. Sc.*, Phila., 1846, p. 348.

until a year or two have elapsed; in a few cases not until three, four, five, or six have passed; and, in a very few cases, many years, *e.g.*, thirty-two, may supervene. Full statistics in regard to this are given by Parry.<sup>1</sup>

In a few cases the gestation sac may open in more than one way. Thus it may communicate with rectum and vagina, with rectum and bladder, with uterus and intestine, with abdominal wall and intestine, and even with bowel, bladder, and abdominal wall.

Several writers have given statistics as to the relative frequency of the different channels of pus-discharge in the various forms of ectopic gestation described according to the old classifications. These are, of course, entirely unreliable, seeing that the classifications are themselves in error.

As regards the sub-peritoneo-pelvic variety, Dezeimeris pointed out the great frequency of the discharge *per rectum* in it. Mattei,<sup>2</sup> in 1860, suggested that the stripping upwards of the peritoneum, and the close relation of the gestation sac to bowel in these cases, facilitated the entrance of poisonous matters from the bowel. Recently Berry Hart<sup>3</sup> has insisted upon the very great importance of this form in relation to suppuration. He thinks that two factors are essential to the termination of an ectopic gestation by suppuration, *viz.* (1) extra-peritoneal development after rupture of the tube into the broad ligament; (2) uppermost position of the placenta and its consequent displacement as the gestation advances. The ovum lying extra-peritoneally comes into close relation with bowel, especially with the rectum, and, in left-sided cases, from an early stage. The displacement of the placenta leads to its

<sup>1</sup> *Op. cit.*, p. 168.

<sup>2</sup> "Des divers modes de terminaison des grossesses extra-uterines anciennes," &c., Paris, 1860.

<sup>3</sup> "Selected Papers," Edin., 1898, p. 161.

gradual and sometimes to its rapid destruction by blood extravasation, so that the nutrition of the fœtus is interfered with; death of the fœtus may therefore be brought about, and suppuration may then be set up by the entrance of noxious matter from the bowel.

I am strongly of the opinion that Hart is right in insisting upon the importance of these factors in the causation of abscess formation. The occurrence of suppuration in any variety other than the extra-peritoneal will most probably be shown to be extremely rare. In the purely tubal form the placenta does not undergo such alterations, nor are the peritoneal relations so disturbed. The fœtus tends therefore to be healthier, and there is greater protection from the bowel.

Hart is of the opinion that the extra-peritoneal form in which the placenta lies above the fœtus is the one that always suppurates. There is no reason why in certain cases in which it lies below suppuration should not occur; I mean those in which, at the time of rupture, a considerable amount of the placenta was destroyed. In such a case the damage may be so great that the fœtus may die and suppuration follow.

In cases in which the placenta has not been much injured at the time of rupture, and in which it lies lowermost, the progress of the gestation is not, so far as we know, accompanied with destructive placental changes of any extent, and the fœtus is therefore not so apt to die as in cases where the placenta lies above, and is displaced.

Hart believes that death of the fœtus occurs first. This may be so, but it is not necessary to suppuration in every case. This process may begin in blood clot. We know, of course, that suppuration may occur in a hæmatoma not associated with gestation, or in the sac wall, probably more especially if the latter be at all inflamed. Death of the fœtus may thus be

sometimes secondary. It is possible that the septic germs may sometimes pass first of all from the maternal tissues into the placenta, thus reaching the foetus and causing its death—

- (γ) By mummification (*vide* p. 92).
- (δ) By conversion to adipocere (*vide* p. 93).
- (ε) By conversion to lithopædion (*vide* p. 94).

### 3. CASES WHICH RUPTURE INTO THE PERITONEAL CAVITY.

- (a.) *Tubo-peritoneal gestation*, in which escape of the foetus in the membranes takes place into the peritoneal cavity, the placenta remaining in the tube, and development continuing.

The first undoubted case of such a form of ectopic gestation was described by me in a monograph<sup>1</sup> published in 1892. Several of the older writers, and also recent ones, *e.g.*, Küstner,<sup>2</sup> Werth,<sup>3</sup> and Berry Hart<sup>4</sup> thought this form possible, while others denied its possibility, believing that rupture of the tube into the peritoneal cavity meant death to the mother, unless she were operated upon.

This case,<sup>5</sup> which occurred in the practice of Halliday Croom, was seen first in February 1890. The patient complained of great swelling in the abdomen and pain in the left iliac region. The history pointed to ectopic gestation, or to pregnancy in the horn of a bi-cornuate uterus. Laparotomy was performed on 15th February. A large, well-formed, recently dead foetus was removed from a sac which extended nearly up to the liver, and which had in the lower part of the abdomen a thick anterior wall. There was an excessive amount of amniotic fluid. The

<sup>1</sup> "Tubo-Peritoneal Ectopic Gestation," Edin., 1892.

<sup>2</sup> *Op. cit.*, p. 514.      <sup>3</sup> *Op. cit.*, p. 57.

<sup>4</sup> *Rep. Lab. Roy. Coll. Phys.*, Edin., vol. i., p. 34.

<sup>5</sup> First communicated by me to the Pathological Club, Edinburgh, May 28, 1890.

uterus was enlarged, elevated, and drawn towards the right side. The placenta was in a separate sac in the left side of

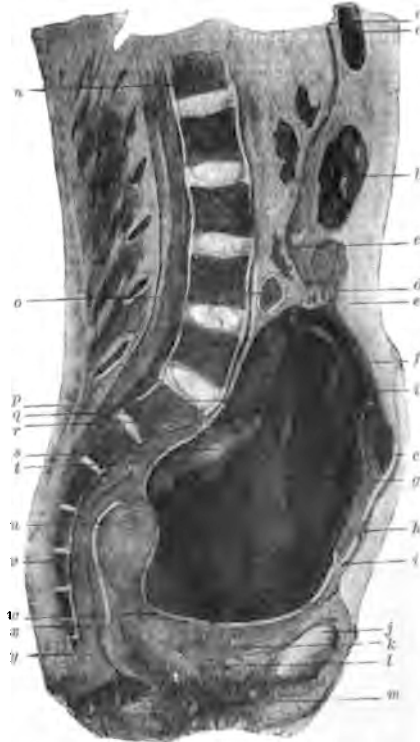

FIG. 7.—Vertical mesial section of body with tubo-peritoneal gestation.

- |   |   |
|---|---|
| a. Pyloric end of stomach.  | l. Urethra.   |
| b. Transverse colon.  | m. Vagina.  |
| c. Secondary or amniotic sac, in which foetus lay.  | n. First lumbar vertebra.   |
| d. Umbilical cord.  | o. Small intestines.  |
| e. Peritoneal cavity behind anterior abdominal wall.  | p. Fold of amniotic cavity.   |
| f. Great omentum altered in character, being dense and fibrous in its inner part, and entering into the formation of the secondary sac. | q. Promontory.  |
| g. Wall of primary or tubal sac containing the placenta.  | r. Adhesions between posterior wall of primary sac and parietal peritoneum. |
| h. Adhesion between anterior abdominal wall and great omentum.  | s. Pale firm mass remains of old blood extravasation into placenta.         |
| i. Blood and torn up placenta forming the mass in primary sac.  | t. Space containing fluid in wall of primary sac.                           |
| j. Symphysis pubis.   | u. Right Fallopian tube in wall of uterus.                                  |
| k. Bladder.   | v. Rectum.  |
|   | w. Adhesions between primary sac wall and utero-vesical pouch.              |
|   | x. Pouch of Douglas.  |
|   | y. Tip of coccyx.   |



the pelvis—a thick viscid mass extending two inches above the brim. It was left *in situ*. The sac which contained the foetus was washed out and drained. The patient died thirty-eight hours after operation, with symptoms pointing to uræmia.

The cadaver was studied by me by means of the sectional, dissectional, and microscopical methods. The gestation was found to be of mixed nature, partly within and partly without the peritoneal cavity.

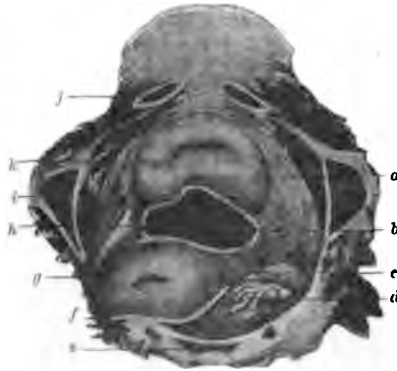

FIG. 8.—Transverse section of pelvis in tubo-peritoneal gestation, through fourth sacral vertebra and subpubic ligament.

- |   |   |
|---|---|
| <p>a. Paravesical connective tissue containing fluid in its spaces.</p> <p>b. Utero-vesical pouch partly closed by adhesions.</p> <p>c. Right broad ligament.</p> <p>d. Rectum.</p> <p>e. Fourth sacral vertebra.</p> <p>f. Pouch of Douglas.</p> <p>g. Left side of uterus bulging into great sacro-sciatic notch.</p> | <p>h. Placenta and blood in primary sac which is lying in the utero-vesical pouch.</p> <p>i. Ischium.</p> <p>j. Descending ramus of pubes.</p> <p>k. Bladder.</p> <p>l. Left broad ligament pushed against pelvic wall by uterus.</p> |
|---|---|

*Nature.*—The gestation sac was double, one containing the foetus, the other the placenta. The former was that part of the peritoneal cavity behind the stomach, transverse colon, and great omentum; the latter consisted of the enormously dilated left Fallopian tube lying in front of the uterus and extending vertically from the utero-vesical pouch to the fourth lumbar vertebra. Though quite distinct from one another, they were connected by means of the umbilical cord and amnion; this

membrane lined the secondary (peritoneal) sac, and passed into the substance of the primary (tubal) sac. The left ovary was found blended with the posterior wall of the primary sac. The broad ligaments were about the same size. The left one was adherent in several places to the primary sac. The uterus was well-formed and enlarged. The right tube and ovary were found somewhat bound together by adhesions.

*Development.*—The ovum in this case began to grow in the

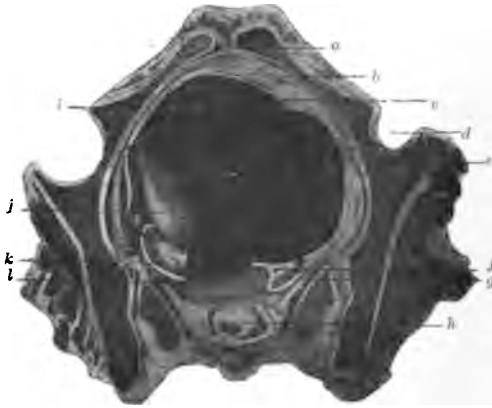


FIG. 9.—A higher transverse section in the same tubo-peritoneal case, made through the junction of the first and second sacral vertebræ and the upper part of symphysis.

- |  |  |
|--|--|
| a. Symphysis pubis.                                    | A. Cartilage between first and second sacral vertebræ.         |
| b. Peritoneal cavity.                                  | i. Wall of primary sac.  |
| c. Adhesions between sac wall and parietal peritoneum. | j. Pale firm mass resulting from old hæmorrhage into placenta. |
| d. Right acetabulum.                                   | k. Left ovary attached to wall of primary sac.                 |
| e. Placenta and blood mass.                            | l. Rectum.   |
| f. Outer end of right Fallopiian tube.                 |  |
| g. Right ovary.  |  |

left tube, which very early fell forwards in front of the broad ligament, where it continued to increase in size.

Then, at sometime during the early months, in a manner unknown, escape of the fœtus in the amnion took place into the peritoneal cavity. This must have occurred very gradually, there being nothing in the clinical history to make either the patient or her physician aware of it. It may have been brought

about in one of two ways. The tube wall in its upper and posterior part may have been greatly thinned, so that the amnion and foetus gradually protruded as a hernia-like mass. Veit<sup>1</sup> and others have noticed such a method of escape of the ovum. Or the escape may have occurred by the fimbriated end of the tube, gradually dilated by the increase in the size of the ovum. This has been observed by Kustner,<sup>2</sup> Orthmann,<sup>3</sup> and others. It is impossible to say whether or not any chorionic

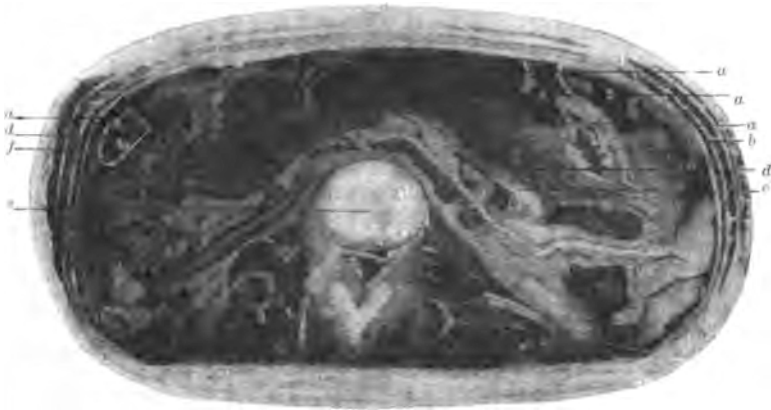

FIG. 10.—Another transverse section through abdomen in same tubo-peritoneal case, made at level of junction of third and fourth lumbar vertebrae.

- |                                      |  |   |
|--------------------------------------|--|---|
| a. Folding of altered great omentum. |  | e. Junction of third and fourth lumbar vertebrae. |
| b. Peritoneal cavity.                |  | f. Amniotic cavity.                               |
| c. Intestines.                       |  |   |
| d. Great omentum.                    |  |   |

tissue escaped along with the amnion. The sub-amniotic layer in the wall of the secondary sac was well-formed fibrous tissue, in some parts very dense; in others, of loose nature and allowing of the folding of the amnion exactly similar to that which occurs in uterine pregnancy. However much of the membranes escaped, they were unbroken and became attached to the peritoneum, its epithelial lining becoming destroyed and its

<sup>1</sup> Schroeder's "Lehrbuch d. Geburtshülfe," 10te Aufl. 1888, p. 423.

<sup>2</sup> *Op. cit.*, p. 503.

<sup>3</sup> *Op. cit.*, chap. v.

subepithelial layer becoming dense and fibrous, forming a secondary sac wall for the foetus. The amniotic fluid continued to be secreted, and to such an extent that in the later months hydramnios resulted. The intestines also became somewhat matted together, especially in each lumbar region, while the great omentum, which entered into the formation of the anterior wall of the secondary sac, became changed into thick fibrous tissue, especially in its inner layers. Strong adhesions developed between the primary sac wall and the left side of the pelvis. That part of the wall not in contact with the pelvic wall and floor became covered with the escaped amnion, thus forming a portion of the secondary sac wall.

*Post-operation changes.*—Hæmorrhage took place inside the primary sac, causing it to be greatly distended. The uterus was pushed backwards and to the left to such an extent that it bulged into the great sacro-sciatic foramen. The uterus and appendages, the rectum, bladder, ligaments, and extra-peritoneal structures were greatly compressed, the vessels being almost completely closed.

The placenta was greatly torn up by the hæmorrhage, which resulted probably from the bursting of some of the thin walled sinuses in the inner part of the tube wall.

A case similar to this has recently been described by Mr. Lawson Tait. As to the frequency of its occurrence, it is impossible to say anything. No doubt, in the past, it has been put down as an abdominal pregnancy (primary).

It is one of the cases difficult to make out except by most careful examination. At the time of operation in the case I have described, the true nature of the gestation could not be made out.

It is believed by some that, at the time of rupture of the primary sac, only the foetus may escape into the peritoneal

cavity, and that, in certain cases, the gestation may progress until full time. Several cases of this nature have been described.

Charpentier<sup>1</sup> mentions the case of Walther, in which, after the rupture of a pregnancy, said to be "ovarian," the foetus developed for four months amidst the abdominal viscera, "and was found at the end of gestation as free and without cyst as at the time of its escape."

Bandl<sup>2</sup> records a case in which, after rupture of the primary sac at the fourth month, the foetus grew till full time in the abdominal cavity, and was extracted alive by laparotomy, the mother being *in articulo mortis*. At the *post-mortem* the child was said to be lying in the abdominal cavity together with a quantity of dirty fluid, no membranes, however, being found.

Jessop's<sup>3</sup> case was one in which the foetus was described as escaping alone into the peritoneal cavity, where it continued to grow until full time, when it was extracted alive. At the operation the peritoneum was more vascular than normal, and appeared "thick and velvety on section."

No trace of cyst or of membranes could be found. A few bands of unorganised lymph of very friable nature were found lying upon, but not adherent to, the intestines. As the mother recovered from the operation, the condition of the appendages, the true nature of the gestation sac, and the relations of the placenta and membranes, were not ascertained.

Champneys<sup>4</sup> also describes a case in which a seven month foetus was removed from the abdomen. It lay among the intestines, "covered only by a dull white membrane." The mother died on the thirty-second day after the operation. At the *post-mortem* it was impossible to make out the relations of

<sup>1</sup> "Traité des Accouchements," Paris, vol. ii., p. 1030.

<sup>2</sup> "Cycl. of Obstet. and Gyn.," vol. xii., p. 690.

<sup>3</sup> *Trans. Obst. Soc. London*, vol. xviii., p. 261.

*Trans. Obst. Soc. London*, vol. xxix., p. 456.

parts in the pelvis, though the placenta was found *above the pubes* lying loose in a sac.

From the descriptions given in these cases we cannot be certain as to their nature, and we are not justified in considering them instances of escape of the foetus alone, and of its after-development in the peritoneal cavity. These cases and others of similar description may be either tubo-peritoneal in which the membranes escaped along with the foetus, surrounding it and afterwards becoming attached to the peritoneum, or sub-peritoneo-abdominal cases in which rupture into the peritoneal cavity had never occurred at all. As I have already pointed out (p. 27) the operation examination or the ordinary *post-mortem* examination is insufficient to determine the true nature. Careful sectional and microscopic study are also necessary, especially to determine the true relations of the peritoneum.

We are, therefore, yet without proof that a foetus can escape into the peritoneum free of membranes and there continue to develop to full time. It is, moreover, exceedingly unlikely that such an occurrence can take place.

The long held belief, viz., that an early complete ovum may escape into the cavity of the abdomen and develop on the peritoneum is a pure supposition, unsupported by any evidence whatever. On the other hand, all our knowledge tends to show the exceedingly great improbability of this view. Leopold's experiments in regard to the absorptive power of the peritoneum on young foetuses placed in the abdominal cavity will shortly be quoted (p. 66). All recent embryological investigations go to show that the relation of the ovum to the mother is so specialised and intimate, that complete disassociation of the two, especially at the period most common in tubal rupture, would result in rapid death of the ovum and its absorption by the peritoneum.

We know that the villous connection between ovum and decidua develops very early, the maternal blood very soon furnishing nutriment and oxygen to the ovum through the medium of the villi. It is inconceivable that a villus covered ovum could attach itself to a peritoneal surface and wait for the development of an intervillous blood circulation. This is still more improbable when the chorion frondosum is more consolidated into a placenta.

No, this old belief is quite untenable. The result of a meeting between a delicate embryonic tissue cut off suddenly from its normal source of nutriment, and therefore presumably in a weakened condition, and the strong resistant peritoneum, which possesses such marked absorptive powers, can only be the destruction of the former by the latter.

*(b.) Gestation terminates.*

By the escape of blood into the peritoneal cavity endangering the mother's life, through rupture of the tube wall.

Rupture of the tubal gestation into the peritoneal cavity, in the great majority of cases, is accompanied with such escape of blood that the mother's life is in peril unless saved by laparotomy.

The rupture is due to the thinning and bursting of the tube wall by the expanding ovum, but sometimes it is directly caused by injury, such as a sudden fall or lift.

The rupture may be large or small, the rent in the tube being rounded, elongated, or irregular. In some cases that part of the wall to which the placenta is attached may burst, or in others the non-placental portion. The whole ovum may escape into the peritoneum or only part of it. According to Orthmann's statistics complete expulsion takes place in a majority of cases. The hole in the tube may become plugged by the foetus partly passed through it. It is thus easy to see

that many variations are to be found in the nature and extent of the rupture, the amount of blood lost and the danger to the mother. There can be no doubt that, in the majority of cases of rupture, death will occur within 24 hours unless an operation be performed. Thus, Parry<sup>1</sup> found that, out of 113 cases, 39 died within ten hours, 81 within twenty-four hours, and 98 within forty-eight hours. The explanation of this is the large loss of blood which usually accompanies rupture.

In other cases only a small loss may take place, and this may be followed at successive intervals by more hæmorrhage.

The temporary cessations may be due to contractions of the tube wall or vessel wall, or to plugging of the rent by the foetal structures. A succession of small losses may prove fatal to the mother after a short time. In some cases blood may accumulate first in the tube, *e.g.*, between the wall and placenta, and afterwards burst into the peritoneal cavity. In another class of cases where the tube is surrounded with adhesions, the blood may only slowly work its way through them. The earlier in the pregnancy the rupture occurs, the less will be the immediate danger to the mother, because the vessels torn are not much enlarged, and will be more apt to be closed by the contraction of the muscular part of the tube wall. Also, an escaped early ovum along with the blood will probably more easily be absorbed in the early than in the late months. The mother will therefore run a somewhat less risk from rupture during the first and second months than during the succeeding months.

In the majority of cases rupture occurs during the first four months of pregnancy, but may also take place during the succeeding months. During the first month it is rare, but has been reported<sup>2</sup> as taking place in the second and third weeks.

<sup>1</sup> *Op.*, *cit.* p. 152.

<sup>2</sup> Parry, *op. cit.*, p. 152.



*HÆMORRHAGE INTO PERITONEAL CAVITY.*

Hennig<sup>1</sup> gives the following table:—

Rupture during the 1st month occurred in 5 cases.

”	”	2nd	”	22	”
”	”	3rd	”	18	”
”	”	4th	”	23	”
”	”	5th	”	8	”
”	”	6th	”	1	”
”	”	7th	”	1	”
”	”	8th	”	6	”
”	”	9th	”	1	”
”	”	10th	”	9	”
	Beyond	”	”	1	”

In Von Schrenck's 141 collected cases<sup>2</sup> of rupture:—

In the 1st month in 13 cases.

”	2nd	”	67	”
”	3rd	”	28	”
”	4th	”	12	”

In Schauta's 87 cases<sup>3</sup>:—

In the 1st month in 15 cases.

”	2nd	”	29	”
”	3rd	”	23	”
”	4th	”	10	”

In Mackenrodt's 38 cases<sup>4</sup>:—

In the 1st month in 6 cases.

”	2nd	”	23	”
”	3rd	”	5	”
”	4th	”	4	”

<sup>1</sup> *Op. cit.*, p. 143.

<sup>2</sup> “Ueber ektopische Gravidität.” *Inaug. Diss. Jurjew*, Dorpat, 1893.

<sup>3</sup> “Beiträge zur Casuistik, Prognose und Therapie d. Extra-uterinschwangerschaft,” Prague, 1891.

<sup>4</sup> “Vier präparate v. Extrauterinsch.,” *Ztschr. f. Geburtsh. u. Gynäk.*, Stuttgart, 1898, bd. xxvii.

A large number of cases ruptured, it thus appears, during the second month.

When death of the mother occurs immediately after rupture or within a few hours, the blood poured forth may not have coagulated, but may be found lying free in the peritoneal cavity with or without part of the whole of the ovum. In other cases a hæmatocele is formed. The effused blood gathers in the pelvis, and may extend high into the abdomen, forming a soft mass at first and afterwards a solid elastic structure. The small intestines usually lie on the upper surface and help to form a covering for it along with membranes formed by the peritonitis which often follows rupture. The relation of the uterus to the hæmatocele mass is interesting. It may lie retroverted or retro-placed below the blood, or may be pushed in front of it against the anterior abdominal wall, or may be upright, completely surrounded by the hæmatocele.

A good deal has been written in recent years as to the relation of ruptured ectopic pregnancy to intra-peritoneal hæmatocele. Lawson Tait<sup>1</sup> is of the opinion that the great majority of cases can be attributed to this cause. Veit<sup>2</sup> gives the following statistics:—

In 66 cases of his own		16 were due to ruptured		
		tubal gestation.		
„ 20	„ Jousset	9	„	„
„ 17	„ Dubousquet	5	„	„
„ 36	„ Voison	9	„	„
„ 7	„ Engelhardt	1	„	„
—————		—————		
„ 146	„ in all	40	„	„
		or 28 per cent.		

<sup>1</sup> *Op. cit.*, p. 472.

<sup>2</sup> "Die Eileiterschwangerschaft," Stuttgart, 1884, p. 14.

There can be no doubt, as Veit indeed thinks, that this figure is far too small. Many cases of early ectopic pregnancy undoubtedly are never recognised because of the great difficulties which many present, and in some instances because of carelessness in examination. Very many cases of hæmatocele are reported without the question of ectopic pregnancy being taken into consideration.

*Sequelæ of hæmatocele.*—These need not be fully discussed here, as they are scarcely within the scope of this work. When once the hæmatocele is formed, it may progress as follows:—

1. The patient may die from the result of the shock and exhaustion, even after some days.

2. Peritonitis may occur of such a severe nature or so protracted as to kill the patient. The relation of hæmatocele to peritonitis has been a subject considerably discussed. Bernutz and Goupil<sup>1</sup> were of the opinion that the peritoneal changes resulting from escape of blood into the abdominal cavity were not so great as had been supposed.

Rogers<sup>2</sup> said that peritonitis never occurred. Parry's<sup>3</sup> opinion "is that it is so rare . . . that the possibility of its supervention need scarcely be taken into consideration." Some other writers have held that it is a very common occurrence.

There can be no doubt that the majority of cases of hæmatocele run a course with neither the signs nor symptoms of peritonitis, and it may be at once conceded that acute peritonitis very rarely supervenes in a hæmatocele. As to the occurrence of *chronic peritonitis*, careful observations require to be made, and *post-mortem* evidence is alone to be depended upon for information, because we know that often in the abdominal

<sup>1</sup> "Diseases of Women," *New Syd. Soc. Trans.*, vol. i., p. 269.

<sup>2</sup> "Extra-Uterine Fœtation and Gestation," *Phila.*, 1867, p. 39. <sup>3</sup> *Op. cit.*, p. 138.

cavity extensive adhesions may be slowly formed, *e.g.*, over an ovarian tumour, without the accompaniment of sufficient clinical signs to make evident the progress of the pathological process. As far as we know at present from *post-mortem* evidence, the upper surface of a hæmatocele gets roofed over by the bowels and omentum matted together by slowly formed peritonitic adhesions.

3. The blood may become entirely absorbed, so that the patient recovers. The progress of every case depends upon the fate of the ovum. If the pregnancy be early, the ovum may probably be easily absorbed if it escape along with the blood into the peritoneal cavity. After the early months, when the placenta is a well-marked structure, partial or total escape of it along with the fœtus probably always is fatal to the mother. When the fœtus alone escapes, we cannot definitely speak as to its fate in all cases. If young, it may be removed gradually by the peritoneum, whose absorptive power is so great. Older fœtuses may be partly absorbed, or may, with or without absorption, become encapsuled by peritonitis, and, as a result, the patient may die; or the fœtus may become shrivelled, turned into adipocere, into a lithopædion, or it may become softened and form an abscess.

Interesting in this connection are Leopold's<sup>1</sup> experiments, in which he placed canine fœtuses in the peritoneal cavity of other animals. Breaking up and absorption of the fœtuses occurred with great rapidity. In one dog in which was placed a fœtus  $2\frac{1}{2}$  c.m. in length, as well as another which had gone beyond the mid term of pregnancy, no trace was found after two days. In another case in which two fœtuses  $2\frac{1}{2}$  c.m. in length were placed, three days afterwards, when the abdomen was

<sup>1</sup> "Experimentelle Untersuchungen ueber d. Schicksal implantirter Fœten," *Arch. f. Gynaek.*, Berlin, bd. xviii., hft. i.

opened, two yellowish white round masses were found, which looked like embryonic tissue, and which were bound to the intestine and anterior abdominal wall with peritonitic adhesions; they were very soft to the touch, and easily broke up. Small cartilaginous bits were still found in them.

In another case two fœtuses were implanted, and the abdomen opened on the fifteenth day. Nothing was found save two small bodies, each the size of half a lentil, and fastened to the intestines by adhesions.

Similar results were got with older fœtuses.

When septic peritonitis followed the implantation, it was found that the breaking up of the fœtus took place more quickly than when no septic complication occurred.

In the septic cases complete breaking up and absorption took place, save in the most resisting tissues—*e.g.*, bone.

It is interesting to quote, in conclusion, the results<sup>1</sup> of William Hunter's recent experiments on the fate of blood poured into the peritoneal cavity of animals.

“The results of the foregoing experiments may be regarded as definitely proving that, in the case of the peritoneal cavity at least, the fate of extravasated blood is not so entirely a merely local one as has hitherto been generally supposed. On the contrary, a very considerable, sometimes even a large, proportion of the red corpuscles may escape a local fate altogether, becoming absorbed mainly through the lymphatics of the diaphragm into the circulation, where they continue, for a certain time at least, to perform their functions as before.

“The rapidity with which this absorption takes place is always both relatively and absolutely greatest during the earlier hours after the effusion, especially in the case of entire blood,

<sup>1</sup> “Intraperitoneal Blood Transfusion,” &c., *Journ. Anat. and Physiol.*, London, 1887.

the absorption extending, however, over a period of twenty-four hours or even longer, according to the amount of the effusion.

“The maximum increase is attained on the third or fourth day after the injection, the time depending partly on the quantity of blood transfused, partly on its fluidity. . . .

“The actual absorption of corpuscles which takes place during the earlier hours after the transfusion can, however, never be accurately determined, even by enumeration of the corpuscles in the circulating blood, still less by estimation of the hæmoglobin. For, owing to the serious effusion which almost always occurs into the abdomen as the immediate result of the injection, the number of corpuscles in the circulating blood, as determined by enumeration, is always apparently much increased; and it is not until this infused serum, along with the injected serum, has become re-absorbed, and the injected serum has become removed from the circulating blood, that the actual amount of absorption of corpuscles which has taken place becomes apparent.

“A *slight inflammatory* reaction always occurs for a few hours after the injection, resulting in an effusion of serum containing leucocytes, more or less marked according to the amount of irritation. This effusion is, however, of short duration, ceasing generally in the course of the first few hours, after which the effused serum, along with that of the injected blood, becomes re-absorbed into the circulation. The irritation produced by the presence of clots is probably of more consequence, as it certainly is longer lasting. The resulting inflammation, however, is generally localised. In no instance, at least in these experiments, was it such as in any way to endanger life. . . .

“It is in the neighbourhood of the female generative organs, and in connection with pathological conditions of these organs, that such extravasations most frequently occur. A few considerations only need be presented here.

“If the extravasation take place extra-peritoneally, *e.g.*, between the layers of the broad ligament, . . . it is clear that most of the conditions will be present, especially as regards the more or less definite boundaries of the extravasated blood, to ensure the early coagulation of the blood, and that, too, *en masse*. As any absorption of corpuscles which may then occur can only take place through the ordinary lymphatic channels of the pelvis, through which the absorption of the corpuscles as such is but slight, by far the greater portion of the corpuscles will thus be doomed to a local fate.

“If, on the other hand, the effusion of blood occur not only extra-peritoneally, but also in part into the peritoneal cavity itself, as is probably not unfrequently the case, the ultimate fate of the blood may be different. Its coagulation may then be more or less delayed, and its absorption greatly facilitated by the special action of the diaphragm in promoting absorption.

“The distribution of the blood in such cases will naturally be, in the first instance at least, in the neighbourhood of the pelvic organs, although the peristaltic action of the intestines will tend to distribute it more or less amidst the coils of intestine. However clear may be the part played by the diaphragm in absorption in the case of animals in whom the quantity of blood injected, relative to the size of the abdomen, is so great, the case is otherwise in the human subject, where the quantity of blood relative to the size of the abdomen may be very small, and the blood itself is generally situated at that part of the abdomen most distant from the diaphragm.

“It became of interest, therefore, to determine what part the diaphragm played in the absorption of small quantities of fluid.

“In two experiments on rabbits, in which death took place within a period of 24 to 26 hours after the injection, the inflammation was observed to be most intense over the under surface

of the diaphragm and upper surface of the liver, these surfaces being covered with a thickish layer of fibrinous lymph, with at parts larger nodules of fibrine and leucocytes. It seemed as if the septic poison introduced had acted most virulently at the seat of its absorption.

“It has already been seen that it was in this neighbourhood that fluid blood was always found most abundant, if examination were made shortly after its injection.”

4. *Suppuration may follow.*—Suppuration may take place in the early or late stages of a hæmatocele, or may, after the blood mass has been entirely absorbed, start in connection with the remains of the fœtus. The pus tends to work its way to the outside, bursting through bowel, vagina, or bladder.

#### 4. GESTATION MAY BE DESTROYED.

(a.) *By the formation of the so-called “tubal abortion.”*

By this is meant the separation, partial or complete, of the ovum from the tube wall, accompanied with hæmorrhage into the tube lumen and the escape of the blood, along with part or whole of the ovum into the peritoneal cavity through the fimbriated extremity of the tube.

The condition was first fully described by Werth,<sup>1</sup> though cases had been noticed by other observers, e.g., Westermarck<sup>2</sup> and Veit.<sup>3</sup> Recently Keller,<sup>4</sup> Bland Sutton,<sup>5</sup> and Orthmann<sup>6</sup> have written at some length regarding it. The abortion is most apt to occur during the first months before the *ostium abdominale* has become closed, though it is likely that it may also take place if the ostium be only closed with weak adhesions.

In thirty-two cases<sup>7</sup> collected by Mackenrodt—

<sup>1</sup> *Op. cit.*, p. 105.

<sup>2</sup> “Hygiea,” Stockholm, 1885, Nr. 6.

<sup>3</sup> *Ztschr. f. Geburtsh. u. Gynäk.*, Stuttgart, bd. xii., hft. ii.

<sup>4</sup> *Ztschr. f. Geburtsh. u. Gynäk.*, Stuttgart, 1890, pp. 21, 22.

<sup>5</sup> *Op. cit.*

<sup>6</sup> *Op. cit.*

<sup>7</sup> *Ztschr. f. Geburtsh. u. Gynäk.*, Stuttgart, 1893.



It occurred during the 1st month in 8 cases.

”	”	2nd	”	”	19	”
”	”	3rd	”	”	4	”
”	”	4th	”	”	1	”

In twenty-nine cases occurring in Martin's Hospital—

It occurred during the 1st month in 13 cases.

”	”	2nd	”	”	10	”
”	”	3rd	”	”	4	”
”	”	4th	”	”	2	”

The expulsion probably takes place as a result of the contractions of the muscular part of the tube wall, the tubal contents

abortion mass.

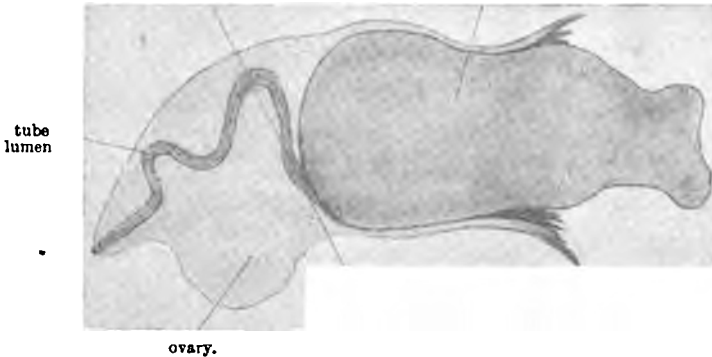


FIG. 11.—Left tubal pregnancy, 1-2 months, longitudinal section. The tubal abortion is gradually passing through outer end of tube (ORTHMANN.)

moving in the direction of *least resistance*. It can most easily take place when the ovum is primarily situated in the outer part of the tube, but, it must be remembered, the ovum may be moved some distance along the tube.<sup>2</sup>

<sup>1</sup> Orthmann: "Beitrag zur frühzeitigen Unterbrechung der Tubenschwangerschaft," *Ztschr. f. Geburtsh. u. Gynäk.*, Stuttgart, 1894, bd. xxix.

<sup>2</sup> According to Lawson Tait (*Brit. Gynec. Journ.*, London, May 1892, p. 99) this so-called "tubal abortion" is extremely rare, and he objects to the use of the term, because its clinical and pathological features are the same as in the case of rupture of the tube. Moreover, he believes that the introduction of this term may lead practitioners to consider it as, on the whole, of no more seriousness than an ordinary "uterine abortion."

In most cases, according to Orthmann, the ovum is completely expelled.

*The results to the mother are practically the same as when rupture of the tube wall occurs, and all that has been said under this heading will apply here.* A hæmatocele is formed in the peritoneum; death may be immediate or delayed; peritonitis, suppuration, &c., may follow; or, sometimes, recovery may ensue. In some cases where the patient does not at once die, a hæmato-salpinx may be formed along with the hæmatocele; and according to Werth, the outer end of the tube may become closed after the escape of blood, so that the hæmatocele and hæmato-salpinx become distinct from one another.

Orthmann, however, states that in quite a number of abortions (ten out of twenty-nine operated upon in Martin's Hospital) the ovum may be found in the peritoneal cavity without any blood, the latter having been absorbed quickly by the peritoneum. In such cases, however, more or less blood clot is found in the tube. He points out that this condition never occurs in cases of tubal rupture where blood is always found in the peritoneal cavity.

This difference is probably explained by the fact that, with a considerable number of tubal abortions, very little blood may escape from the tube, so that rapid absorption of it can take place.

According to Bland Sutton, tubal abortion is the real condition in those cases of hæmatocele that have been wrongly attributed to reflux of menstrual blood from the uterus as well as to hæmorrhage from the tube.

The supposed menstruation is really, according to him, the separation of uterine decidua with blood escape in cases of tubal pregnancy, the internal hæmorrhage being due to the absorption of the ovum into the peritoneum. As there is only a slight

escape from the uterus in such cases, it is easily understood how the belief has been more readily adopted that the blood had regurgitated through the Fallopian tubes.

In cases where the hæmatocele forms without any external bleeding, and therefore, presumably not associated with menstruation, the opinion has usually been that the bleeding occurred in some way from the tubal mucosa. All such supposed cases must be examined with the greatest care, clinically, to ascertain the existence of ectopic gestation, and, at the time of operation or *post-mortem*, to make out the real nature of the hæmorrhage; above all, to examine the clot carefully for bits of the fœtus, and the tube for remains of the ovum.

The importance of accuracy is great from the practical point of view, since, now-a-days, it is considered safest to perform a laparotomy and remove the tube, if the bleeding be associated with a tubal gestation.

In many of these cases, besides the free blood which is poured into the tube, there are also found extravasations in the substance of the fœtal membranes of small or large amount. There can be no doubt that the latter hæmorrhages may, by destroying the ovum and forming the so-called "mole," lead to the abortion and the consequent tearing of maternal vessels, which is accompanied with the loss of a large quantity of blood. I have pointed out in my description of the membranes (p. 132) the almost constant tendency to hæmorrhage, especially in the *decidua reflexa*.

(b.) *By the formation of a hæmato-salpinx.*

The ovum may be entirely broken up and diffused through the blood, or it may be partly or entirely detached and become incorporated as a mole with the blood mass. In these cases

there is often a tendency for the mass to increase, owing to fresh hæmorrhages succeeding the primary loss.

(c.) *By the formation of a mole.*

In a number of cases the ovum may die, as a result of hæmorrhage in its membranes, but without very marked out-pouring of the blood around it. There is thus formed what is known in uterine pregnancy as "blighted ovum," "fleshy or carneous mole," or "apoplectic ovum." The amount of blood extravasation varies. It may be limited to the decidua and chorion, and may be so great as to compress and so almost close the amniotic cavity, or it may burst into the amniotic cavity. The fœtus may be partly or entirely destroyed. Immediately after these changes the ovum looks like a fresh blood clot, and, unless the specimen be studied with care, the gestation elements, *e.g.*, amnion, chorionic villi, and decidua may not be recognised. Later on the mass is paler and firmer, undergoing the ordinary organisation changes of blood clot. They gradually tend to shrink in size, but may remain as small hard masses for long periods. The importance of the fresh mole in relation to abortion into the peritoneum has already been considered.

(d.) *By the formation of a pyo-salpinx,*

owing to decomposition of the ovum and blood clot. The septic process may be very rapid, and the pus may burst into the peritoneal cavity, uterus, bladder, bowel, or vagina.

(e.) *In cases where the ovum may have advanced*

beyond the second month, absorption of the fœtus may take place, but the bones may remain for years unabsorbed.

Mummification, transformation to adipocere or lithopædion, also sometimes takes place.

## CHAPTER IV.

### VARIETIES STUDIED IN DETAIL—*Continued.*

#### INTERSTITIAL TUBAL PREGNANCY.

AN ovum may develop in that part of the Fallopian tube which is situated in the uterine wall. This form of gestation is extremely rare. Most of the statistics regarding its frequency are not to be trusted, because some of the cases on which they are based have not been interstitial, but probably either cornual pregnancies or ampullar gestations which have ruptured into the broad ligament.

Parry<sup>1</sup> describes thirty-one of his collected 500 cases as of this variety. Hennig<sup>2</sup> makes the remarkable statement that out of 150 cases forty-two were interstitial.

Baart de la Faille,<sup>3</sup> in 1867, could gather only sixteen cases. Sassmann,<sup>4</sup> in 1880, was able to collect only four additional undoubted cases in literature published after 1867.

The development of this form of gestation is so characteristic that it should not, in the great majority of cases, be mistaken on *post-mortem* examination. The gestation sac, being embedded in one wall of the uterus, is not distinct from this organ, but is an intimate part of it.

Viewed from the outside the whole uterus appears to be enlarged, but in an irregular manner. The gestation grows

<sup>1</sup> *Op. cit.*, p. 51.

<sup>2</sup> *Op. cit.*, p. 109.

<sup>3</sup> *Schmidt's Jahrb.*, Leipzig, bd. 138, p. 190.

<sup>4</sup> "Ein Fall von interstitieller Schwangerschaft," 1880, p. 3.

internal to the round ligament on the side to which it belongs (as does also a cornual pregnancy). The great majority of ectopic gestations develop outside the round ligament. As the sac enlarges the uterine cavity is more and more pushed towards the opposite side, and, in a specimen advanced to mid term, appears as a canal, running obliquely on the outer wall of the gestation sac.

Occasionally, however, the sac may enlarge chiefly outwards, growing between the layers of the broad ligament, as in cases described by Martin<sup>1</sup> and Leopold.<sup>2</sup> In some cases the original opening may enlarge so that the ovum may entirely escape into the uterine cavity.

I have recently had sent me by Dr. Lawson Russell of Todmorden the notes of a case observed by him, in which a patient expelled a complete uterine decidual cast to which was attached at one of the upper angles an early ovum which had evidently been situated in the interstitial part of one of the tubes.

In some cases the ovum may partly extend into the uterus, and thus develop partly in the tube and partly in the uterine cavity.

In other cases the communication may be closed by the decidua, or remain patent and be merely closed off by the fetal membranes. In the latter form Küstner<sup>3</sup> points out that, on clinical examination, the following mistakes have been made in diagnosis:—On the one hand, they have been thought to be cases of normal pregnancy, with marked hypertrophy of the cervix, the true uterine cavity being mistaken for the cervical canal; and on the other, they have been considered as incomplete abortions, the muscular diaphragm next the uterine cavity

<sup>1</sup> *Ztschr. f. Geburtsh. u. Gynäk.*, Stuttgart, bd. xi., p. 416.

<sup>2</sup> *Centralbl. f. Gynäk.*, Leipzig, 1886, Nr. 17.      <sup>3</sup> *Op. cit.*, p. 508.

being mistaken for an extremely well-marked retraction ring.

As the ovum grows, the wall of the gestation sac does not thicken, as Bland Sutton<sup>1</sup> says it does (in normal uterine pregnancy it is to be remembered that, while the wall greatly increases in area, it does not increase in thickness, but is, on the average, thinner at full term, especially in the lower segment), but, after the early weeks tends to thin, especially in its upper portion. In one case of five months' duration, I

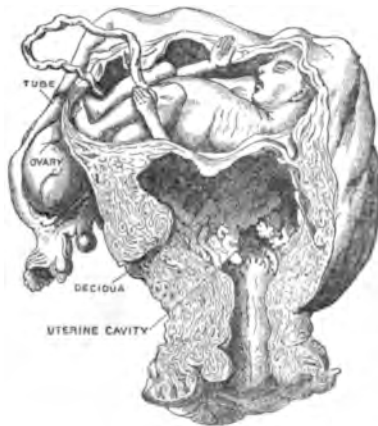

FIG. 12.—Interstitial pregnancy. (In Guy's Hospital Museum.)  
(BLAND SUTTON.)

found the thinnest part of the wall only  $\frac{1}{8}$ -inch in thickness, and containing but a trace of muscle.

Certain cases of interstitial pregnancy seem really to be instances in which the ovum has developed in a tube running in the side wall of the uterus, and connected with the intramural portion of the Fallopian tube.

I have already pointed out (p. 19) how older writers have described an interstitial gestation unconnected with the tube.

<sup>1</sup> *Op. cit.*, p. 352.

Some of their explanations are very fantastic, one of the most curious being that which describes the ovum working its way in and out among the uterine tissues until it finds a permanent resting place.

Baudelocque<sup>1</sup> was one of the earliest to explain that these cases in which the gestation was interstitial, and not in the tube, were really cases in which the pregnancy developed in a branch of the tube which ran down the uterine wall.

Koeberlé and also Hennig<sup>2</sup> have also noted the occasional occurrence of this, and the latter thinks it is embryonic in origin, corresponding to the duct of Gartner, which is found in the cow.

This explanation is probably not the correct one, because Gartner's duct never communicates with the Fallopian tube. The passage in the uterine wall, which is found in connection with the Fallopian tube, is of Müllerian, not of Wolffian duct origin, and it is the remains of an incomplete blending of the two halves of the early uterus. Many variations are found in the size of passage which may be left. It may be a miniature cavity, communicating below with the larger cavity of the opposite side, the cervix being single—a variety of uterus *bilocularis unicollis* of Müller.<sup>3</sup> It may be a small tube, not worthy the name of cavity. It may open into the main cavity at almost any point between the Fallopian tube and *os externum*.

In such cases the external form of the uterus may be normal, though often irregular, both sides not being equally developed.

The possibility of pregnancy developing in the lumen of this tube cannot be denied. It is just as likely as that it should take place in the tube itself.

<sup>1</sup> *Arch. gén. de méd.*, Paris, 1825, p. 410.

<sup>2</sup> *Op. cit.*, p. 111.

<sup>3</sup> "Cycl. of Obstet. and Gyn.," vol. xi. p. 229.



1. RARELY AN INTERSTITIAL PREGNANCY MAY DEVELOP TO  
FULL TIME.

This is not to be wondered at when we know that a tubal pregnancy may follow the same course. Klob<sup>1</sup> has described a case in which the fœtus was removed by abdominal section seven months after full time had been reached. Other cases have been described.<sup>2</sup>

2. RUPTURE OF THE GESTATION SAC INTO THE PERITONEAL  
CAVITY MAY OCCUR.

The rupture occurs generally in the upper and posterior portion of the sac, that in which, as a rule, the greatest thinning occurs; sometimes the tear is in the upper and anterior part.

As to the time of rupture, the following statements are made:—

In Baart de la Faille's cases<sup>3</sup>—

Pregnancy had advanced 6 weeks in 1 case.			
"	"	8	" 1 "
"	"	16	" 1 "
"	"	10	" 6 "
"	"	12	" 6 "
"	"	more than 16 weeks in 3 cases.	

Hennig<sup>4</sup> gives the following table—

Rupture occurred in the 2nd month in 4 cases.

"	"	3rd	" 8 "
"	"	4th	" 4 "
"	"	5th	" 4 "
"	"	6th	" 2 "
"	"	8th	" 1 "
"	"	9th	" 5 "
"	"	10th	" 7 "
"	"	after the 10th	" 2 "

<sup>1</sup> "Cycl. of Obstet. and Gyn.," vol. xii., p. 49.

<sup>2</sup> Küstner, *Op. cit.*, p. 508.

<sup>3</sup> *Op. cit.*

<sup>4</sup> *Op. cit.*, p. 143.

Parry's list is as follows—

Rupture took place in the 6th week in 1 case.

"	"	"	8th	"	1	"
"	"	"	10th	"	2	"
"	"	"	3rd month in 10 cases.			
"	"	"	4th	"	1	"
"	"	"	5th	"	2	"
"	"	"	5½	"	1	"
"	"	"	6th	"	1	"
"	"	"	8th	"	1	"

According to Lawson Tait,<sup>1</sup> rupture occurs always before the fifth month. On comparing these statistics with those relating to tubal rupture, it appears that, while both varieties occur mainly before the fifth month, a very much larger number of tubal ruptures take place in the early weeks. This difference might be expected. The interstitial gestation being surrounded by a thicker and stronger muscular wall tends to remain for a longer period less liable to rupture.

The accident is a very fatal one, on account of the hæmorrhage which accompanies it. In the 26 cases collected by Hecker,<sup>2</sup> death of the mother occurred in every one from this cause. The maternal mortality is therefore greater than in the case of tubal rupture. The explanation is that the rupture does not usually take place in the early weeks, but later, when the vessels of the wall have reached a considerable size, so that there cannot fail to be profuse hæmorrhage. If the placental area be torn through, the loss will be more rapidly fatal. It is also likely that, when rupture takes place, the fœtus or liquor amnii escaping into the peritoneal cavity, the muscular wall of the gestation sac contracts, causing the placenta to be partly or

<sup>1</sup> *Op. cit.*, p. 443.

<sup>2</sup> "Beitrage z. Lehre von d. schwangerschaft ausserhalb der Gebärmutterhöhle," *Monatschr. f. Geburtskunde*, Berlin, 1859, Bd. xiii.

wholly detached. As a result of this, especially if the placenta be situated on the torn wall, there will be great loss of blood. Complete expulsion of the ovum from the sac, followed by thorough contraction of the latter, would tend to diminish the bleeding, though probably not to check it entirely, because in the thin torn wall the muscular elements are so scanty as to be powerless to close the bleeding vessels. It is certain that death may not occur immediately after rupture. Hennig mentions a few cases where the mother lived from ten to forty hours afterwards.

In some instances the whole ovum escapes into the abdomen; in others only the foetus; while in others the placenta may escape and the foetus remain behind.

### 3. RUPTURE OF THE GESTATION SAC INTO THE UTERINE CAVITY.

I have already pointed out that this may occur in the early months partly or wholly. If partly, the ovum may continue to develop; if wholly, it probably always dies, and is expelled from the uterus. As to how old a gestation may rupture in this way nothing is known. As will be found in the next section, it has occurred as late as the eighteenth week. The rupture may take place through the dilated inner end of the tube, or the muscular septum between the gestation sac and uterine cavity may burst. Hennig<sup>1</sup> believes that when the latter form occurs, the placenta is attached to the septum, and that the latter is weakened by the enormous development of vessels in it in relation to the placental supply.

### 4. RUPTURE MAY OCCUR BOTH INTO THE UTERINE AND PERITONEAL CAVITIES.

Rarely this double rupture may occur, and, as has been described by Leopold,<sup>2</sup> besides the internal hæmorrhage which

<sup>1</sup> *Op. cit.*, p. 111.

<sup>2</sup> "Cycl. of Obstet. and Gyn.," vol. xii., p. 51.

occurs, blood may also work its way to the exterior through the uterine cavity.

When this takes place the foetus may escape into the abdomen, and the placenta into the uterus, or the order may be reversed. Bandl<sup>1</sup> mentions a preparation in Rudolf's Hospital, Vienna, in which the former of these conditions exists, pregnancy having advanced for four months. He also refers to a case of Maschka in which rupture occurred at the 18th week, the placenta, head, and part of the neck of the child having escaped into the abdomen, while the child's body was born into the uterine cavity and thence through the vagina.

#### 5. RUPTURE MAY OCCUR BETWEEN THE LAYERS OF THE BROAD LIGAMENT.

This is denied by Bland Sutton and others. I have already mentioned the cases of Martin and Leopold (*vide* p. 76), in which a growing interstitial pregnancy gradually extended into the ligament. Actual rupture must be extremely rare. I can find only one case in which the description clearly points to its having taken place. It is recorded by Rosshirt.<sup>2</sup> The woman went to full time and died after a false labour. The rupture had apparently occurred early. The placenta was found mainly attached to the uterus, but partly also to the adjacent extra-peritoneal broad ligament tissue, into which the rupture had taken place.

A case described by Hey,<sup>3</sup> and known to William Hunter, may have been one of this nature, though from the account it is impossible to be certain. The woman died three months after she had gone to full time. On *post-mortem* examination a large sac was found in the abdomen containing the foetus, and com-

<sup>1</sup> "Cycl. of Obstet. and Gyn.," vol. xii., p. 51.

<sup>2</sup> *Gaz. méd. de Paris*, 1841, p. 289.

<sup>3</sup> "Med. Obs. Soc. Phys. London," vol. viii., p. 341.

municating with a cavity in the uterus which contained the placenta.

In the same category may be placed the case of Hofmeister.<sup>1</sup>

#### 6. THE FŒTUS MAY REACH FULL TIME, DIE, AND REMAIN IN ITS SAC.

Klob<sup>2</sup> and Rokitsky<sup>3</sup> have each described a case in which the dead fœtus was removed from an interstitial gestation sac seven months after full time had been reached. Rathgeb<sup>4</sup> says that a lithopædion may be formed, but there is no definite information in regard to this point.

#### INFUNDIBULAR PREGNANCY.

A gestation may start in the outer end of the Fallopian tube, though this is not of frequent occurrence. Cases of this have been described by many authors under the name of "Tubo-Ovarian" and "Tubo-Abdominal," *e.g.*, by Bussiere,<sup>5</sup> Dezeimeris,<sup>6</sup> Beaucamp,<sup>7</sup> Bandl,<sup>8</sup> &c.

We are not in possession of sufficiently well authenticated facts to give a special description of this variety. But any extended reference to it would appear to be unnecessary, because all that has been said in reference to ampullar gestation might apply to the infundibular. One or two special points must be noted, however:—

The outer end of the tube is the most movable, and, therefore, unless fixed by adhesions, is liable to be found in various positions. Adhesions are very apt to form between it and surrounding parts, *e.g.*, ovary, abdominal

<sup>1</sup> *Mag. f. d. ges. Heilk.*, Berlin, vol. xv., p. 126.

<sup>2</sup> "Cycl. of Obstet. and Gyn.," vol. xii., p. 49.

<sup>3</sup> "Handbuch d. pathol. Anat.," Wien, 1855, vol. iii., p. 542.

<sup>4</sup> "Ein Fall. v. Graviditas interstitialis," München, 1884, p. 21.

<sup>5</sup> *Phil. Trans.*, London, vol. iii., p. 605.

<sup>6</sup> *Op. cit.*, p. 258.

<sup>7</sup> "Ueber Tubo-ovariälschwang.," Stuttgart, 1884.      <sup>8</sup> *Op. cit.*, p. 51.

wall, colon, omentum, rectum, bladder, &c. Rupture may more easily occur through the fimbriated end. This may take place into the peritoneal cavity, into a sac formed by peritonic adhesions around the end of the tube, or into a tubo-ovarian cyst caused by the persistence of an ovarian sac of peritoneum, sometimes found in woman.

This ovarian sac has been especially noticed by Arthur Robinson<sup>1</sup> and Bland Sutton.<sup>2</sup> In mammals, the sac is found in various stages of completeness. Thus, in the hyæna, rat, and mouse, it quite surrounds the ovary, the end of the tube opening into it; in the baboon and porcupine it is partly formed. In the human subject it is usually only found as a recess in the mesosalpinx; this varies in depth in different women. In some it is deep enough to hold the whole ovary. Bland Sutton points out that in the virgin the ampulla of the tube falls over the opening of the recess and hides the ovary, this relationship being disturbed after the first pregnancy.

That cases may proceed to full time is proved by the experience of Bandl and others.

In some cases the outer end of the tube may be from the first in close relation to the ovary, either from a developmental peculiarity or from peritonitis.<sup>3</sup>

It is also probable that pregnancy may sometimes occur in an accessory tube end or in a hollow ovarian fimbria, which is thought by many to be the real end of the Fallopian tube.

In most of the forms of infundibular gestation it is easy to understand how intimate may be the relation of the ovary

<sup>1</sup> "On the Peritoneal Relations of the Mammalian Ovary," *Journ. Anat. and Physiol.*, London, vol. xxi., p. 169.

<sup>2</sup> *Op. cit.*, p. 114.

<sup>3</sup> Hasse, *Arch. f. Gynaek.*, Berlin, bd. viii. p. 402. Burnier, *Ztschr. f. Geburtsh. u. Gynäk.*, Stuttgart, bd. v. p. 357. Spencer Wells, "Diseases of the Ovaries," London, 1872.

to the gestation sac. In many cases it becomes flattened out and stretched, so completely blending with the other tissues of the wall that it may be lost sight of altogether as a distinct structure.

Martin<sup>1</sup> reports five cases of tubo-ovarian pregnancy in which the tube communicated with a small ovarian cyst. The ovum had ruptured into the cyst, and then had passed into the tube.

#### CORNUAL PREGNANCY.

Pregnancy in certain forms of developmentally defective uterus presents so many resemblances to ectopic gestation that the two subjects cannot be disassociated.

It is necessary to bear in mind the mode of origin of the normal uterus. At first, in the embryo, two well-marked rods of tissue appear on the posterior wall of the abdomen and pelvis. These become hollow, and are known as the Müllerian ducts. After the eighth week of foetal life these gradually blend in their lower and middle portions, the septum between them disappearing, giving rise to the vagina and uterus. It is not here necessary to name all the malformations which may arise from the various interferences with this normal development. Only certain ones need be indicated.

First, both parts may develop equally, but blending may not be complete, and a *uterus bicornis unicollis* may be formed. Either horn may become pregnant and the ovum may develop to full time and be delivered in the normal manner.

Again, only one horn may have developed from the first, giving rise to a *uterus unicornis*, all remains of the other horn being absent.

This horn behaves like the well-formed normal uterus. It may

<sup>1</sup> *Berl. klin. Wchnschr.*, Nr. xxii., 1892.

become pregnant, and the foetus may be delivered at full time through the vagina, but, owing to the oblique position of the uterus, rupture may occur as a result of the labour pains. This was illustrated in Moldenhauer's case, quoted by P. Müller.<sup>1</sup>

In another set of cases one horn is well-developed and the other only partially, being attached to it. This condition is known as *Uterus unicornis cum Cornu rudimentario*. It is this form only to which special attention need now be directed.

The rudimentary horn is found in various conditions. It may be throughout its length a thin solid band; it may be a very small tube which communicates with its own Fallopian tube and with the other horn; it may be solid at both ends and hollow in the middle; or it may be solid next the other horn and pervious in the outer part communicating with its Fallopian tube.

That pregnancy may occur in the rudimentary horn is a well-established fact. Not many cases have been recorded, but this is probably due to the fact that they have often been described as tubal. Kussmaul,<sup>2</sup> in 1859, was the first to collect all the undoubted cases, twelve in number, which had been published, and according to him, Dionis, in 1681, was the earliest to describe the condition. In 1883, Sanger<sup>3</sup> could only find records of fifteen additional cases, and in 1888 Himmelfarb<sup>4</sup> gathered only seven others, making a total of thirty-four.

Out of these thirty-four cases the foetus died in twenty-six before the mid term of pregnancy, and in two after this time. In six cases only did the ovum grow in the horn to full time.

In twenty-four cases rupture of the horn occurred and was

<sup>1</sup> *Op. cit.*, p. 205.

<sup>2</sup> "Von dem Mangel d. Verkrummung und Verdopplung der Gebarmutter." Wurzburg, 1859, pp. 124-163.

<sup>3</sup> *Centralbl. f. Gynak.*, Leipzig, 1893, Nr. xx., p. 324.

<sup>4</sup> "Ueber Nebenhornschwangerschaft," *Munchen. med. Wechschr.*, 1888, Nra. xvii., xviii.



fatal to the mother. In three cases lithopædion formation occurred; one of these was a four month, another a five month, and the third a full time case.

In two cases laparotomy for the removal of the pregnant horn was done at the seventh month, and in five at the full time. It is evident, therefore, that the tendency to fatal rupture is, as is the case with tubal pregnancy, great.

The rupture, however, tends to occur at a later period. In none of the cases to which I have just referred did it take place before the third month. No particular accounts of the nature of the rupture have been given, so that it is impossible to say how often it may have taken place into the broad ligament as well as into the peritoneal cavity, and no comparison can, therefore, be made in this relation with tubal pregnancy.

The duration and termination of a horn pregnancy are doubtless related to the degree to which the horn was developed. If the wall is very thin and contains but little muscle, the tendency to short duration and to termination by rupture will be more marked than where the wall is thicker.

In cases in which the pregnancy goes on to full time, according to Himmelfarb, the onset of an attempt at labour is either attended with no contraction pains, or with but a very few in the wall of the pregnant horn, owing to its thinness and the small amount of muscular tissue in it.

Cornual pregnancy may, in the living woman, be mistaken for ectopic gestation. On *post-mortem* examination the following anatomical relationships serve to distinguish the one from the other:—

1. In *infundibular* and *ampullar* pregnancies the round ligament is found attached to the normal uterus on the uterine side of the gestation sac. The normal appearance of the pregnant Fallopian tube is greatly altered.

2. In *cornual* pregnancy the round ligament is situated external to the gestation sac. The unimpregnated horn differs markedly in shape from the normal uterus. The Fallopian tube is found attached to the pregnant horn and is not necessarily altered. The pregnant rudimentary horn is attached to the opposite well-developed horn at the upper end of the cervix.

3. An *interstitial* pregnancy may be more difficult to distinguish from a cornual. The round ligament is situated external to the gestation sac in this case, though, if the pregnancy be partly interstitial and partly ampullar, it may be attached to the anterior aspect of the sac. The close incorporation of the

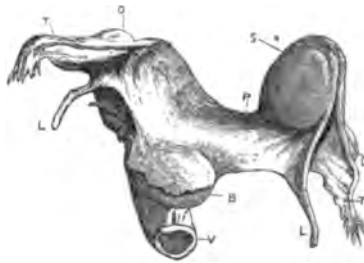


FIG. 13.—Pregnancy in a rudimentary horn. (TURNER.)

- |                     |  |
|---------------------|--|
| B. Bladder.         | F. Fallopian tubes.                    |
| V. Vagina.          | S. Pregnancy in cornu.                 |
| L. Round ligaments. | P. Inner part of left cornu; it is not |
| O. Ovaries.         | pervious but quite solid.              |

sac with the rest of the uterus and the absence of a separate horn serve, however, to distinguish this form from the cornual pregnancy.

In several cases in which the diagnosis of tubal gestation had been made, the application of these rules served to establish the incorrectness of the diagnosis (*vide* Turner's article, *Edin. Med. Journal*, May 1866).

As regards the nature of the attachment of the rudimentary horn to the well-developed one, Himmelfarb found that, out of

27 cases, the bit of horn internal to the gestation sac was canalised, and opened into the cavity of the other horn in 6 cases. In 2 cases the connecting portion was patent, but only in its middle part, its outer and inner ends being solid. In 19 cases it was not canalised but solid from the gestation sac to the junction with the well-developed horn.

The occurrence of gestation in a rudimentary horn whose cavity is not in communication with the rest of the uterus has led to interesting speculations regarding the manner in which such a pregnancy can be brought about.

The following suppositions are possible:—

1. The so-called solid portion of the horn may have been hollow before the pregnancy began—*i.e.*, after the spermatozoa had passed up and fertilised the ovum. Its closure may have resulted from swelling of the mucosa from decidual changes in it and obliteration of the small lumen in whole or in part. That this takes place can neither be proved nor disproved from the facts at our disposal.

It is more difficult to disprove it, since in any given case while we have the condition after pregnancy has begun, we have no record of the state of matters in the non-pregnant condition.

If closure took place in this way, however, careful examination of the solid stalk, especially in early pregnancy cases, should reveal changes in the central portion sufficient to indicate their nature. No such alterations have as yet been pointed out.

2. We know that, in the non-pregnant state, rudimentary horns are found with a perfectly solid band connecting them to the opposite horn, and it has not unnaturally been concluded by many that, when the same condition

is found along with pregnancy of the rudimentary horn, the spermatozoa must have reached an ovum from one or other ovary, having travelled up through the well-developed horn, and that then the ovum passed into the lumen of the outer part of the rudimentary horn through its Fallopian tube. In other words, there is either a wandering of the fertilised ovum outside the uterus from the ovary on the side of the well-developed horn to the opposite rudimentary horn, or the spermatozoa pass from the tube of the sound horn across the pelvis to the opposite side, fertilising an ovum from the ovary belonging to the horn which becomes pregnant. In favour of the first view are the cases in which the *corpus luteum* is found on the side of the non-pregnant horn. In favour of the other view are the cases in which it is found on the side of the pregnant horn; also, in cases in which the bodies of female animals have been examined after coitus, spermatozoa have been found in various parts of the pelvis.

As to the frequency with which these methods of fertilisation occur, Himmelfarb found that, out of the cases collected by him, only in six could the external wandering of the fertilised ovum from the other side be supposed to have taken place.

This subject has been much discussed, but as yet definite conclusions have not been arrived at. The first to describe this so-called external wandering was Eschricht of Copenhagen, in 1834. He based his theory on the facts observed in Brejer's case, in which there was no communication between the pregnant horn and the other save by a solid band, and in which the *corpus luteum* was in the ovary of the opposite side. In 1859, Kussmaul, from a careful study of Bischoff's experiments in

<sup>1</sup> Kussmaul, *op. cit.*

1842 on animals with a double-horned uterus, in which the latter had demonstrated an internal wandering of the ovum—*i.e.*, its passage inside the uterus from one horn to the other, and from his own studies, came to the conclusion that in the human female an internal wandering might occur, but never an external.

In 1862, however, from new observations published, he<sup>1</sup> altered his opinion, and believed that the latter might occasionally occur.

In 1879 Leopold<sup>2</sup> and Parsenow<sup>3</sup> performed experiments on animals, removing the ovary on one side and tying the tube on the other, before impregnation. Küstner<sup>4</sup> and others have made similar experiments. While Parsenow and Küstner got negative results, Leopold, Kireieff, and Bruzzi satisfied themselves that, in the dog, external wandering of the ovum could take place.

Recently, Lode,<sup>5</sup> in experimenting on rabbits, has found that charcoal particles, and also the ova of *ascaris lumbricoides suis*, if injected into the peritoneal cavity, were carried into the Fallopian tubes. He concludes that it is not necessary that the tube end should be in contact with the ovary in order to receive the ovum after the bursting of the Graafian follicle, but that the ovum is carried by currents to the tube, external wandering being thus possible.

Of interest in relation to cornual pregnancy is the question of menstruation. It is now well known that there is not always, in cases of the malformation of the uterus which we are now considering, accumulation of menstrual blood in the rudimentary

<sup>1</sup> *Monatschr. f. Geburtskunde*, Berlin, 1862, bd. xx., p. 225.

<sup>2</sup> "Experiment. Beiträge z. Ueberwand. d. Eies," Rostock.

<sup>3</sup> *Arch. f. Gynaek.*, Berlin, bd. xvi. 1880, p. 24.

<sup>4</sup> *Ibid.*, bd. xv., p. 259.

<sup>5</sup> *Arch. f. Gynaek.*, Berlin, bd. xlv.

horn. There seems to be, in some cases, no discharge of blood at all from the mucosa of this horn.<sup>1</sup> Were menstruation constant, leading to the accumulation of the retained blood, there can be very little doubt that pregnancy in the rudimentary horn would be unknown. Development of a fertilised ovum will probably occur only in those cases in which no menstrual discharge has occurred in the horn.

CHANGES IN THE OVUM AFTER ITS DEATH, WHERE IT IS NOT  
ABSORBED NOR DISCHARGED AS AN ABSCESS, BUT RETAINED  
IN SITU.

*Mummification.*—This is a change which appears to be associated with an absorption of water from the tissues of the foetus, and in most cases of the membranes and placenta as well, followed by a shrinkage of parts which produces a mummified appearance. Chiari<sup>2</sup> has described an interesting case which he dissected in 1876. A woman died at the age of eighty-two, and in her was found the remains of an ectopic pregnancy which had been carried for fifty years. On opening the gestation sac a full time shrunken foetus was found attached by a shrivelled cord to a shrivelled placenta. The latter along with the membranes formed a fibrous capsule which closely enveloped the foetus, and was adherent to it in parts. The cartilage and bone of the foetus appeared normal. The soft tissues were hard and darkened. The vessels and cavities contained whitish detritus. The organs were shrunken but retained their form; the brain, however, was changed into a shapeless red thick mass. On microscopical examination, the structure of the various parts could still be made out.

The most marked alterations are found in the tissues and

<sup>1</sup> Müller, *op. cit.*, p. 209.

<sup>2</sup> *Wien. med. Presse*, bd. xvii., p. 1092.

organs containing much fat. The fat is changed into margarin and cholesterin. The brain becomes a red-brown pulp containing margarin and cholesterin crystals and remains of the ganglion cells. The liver cells retain their characteristic shape. In the kidney the distinction between the cortical and pyramidal substance may be retained, and even the tubules may be found lined with epithelium.

The heart and blood vessels contain debris in which margarin crystals may be found, and also red blood corpuscles. The striped muscle looks like dried flesh, but under the microscope appears very like fresh muscle.

According to van Cauwenberghe<sup>1</sup> mummification is usually associated with some salt deposition in the membranes, in the fœtus or in both. In Chiari's case calcareous concretions were found in the shrivelled placenta and membranes, and crystals of unknown composition were found scattered through the fœtus.

*Adipocere formation.*—In some cases the soft tissues of the fœtus are converted into a soap-like mass—adipocere—in which are found the bones of the fœtus, either arranged somewhat in their normal relations to one another or irregularly disposed throughout the mass. In other cases the bones may be partly or wholly changed, so that all degrees of transformation may be found. The mass is usually coloured more or less uniformly with a golden-yellow tinge—probably due to alteration in the blood pigment. Along with this change may be found deposition of lime salts in various parts. Bland Sutton<sup>2</sup> has pointed out the tendency of adipocere fœtuses to adhere to the wall of the sac in which they lie.

Interesting cases are recorded by Wagner,<sup>3</sup> Bossi,<sup>4</sup> and Keiser.<sup>5</sup>

<sup>1</sup> *Op. cit.*, p. 145.

<sup>2</sup> L. Tait, *op. cit.*, p. 537.

<sup>5</sup> L. Tait, *op. cit.*, p. 536.

<sup>3</sup> *Op. cit.*, p. 374.

<sup>4</sup> L. Tait, *op. cit.*, p. 537.

With the exact nature and conditions of adipocere formation we are not perfectly acquainted. It is made by the union of a fatty acid with ammonia, and is structureless like soap. Fat appears necessary to its formation, but the other tissues of the body can undergo the change after it has begun. Moisture is an essential factor.

*Calcification.*—Lime salts may be deposited in different parts of the ovum in different cases. In most instances, as Küchenmeister<sup>1</sup> has shown, the body of the fœtus is not infiltrated. The membranes and placenta, and also the wall of the gestation sac, may be studded with calcareous nodules or plates, the fœtus being in a state of mummification or adipocere, but without any salt deposits in it; for this condition Küchenmeister has suggested the name of *Lithokelyphos* (κέλυφος, the membranes). Bossi's case<sup>2</sup> was of this nature, also that of van Graau and Schrant.<sup>3</sup>

Along with the deposit in the membranes there may also be calcification in the fœtus itself—a condition which Küchenmeister names *Lithokelyphopädion*. The fœtal deposit is in most cases merely superficial. Keiser's case<sup>4</sup> and also Fales'<sup>5</sup> are instances of this kind. Or salt deposit may be found scattered throughout the tissues of the fœtus.

The fœtus alone may be the seat of the calcareous change—the true *Lithopædion* of Küchenmeister. This is generally found superficially. Thus, in a case described by Cruveilhier<sup>6</sup> the fœtus was covered with a calcareous crust—thick, compact, yet fragile. Under it and easily separated from it was the mummified fœtus. It was as if the *vernix caseosa* had been altered. A

<sup>1</sup> *Arch. f. Gynaek.*, Berlin, bd. xvii., hft. ii.

<sup>2</sup> *Vide supra.*

<sup>3</sup> L. Tait, *op. cit.*, p. 536.

<sup>4</sup> *Vide supra.*

<sup>5</sup> L. Tait, *op. cit.*, p. 536.

<sup>6</sup> "Anat. path. gén.," tome iii., p. 570.



similar case is that of Parkhurst.<sup>1</sup> Recently Dean and Marnoch<sup>2</sup> have given a very full account of a specimen.

An interesting specimen in the Royal College of Surgeons was described by Cheston<sup>3</sup> in 1814, and by Doran<sup>4</sup> in 1881; the abdominal and thoracic viscera had deposits of lime salts, while the integument was infiltrated in various degrees in different parts.

In cases where there has been very marked salt deposit, the altered tissues may become very hard and resemble bone. The term *petrification* is sometimes used for this condition. An instance of this was published by Heiskell.<sup>5</sup> He found the gestation sac of bony hardness, and containing a fœtus whose outer covering was for the most part of the same consistence. Mojon<sup>6</sup> has described a case in which the fœtus throughout appeared to be a solid, hard mass.

Van Cauwenberghe,<sup>7</sup> Campbell,<sup>8</sup> and others have further described the formation of bone—ossification in the ovum. This is probably a mistake. I know of no case in which this was actually proved by microscopic examination. There is no reason to suppose that the so-called bone was anything more than very dense and hard calcareous deposit.

Müller<sup>9</sup> analysed the deposit in one case, and found it to contain salts of sodium, potassium, calcium, and magnesium.

The *rationale* of these changes is not thoroughly understood; they have been discussed chiefly by Albers<sup>10</sup> and van Cauwen-

<sup>1</sup> *Med. Times and Gaz.*, London, vol. i., p. 655.

<sup>2</sup> *Journ. Anat. and Physiol.*, London, vol. xxviii.

<sup>3</sup> *Med. Chir. Trans.*, London, vol. v., p. 104.

<sup>4</sup> Barnes, "On the so-called Lithopædion," *Trans. Obstet. Soc. London*, vol. xxiii., p. 170. Barnes also describes a specimen in St. Thomas' Hosp. Museum.

<sup>5</sup> *Arch. gén. de méd.*, Paris, 1828, tome xviii.

<sup>6</sup> "Bibliothèque de méd.," tome xxxiii., p. 411.

<sup>7</sup> *Op. cit.*, p. 149.

<sup>8</sup> *Op. cit.*, p. 142.

<sup>9</sup> "De Lithopædiis," Berlin, 1846.

<sup>10</sup> "Zur Geschichte des Lithopædion," *Monatschr. f. Geburtskunde*, Berlin, 1861, Bd. xvii., p. 42.

berghé.<sup>1</sup> The old idea held by some that the cretaceous deposits are an attempt at the formation of true bone, and that in some cases true bone is formed, must be entirely abandoned; the cartilage, which was described as being sometimes found in the gestation sac or in the foetus, was not real cartilage, but only the sac wall and membranes dried and hardened, probably often from inflammatory changes, or the shrivelled and toughened tissues of the mummified foetus.

The processes leading to these various transformations in the ovum are related not to living tissues, but to those whose nutrition has been stopped. Van Cauwenberghé believes that they are found not where death of the ovum occurs suddenly, but gradually. He thinks that in certain cases in which the foetus is believed to die suddenly, when full time is reached, it may in reality continue to live for a time, only gradually losing its vitality. In other cases, according to Albers, similar conditions are brought about through the formation of adhesions between the foetus and the surrounding sac by inflammation. These adhesions, vascularised with maternal blood, blend with the foetal tissues, and thus afford them slight nourishment after the cessation of the placental circulation. He mentions, in support of this statement the fact that, in cases where these adhesions are attached to the head, the cranial bones may be ossified, or teeth developed, to an abnormal extent. This connection, however, may be entirely a coincidence; in uterine pregnancy we know that children are occasionally born with excessive cranial ossification, or with teeth that have cut the gums. The same conditions may be found in ectopic foetuses, without having anything to do whatever with adhesions.

Many accurate observations have been recorded, undoubtedly, in regard to the formation of adhesions between the foetus and

<sup>1</sup> *Op. cit.*, p. 149.

the wall of the sac containing it, though the exact nature of these adhesions has not been carefully studied.

They may, in many cases, be purely foetal bands running between the amnion and the fœtus, though, in other cases, they would appear to be maternal inflammatory off-shoots from the gestation sac itself.

As to the part they can play in supplying nourishment to the foetal tissues, after the cessation of the placental circulation, little trustworthy information is on record. Van Cauwenberghe sums up his ideas as to the changes which are brought about in the ovum through these altered nutritive conditions as follows:—

“Les métamorphoses du fœtus ne sont que le terme final d’une atrophie résultant d’une oblitération ou d’une diminution notable des moyens de nutrition, et nous n’aurons pas de peine à convaincre le lecteur qu’il doit en être ainsi; dans le cas où la vie animale du fœtus s’éteint insensiblement, toutes les fonctions faiblissent: le système nerveux devient inactif, les tissus sont privés de leur stimulant fonctionnel, la nutrition est en défaut, et la transformation calcaire ou adipocéreuse s’opère de même que dans un membre paralysé; le tissu musculaire finit par ne plus se régénérer, tandis que la graisse se substitue aux éléments préexistants à mesure que le mouvement de décomposition inhérent à tout ce qui est organisé les fait disparaître. Mais dans les cas où le fœtus ne conserve qu’un reste de la vie végétative dépendant de la circulation maternelle, les phénomènes ont une marche plus rapide et peut-être un peu différente; le petit nombre de vaisseaux sanguins fournis par la mère au produit de la conception, ne peut suffire pour tout le corps de ce dernier, les seules parties voisines des adhérences pseudo-membraneuses y trouvent les éléments d’une nutrition plus ou moins parfaite, tandis que les parties éloignées,

bien qu'à l'abri de la putréfaction par leur rapport intime avec les premières, n'en ressentent nullement l'influence nutritive, et ne constituent qu'un véritable corps étranger susceptible de s'atrophier, de se fondre en quelque sorte sous l'action absorbante du kyste et des organes voisins. Cette absorption ou cette atrophie ne tarde guère à gagner mêmes les parties envahies par la circulation maternelle, où elle trouve une cause auxiliaire dans l'oblitération des vaisseaux, et le retrait insensible de cette nutrition empruntée. Elle peut avoir des conséquences variables: commençant par le liquide amniotique ou le produit d'une exsudation formée autour du fœtus, l'absorption peut produire sur les téguments de ce dernier un dépôt de phosphate calcaire, fourni par la surface absorbante qui l'entoure, être ainsi arrêtée presque à son début, et faire trouver à l'autopsie un fœtus momifié simplement encroûté. D'autres fois ce dépôt de sels calcaires ne se manifeste pas, et une durée plus longue du travail morbide produit aussi des altérations plus profondes: toutes les parties molles s'atrophient et disparaissent ou se réduisent à une membrane mince et transparente enveloppant le squelette, qui lui-même n'est pas à l'abri de la marche envahissante de cette atrophie."

Dean and Marnoch<sup>1</sup> believe that the calcification of superficial structures is explicable on the same lines as calcification in infants.

There is a preliminary coagulative necrosis, followed by the deposition of insoluble lime salts.

They think that, just as in Litten's kidney experiments,<sup>2</sup> the infiltration of the outer necrosed layers by maternal lymph was followed by calcification; this acts as a protective covering for the internal parts, and accounts for their preservation, and also for the varying degrees of calcification found in them.

<sup>1</sup> *Op. cit.*, p. 83.

<sup>2</sup> *Virchow's Archiv*, bd. lxxxiii., p. 508.

In most recorded cases in which these metamorphoses have occurred, the foetus is either full time or one advanced to beyond mid term. A small lithopædion is very rarely met with. Two specimens, each the size of a hazel nut, exist in the Vienna Pathological Museum, and are described by Bandl.<sup>1</sup>

The altered foetus may remain for many years *in situ*, and cause no disturbance to the woman. Küstner<sup>2</sup> mentions cases in which it was retained for 51, 54, and 57 years, and there are several instances in which it was carried for shorter periods.

A woman carrying a lithopædion may become pregnant and carry a child to full time in the uterus (*vide* p. 111). The ectopic mass may by its presence so seriously interfere with the normal emptying of the uterus that artificial delivery may require to be adopted. This was well illustrated in a case of Possi's, mentioned by Bandl,<sup>3</sup> where the lithopædion lay in the pelvis, and necessitated the induction of premature labour in three successive pregnancies.

An interesting case is recorded by Haderup,<sup>4</sup> in which, during the course of a uterine pregnancy, an old ectopic ovum suppurated and escaped to the surface, the normal pregnancy continuing to full time.

A lithopædion may remain quiescent for years, and in the end inflammation may develop around it of such severity that the patient's death may be caused. In other cases a patient may suffer from minor inflammatory attacks around the mass.

It is of interest to note that cases of *uterine* gestation have been recorded in which, after the death of the foetus, it has been retained for a time, and has undergone similar transformations to those above described.

<sup>1</sup> *Op. cit.*, p. 65.

<sup>2</sup> *Op. cit.*, p. 68.

<sup>3</sup> *Op. cit.*, 537.

<sup>4</sup> *Schmidt's Jahrb.*, Leipzig 1871, bd. cl.

Küstner<sup>1</sup> mentions a case of Buhl's in which, after a five months' pregnancy, the foetus, having been apparently dead for 1½ months, the following changes were found—apparently of the nature of adipocere. The skin was of soapy consistence, and also the walls of the various canals opening to the surface. Microscopic examination revealed many margarin crystals in this soapy tissue. The muscles, bones, and joints appeared unaltered. In the brain no nerves or cells were found, only numerous granules and nuclei, cholesterin and margarin crystals, amyloid bodies, and triple phosphates. The lungs were covered with the soapy substance. The heart showed the same change on its outer and inner walls; its muscle was degenerated, of a greenish brown colour, and contained fat globules and dark-red pigment granules. The liver and kidneys were covered with the whitish margarin containing substance; while throughout their substance were whitish fatty looking masses, colourless, needle shaped crystals, and hæmatoid crystals. The uterus was friable and of a greenish colour.

Cases have also been described in which, in a retained uterine ovum, salt deposition has given rise to the formation of a *lithopædion*. Hennig, in 1878, could collect only five cases in literature; one occurred in his own practice, which was observed by him along with Becker-Laurich.<sup>2</sup> The descriptions of the specimens in these cases correspond to those given where the pregnancy was ectopic.

In regard to these cases the doubt may be expressed as to whether some of them may not have been interstitial gestations not really in the uterine cavity. So intimate was the relationship of the uterine substance to the lithopædion mass that mistakes may readily have occurred in describing them. The formation of a lithopædion in normal pregnancy seems impro-

<sup>1</sup> *Op. cit.*, p. 660.

<sup>2</sup> Küstner, *op. cit.*, p. 660.

bable, and is difficult to understand, unless there be perhaps some maternal nerve disturbance or lesion, whereby the uterus has never been stimulated to expel its contents, or where the cervix has been closed after pregnancy has begun, and rupture of the uterus has not occurred at the time of labour.

SUPPOSED GROWTH OF THE PLACENTA AFTER THE DEATH  
OF THE FŒTUS.

For several years it has been the opinion of many authorities that in some cases the placenta continues to grow after the death of the fœtus. Observations upon which this opinion has been founded have been made by Lawson Tait,<sup>1</sup> Herman,<sup>2</sup> Knowsley Thornton,<sup>3</sup> Freeland Barbour,<sup>4</sup> and others. Berry Hart, in a recent paper,<sup>5</sup> has ably discussed this question, and the conclusion at which he has arrived I am able to corroborate from my own experience, viz., that there is no proof that growth does occur in the placenta after the death of the fœtus.

In the first place, it is stated that the growth only occurs in certain cases. Why this should be so it is difficult to understand. One would expect it to be a constant occurrence, or, at least, one might expect to be made aware of the variations in conditions affecting its growth.

Further, it does not seem to have been pointed out that, just as in normal pregnancy so in ectopic pregnancy, there are great variations in the size of the placenta at corresponding periods in different cases. This variation is greater, according to my experience, in ectopic gestation. Only an approximate idea of the period to which a pregnancy has advanced can be

<sup>1</sup> *Op. cit.*, p. 509.

<sup>2</sup> *Trans. Obst. Soc. London*, vol. xxix., p. 506.

<sup>3</sup> *Trans. Obst. Soc. London*, vol. xxix., p. 85.

<sup>4</sup> Hart and Barbour "Manual of Gynecology," Edin., 1882.

<sup>5</sup> "Selected Papers," Edin., 1893, p. 166.

formed from the size of the placenta. Variations also occur in the size of the fœtus, and the size relationship between fœtus and placenta is different in different cases.

It will not do, therefore, to compare one specimen with another without taking into account these individual variations. To prove the truth of the statement, it would be necessary to estimate, by some accurate method, the size of the placenta before and after the death of the fœtus, and to show by the microscope the seat and amount of the alleged growth.

That correct observations have been made in many instances as to *the increase in size of the placenta*, after the death of the fœtus or its removal by operation, cannot be disputed. The explanation of this increase as being *due to growth is the mistake that has been made*. The change in the size of the placenta is due not to growth of its tissue, but to extravasations of maternal blood, varying in size and number, which alter the continuity of the villi and their relations to one another.

I have already pointed out (p. 73) the constant tendency to the occurrence of hæmorrhages in the placenta of ectopic gestation. This tendency occurs through the whole of pregnancy, and is probably especially marked, as Hart says, in the subperitoneo-abdominal form, in which the placenta is situated above the fœtus, and is consequently displaced in its growth. The hæmorrhages may be few, small, and separate; they may be close together, and the general shape and size will not be greatly altered. But they may be so excessive that the placenta, from having been a discoid mass, may be changed to a thick ovoid or rounded mass, consisting of blood clot, in which are found scattered the torn up and broken villi. The colour of the placenta varies also according to the amount of organisation of the hæmorrhagic masses. There may thus be



found all stages, from the dark red or the plum coloured recent blood clot, to the old pale fibrous looking nodule of an advanced state of organisation.

In some of the intermediate stages the mass may resemble hepatised lung or a piece of liver. In some cases in which the patient has reached an advanced period of pregnancy, *e.g.*, that described by Hart<sup>1</sup> in the paper to which I have referred, the placenta may have become so altered that to the naked eye scarcely a normal piece of placenta can be recognised.

On examining<sup>2</sup> the placenta recently torn up with blood extravasation by means of the microscope the following conditions are found:—The villi are widely separated and scattered irregularly through the blood clot, many of them having been torn from both foetal and maternal attachments. In some parts masses of them are heaped together either against the maternal wall, against the chorionic layer near the foetal surface of the placenta, or in the blood clot. The blood may be seen commencing to organise, fine filaments of fibrin running throughout it, and a large number of leucocytes being often seen in various places.

When the old nodules are studied the mass is found to consist of dense fibrin, often canalised and in places very tough and fibrous.

The villi lying scattered about in this present various appearances; they possess very little covering epithelium, or, in most cases, have lost it altogether; they have become very fibrous, their vessels having completely closed, and being indicated only by lines of blood pigment. Others show a sort of hyaline degeneration. Throughout the fibrin masses hæmatoidin crystals are scattered in small or large groups. In different

<sup>1</sup> *Op. cit.*, p. 170.

<sup>2</sup> See my "Tubo-Peritoneal Ectopic Gestation," p. 33.

parts the organised fibrous tissue of a very low type is vascularised, and the vessels are, doubtless, in connection with the maternal system.

Why hæmorrhage should occur in the placenta after the death of the foetus does not in all cases appear evident. In those cases in which the foetus alone is removed from the sac, the placenta being left *in situ*, it is most likely due to the diminished pressure relations resulting from the removal of the contents of the amniotic cavity. Possibly, with the death of the foetus and the cessation of the circulation in the villi, there may be a lessened resistance on the part of the latter to the maternal blood circulating among them, and so, being in a deteriorated condition, their normal relations may be entirely altered by the pressure of this blood current flowing among them. That deterioration of the villi must soon follow the death of the foetus can scarcely be doubted. Their entire foetal origin must be remembered; there is no reason why they should continue to grow after the foetus, which is the sole reason of their existence, has ceased to live.

## CHAPTER V.

### GENERAL CONSIDERATIONS.

*Age.*—Ectopic gestation may occur at any time during the period of sexual activity. As Kiwisch<sup>1</sup> has pointed out, statistics show them to be most common between the ages of 28 and 40. Van Cauwenberghe<sup>2</sup> gives the following figures:—

In 130 cases—

Under 28 years there were	17.
Between 28 and 40	„ 96.
Above 40	„ 17.

Other tables are given by Hecker<sup>3</sup> and by Parry.<sup>4</sup> Both van Cauwenberghe and Hecker mention several of the cases they have noted as being over 60, without specifying whether the gestations were in progress or old standing ones represented by lithopædions, &c. Most likely they were examples of the latter. Neither of these authors mention in these cases the age of marriage,—an important point to know before we are justified in drawing conclusions from the tables.

*Primiparity and multiparity.*—Van Cauwenberghe<sup>5</sup> gives the following statistics:—

In 124 cases—

There were	21 primiparæ.
„ „	103 multiparæ.

<sup>1</sup> “Klinische lessen,” bd. ii., p. 175.

<sup>2</sup> *Op. cit.*, p. 171.

<sup>3</sup> “Beiträge zur Lehre von d. schwangerschaft ausserhalb d. Gebärmutterhöhle,” *Monatschr. f. Geburtshunde*, Berlin, 1859, bd. xiii., p. 98.

<sup>4</sup> *Op. cit.*, p. 29.

<sup>5</sup> *Op. cit.*, p. 171.

*History of married and child-bearing life.*—Hecker gives the following:—

In 31 primiparæ 11 had been sterile for several years, varying from four to fifteen. In 121 multiparæ 77 had previously borne children regularly, 31 had intervals varying from two to seventeen years between their last uterine pregnancy and the ectopic one, while the others showed irregular intervals between the times of their previous uterine gestation.

*Side of the gestation.*—Opinions vary as to the relative frequency of right and left-sided ectopic gestations.

Campbell,<sup>1</sup> Barnes,<sup>2</sup> and Hecker<sup>3</sup> assert that it is most frequent on the left side; May<sup>4</sup> and others, on the right side; van Cauwenberghe<sup>5</sup> found that in 58 cases 30 were right-sided and 28 left-sided. Parry<sup>6</sup> found that out of 185 cases, 100 occurred on the right and 85 on the left side. These statistics are inconclusive. As far as we know, there seems to be no tendency for ectopic gestation to develop on one side more than on the other.

*Site of gestation in tube.*—Parry<sup>7</sup> found that in 214 cases 31 were in the interstitial part of the tube, 34 in the pavilion, and 149 in the ampullary portion of the tube. Hennig<sup>8</sup> found that in 122 pregnancies, 77 were situated in the ampullary part of the tube. No statistics in regard to this point can be accurate unless cases of early pregnancy be examined; in many cases, after the first few months, owing to the enlargement of the tube, it is difficult to say where the pregnancy began. Still, there can be no doubt that the ampulla is the most common seat.

*Proportion of ectopic to normal gestations.*—There are no reliable statistics on this point; in making an estimate, it will be neces-

<sup>1</sup> *Op. cit.*, p. 112.

<sup>2</sup> *Op. cit.*

<sup>3</sup> *Op. cit.*

<sup>4</sup> *Am. Journ. Med. Sc.*, Phila., 1856, p. 820.

<sup>5</sup> *Op. cit.*, p. 82.

<sup>6</sup> *Op. cit.*, p. 89.

<sup>7</sup> *Op. cit.*, p. 89.

<sup>8</sup> *Op. cit.*, p. 102.

sary to bear in mind that women may have ectopic gestations which are overlooked, especially those in which the ovum becomes destroyed and absorbed at an early period, and those in which death of the women occurs from rupture of the gestation sac and internal hæmorrhage. Such cases should be taken into account in making statistics.

*Repeated ectopic gestation.*—A patient having had an ectopic gestation on one side may, at a later period, become pregnant on the other side.

In some instances the second has occurred while *the remains of the first* pregnancy, in the shape of a shrivelled-up ovum or lithopædion, have continued in the opposite side. (There is no case described, however, in which the second gestation has developed while the first was in active progress.) Several well-authenticated examples are recorded, one of the earliest being that of Primerose<sup>1</sup> in 1594.

Accounts of most of the published cases are given by Parry,<sup>2</sup> Abel,<sup>3</sup> Herman,<sup>4</sup> and Lawson Tait.<sup>5</sup>

It is also believed by some that an ectopic gestation may be repeated on the same side. This is based upon a case described by Haydon, Tyler Smith, and Braxton Hicks,<sup>6</sup> in which was found what was thought to be a ruptured three months' tubal gestation, adjacent to which was a smaller shrivelled fœtus; the latter was thought to be the remains of an *older gestation* (about four and a half years previously the patient was supposed to have been pregnant, and to have aborted, though no fœtus was found). This case is not conclusive. From the description, the uterus would appear to have been malformed

<sup>1</sup> *Op. cit.*, lib. iv., p. 316.

<sup>2</sup> *Op. cit.*, p. 144.

<sup>3</sup> *Arch. f. Gynaek.*, Berlin, bd. xlv., 1893, p. 55.

<sup>4</sup> *Brit. Med. Journ.*, London, 1890, vol. ii., p. 722.

<sup>5</sup> "Lectures on Ectopic Pregnancy," 1888, p. 46.

<sup>6</sup> *Trans. Obst. Soc. London*, vol. v., p. 280.

the so-called tubal gestation having really been a horn pregnancy. Moreover, the foetuses found may have been twins, the smaller shrivelled one corresponding to the *fœtus papyraceus* found in some cases of plural conception in uterine pregnancy; they may have developed in the same or in adjacent parts of the tube to begin with.

Recently, H. C. Coe<sup>1</sup> has described an interesting case of this condition which is beyond dispute. A patient who had carried the remains of a tubal or tubo-ligamentous gestation for twelve years became pregnant, the gestation occurring in the same tube external to the old sac. It is interesting to note, also, that the corpus luteum was found only in the ovary of the non-pregnant side, the case therefore appearing to be one of external wandering of the ovum.

It is difficult to understand how the ovum could have passed the old gestation. The explanation probably is that the old gestation had ruptured into the broad ligament, and had gradually become absorbed, the tube closing again and remaining pervious. It may, of course, be suggested by some that the ovum had passed to the opposite side through the peritoneal cavity—external wandering.

Bland Sutton<sup>2</sup> believes that repeated gestation in the same tube is an impossibility, on account of the alterations in the tube caused by pregnancy.

This I consider true for cases where a gestation has advanced as to affect the whole tube, but in cases where it has very early been destroyed, the ovum having disappeared, and the tube having remained pervious, so that an ovum could still pass along it, there is no reason why it should not again offer a place of development for a future gestation.

<sup>1</sup> "Internal Migration of the Ovum." &c., *Trans. Amer. Gyn. Soc.*, vol. xviii.

<sup>2</sup> *Op. cit.*, p. 367.

*Plural ectopic gestation.*—By this may be meant either a gestation on each side, two on one side in different sacs, or in the same sac. As to the first of these we have but scanty evidence, though there is no reason why the condition might not occur. Rowan<sup>1</sup> describes a case in which he operated for ruptured early left tubal pregnancy, the right tube being also several weeks pregnant; the placenta was partly separated and the foetus was not found.

As to whether two ova may develop in different parts of the same tube I can find no evidence save that of Boehmer,<sup>2</sup> who described a case in which the tube was enlarged in two different parts, one of which contained an early ovum and the other an ovum changed into a mole.

There is no reason against supposing that this may take place; it occurs in the uterus in certain cases of twin pregnancy. The condition would in such a case resemble that found in many of the lower mammals. It is interesting to note this in relation to my views<sup>3</sup> on the etiology of ectopic gestation.

We have more abundant evidence as to the development of a plural gestation in one sac analogous to what occurs in the uterus.

One of the earliest authentic cases is that recorded by Thomas Bell in 1756,<sup>4</sup> though Densing,<sup>5</sup> a century before, described a twin ectopic gestation in the abdomen, of whose nature we cannot be very certain. Other cases are described by Varnier<sup>6</sup> in 1785, Rupin<sup>7</sup> in 1860, Walter<sup>8</sup> in 1892, and by others during this century.

<sup>1</sup> *Australian Med. Journ.*, Melbourne, 1890, p. 265.

<sup>2</sup> "Observat. anatom. rar.," p. ii. <sup>3</sup> *Vide* p. 12.

<sup>4</sup> "Med. Comment.," Edin., vol. ii., p. 72.

<sup>5</sup> "Historia partus infelicia," &c., Groningen, 1662.

<sup>6</sup> *Journ. de méd. de Paris*, Paris, 1785, tome lxxv.

<sup>7</sup> *Gaz. d. hôp.*, Paris, 1860, No. 13.

<sup>8</sup> *Brit. Med. Journ.*, London, Oct. 1, 1892.

Trezevant<sup>1</sup> describes a case in which two foetuses were found on one side, one being between six and seven months old and the other five or six weeks; each was surrounded by its own membranes. Parry is of the opinion that this was either a twin gestation or that the small foetus belonged to a previous ectopic pregnancy. The latter opinion is most unlikely; it was either a case of twin gestation in the same or in an adjacent part of the tube, one foetus having died at an early period. This case should be compared with that of Haydon, already described.

*Concurrent ectopic and uterine gestation.*—There appears to be no doubt that different ova may become impregnated about the same time and develop, one in the tube, the other in the uterus.

Cases have been recorded by Loudon<sup>2</sup> in 1836, Whinnery<sup>3</sup> in 1846, Starley,<sup>4</sup> Cooke,<sup>5</sup> Galabin,<sup>6</sup> Browne,<sup>7</sup> and others.

*Intercurrent uterine gestation, or uterine gestation during the course of an ectopic pregnancy.*—There is no evidence that a gestation can develop in the uterus after an ovum has once fairly started to develop in a tube, or at a period during the growth of an ectopic foetus. The reason of this is evident; after a gestation begins, whether ectopic or uterine, no ova are shed. Where foetuses are found growing in tube and uterus, or in both tubes, they have developed from ova shed from one or both ovaries at or about the same time.

After an ectopic gestation has ceased to develop, however, whether the ovum be absorbed or not, pregnancy may take place in the uterus. This was long ago described by Albucasis, and also by many authors during the last two centuries. Not one

<sup>1</sup> Parry, *op. cit.*, p. 139.

<sup>2</sup> Campbell, *op. cit.*, p. 65.

<sup>3</sup> *Am. Journ. Med. Sc.*, Phila., 1846, p. 351.

<sup>4</sup> *New York Med. Journ.*, March 1873, p. 299.

<sup>5</sup> *Trans. Obstet. Soc. London*, vol. v., p. 143.

<sup>6</sup> *Trans. Obstet. Soc. London*, vol. xxiii., p. 143.

<sup>7</sup> *Trans. Am. Gyneo. Soc.*, 1881.



but several normal pregnancies may occur while a woman carries the remains of an ectopic gestation either as adipocere, lithopædion, or as a mummified mass. Thus Josephi<sup>1</sup> mentions one case in which a woman carried ectopic remains for sixteen years, and bore during this time four children; in another a mass was carried for forty-six years, two children being born. Campbell<sup>2</sup> gives one case in which seven children were born.

Parry's statistics as to the frequency of twin conception associated with ectopic pregnancy are seriously misleading. Out of five hundred ectopic cases he finds twenty-two—*i.e.*, one in twenty-three. He has included in these, however, twin tubal cases, concurrent ectopic and uterine cases and cases of intercurrent uterine. Among these, probably the last mentioned are the most frequent.

There is very scanty record of the formation of more than two fœtuses. Campbell<sup>3</sup> mentions two cases in which the products of these were found.

*Hernia of ectopic gestation.*—A number of cases of this condition have been recorded,<sup>4</sup> but careful study of them reveals much uncertainty as to their exact nature. In most of them the pregnancy may not have been ectopic, but may have been either cornual or even uterine.

There is no doubt, however, that a pregnant tube may be in a hernial sac, because we know that the appendages in the non-pregnant state may be there. It is stated that ectopic gestation has been found in most varieties of hernia—*e.g.*, inguinal, crural, and abdominal. It is also stated by some that hernia of part of the internal genitals is a cause of ectopic pregnancy. In regard to this *vide*, the chapter Etiology, pp. 1-15.

<sup>1</sup> *Op. cit.*, p. 126.

<sup>3</sup> *Op. cit.*, p. 111.

<sup>2</sup> *Op. cit.*, p. 111.

<sup>4</sup> Parry, *op. cit.*, p. 134.

*The fœtus in ectopic gestation.*—The fœtus may be as well developed as in uterine pregnancy, and if removed alive from the mother may grow to be a healthy child. In a large number of cases, however, the child is puny, and dies before, at, or soon after birth. The most important cause of the weakened condition is, probably, the progressive destruction of the placenta in ectopic cases as a result of hæmorrhage into it.

In quite a number of cases amniotic bands grow between the fœtus and the gestation sac wall.

Several interesting cases of head deformity have been described. Olshausen mentions one in which one side of the skull was indented just like the moulding of a head which has gone through labour in a rickety pelvis. Here it was due to pressure of the head against the spine of the mother. In other cases the head was flattened vertically or obliquely. The face, also, may be found greatly compressed.

These conditions were found both in living and dead fœtuses, but especially in cases where the child had been dead, the liquor amnii having been partly or wholly absorbed, whereby more pressure was brought to bear on the fœtus.

Various malformations may also be found—*c.g.*, clubfoot, dislocations of limbs, exomphalos, encephalocele, &c.

## CHAPTER VI.

### DEVELOPMENTAL CHANGES.

#### CHANGES IN THE TUBE WALL.

##### PERITONEUM.

THE peritoneal covering of the tube grows as the latter increases with the advance of pregnancy. In examining a large number of specimens, it is common to find the peritoneum presenting various appearances as a result of inflammation. The exact relation of the growth of tubal gestation to the occurrence of peritonitis cannot be determined accurately. In certain cases it has existed from before the commencement of the pregnancy; in other cases it is apparently caused by marked irritation, such as rupture of the tube into the broad ligament or peritoneal cavity. In some cases, it must be noted, no inflammation is to be found in early pregnancy; an abdomen may be opened, and the pregnant tube be found lying freely movable with its outer covering unaltered. It may with justice be said by some that there does not appear to be any good reason for believing that, so long as the ovum grows undisturbed in the tube, there is any greater tendency to the development of peritonitis than in the case of normal pregnancy in the uterus. This may be true as regards the early months, but not as regards the late months of gestation. The pregnant tube may undergo peritoneal changes like any tumour, but the thinness of its wall,

the growth of the placenta, and the occurrence of hæmorrhages in it, are doubtless the special factors which help to increase the liability to these changes.

According to the nature and degree of inflammation, one finds the surface of the tube presenting various appearances. In some cases the epithelium has entirely disappeared, being replaced by a small cell layer consisting of young connective tissue cells; in others the inflammatory products have undergone various chronic changes.

Occasionally one finds on the surface irregular masses of large more or less rounded cells, somewhat resembling decidual cells; they do not extend at all deeply into the substance of the wall, but are quite superficial, often projecting as tags from the surface.

These cell masses have also been noticed by Orthmann,<sup>1</sup> Werth,<sup>2</sup> and Zedel,<sup>3</sup> but they are not of frequent occurrence. Their origin is not absolutely certain, but they are in all probability proliferated masses of the peritoneal cells. I have seen the same appearance in specimens of peri-salpingitis not associated with pregnancy.

In a few cases, also, I have found under the peritoneum small spaces lined with cubical epithelium. These have been thought by Orthmann to be the ends of deep recesses of the tubal mucosa. No direct connection has been made out, however. Zedel thinks they are sections across folds of the peritoneum. Against this view is the fact that they have too close a resemblance to gland-like spaces, the cells being in close contact with the wall, and showing no signs of irritation when the superlying

<sup>1</sup> "Ueber Tubenschwang. in d. erst. Monaten."

<sup>2</sup> "Beiträge z. Anat. u. z. operativen Behand. d. Extrauterinschwang.," Stuttgart, 1887, p. 119 *et seq.*

<sup>3</sup> "Zur Anatomie d. Schwang. Tuben," &c., *Ztschr. f. Geburtsh. u. Gynäk.*, Stuttgart, bd. xxvi., p. 137.

peritoneum may be either destroyed or proliferated. Moreover, I have not been able in serial sections to trace these spaces to the surface. They are in all probability embryonic in origin, like many other similar spaces to be found elsewhere within the folds of the broad ligament. It is well known that they may sometimes distend and give rise to small cysts in the outer part of the tube wall, and though this be an uncommon occurrence, the mere spaces may be found in a good number of cases.

Foldings of the surface are undoubtedly occasionally met with—due either to the remains of the early foetal condition or to inflammation. In these cases there is no difficulty in tracing the irregularity of the wall outline in a section.

It is of the greatest importance to bear in mind that in advanced ectopic gestation peritonitic adhesions may make it very difficult to determine the relations of the gestation sac. The examination of cases either at the time of an operation or by ordinary *post-mortem* dissection may lead to an erroneous impression regarding their nature.

The evidence that has been brought forward by Berry Hart and myself (*vide* chapter on Classification) has been sufficient to show the errors into which the older authorities have been led in their descriptions of the varieties of extra-uterine pregnancy; and we have shown that, for the proper study of difficult cases, it is absolutely necessary, in the first place, to employ the sectional method, the body being frozen and cut into a series of slabs, in which the relationships of parts—especially of the peritoneum—can alone be studied; auxiliary to this method are dissection and microscopic examination of the parts.

#### MUSCULAR PART OF THE WALL.

There is a considerable difference of opinion as to the changes in the muscular layer as a result of pregnancy. Some authors

describe hypertrophy, others hyperplasia, and others both hypertrophy and hyperplasia; whereas others deny that either of these changes occur. It is again said by some that the muscle gradually shrinks and disappears from the very beginning of pregnancy.

Many different statements also are found regarding the thickness of the tube wall. The apparent want of harmony in these statements, which are, for the most part, based on accurate observations, is easily explained when it is understood that the gestation sac varies in thickness in different parts and at different periods of pregnancy.

There can be no doubt that the development of the ovum induces early changes in the muscular part of the tube similar to those which take place in the uterus during normal pregnancy. There occurs both hypertrophy and hyperplasia of its fibres. This can be demonstrated if one studies carefully a series of tubal gestation sacs at different periods. These changes are chiefly marked during the first two or three months. How long they may continue it is impossible to say, though it can be positively stated that they occur but slightly after three months; variations are found in different cases.

It would appear that after an early period the muscle is not able to respond to the rapid development of the ovum as does the normal fruit holder—the uterus. The connective tissue, however, increases throughout, growing to be far greater in quantity than the muscle.

The normal relations of the muscle, also, become entirely destroyed. The bundles get broken and separated, and are found running in every direction. In the late months considerable portions of the wall may contain no muscle whatever, owing to the marked scattering of fibres which has taken place.

In many cases atrophy of the fibres may accompany these alterations.

When the tube ruptures early into the broad ligament, and the ovum continues to develop, it is likely that there will be a less marked increase in the muscle, owing to the removal of some pressure stimulus from the interior of the tube, as a result of the new accommodation partly found by the ovum within the broad ligament.

As regards the thickness of the gestation sac no definite measurements can be given. It may vary from one-thirty-second of an inch to three-sixteenths of an inch, and may even sometimes be thicker. Marked thickening is usually due to inflammation of the outer part of the wall, or to hæmorrhages into its substance. Great thinness at any point is due to the stretching of a part, thin or weak from the first, not able to withstand the pressure of the increasing contents. Rapid thinning occurs where great hæmorrhage takes place in the tube distending it.

As far as my observations go, it appears that that portion of the wall to which the placenta is attached is somewhat thicker than the rest of the tube wall—largely due to the enormous development of blood vessels in that portion. Abel<sup>1</sup> says that this part hypertrophies, and that the rest of the wall thins and atrophies.

#### MUCOUS MEMBRANE.

##### *Decidua Vera.*

Varying opinions are held regarding the formation of a decidua vera in the tube. Some are to the effect that no such change takes place; some, that the whole mucosa is altered;

<sup>1</sup> "Zur Anat. d. Eileiterschwang." &c., *Arch. f. Gynaek.*, Berlin, 1891, bd. xxxix.

others, that part shows the change; while others are to the effect that it is developed only in that portion of the mucosa in contact with the ovum.

The uncertainty in our knowledge of the decidua has arisen partly from an insufficient microscopic examination of cases, and partly from the study of tubal pregnancies too far advanced to furnish accurate information regarding either the nature or the extent of the early vera. Conclusions have been formed from insufficient data. Up to the present time there has not been described an early stage decidua vera, *i.e.*, just before or at the time of the attachment of the ovum. Observations have only been made in cases where changes have taken place owing to pregnancy having advanced for weeks or months.

Careful investigation, beyond doubt, establishes the fact that a vera is always formed. Occasionally cases are reported, *e.g.*, those by Hennig<sup>1</sup> and Werth,<sup>2</sup> in which no decidual tissue was noticed by them in the sections examined; also, cases are found in which it is small in amount. These cases, however, prove nothing with regard to the early vera; they only hold good with reference to the specimens in question, which represented various degrees of advancement in pregnancy. It is necessary to bear in mind that different cases present individual variations, and that the alterations which take place as a result of pregnancy progress rapidly—more so than in uterine gestation, and show many variations, both in degree and rate of change, in different instances. Above all, before conclusions can be formed, it is necessary to examine a large number of sections from each specimen, in order to arrive at the truth. One portion of a tubal gestation sac may differ greatly from another; one part may show numerous well-marked decidual cells, others only a

<sup>1</sup> *Op. cit.*, p. 106.

<sup>2</sup> *Op. cit.*, p. 104.



few, and others none at all. Insufficient examination may, therefore, it is easy to see, lead to error.

As to the extent of decidua vera which is formed, it can now be definitely stated, from the examination of my own material and the analysis of many well-recorded cases, that it varies considerably in different cases. Thus, a large portion of mucosa may rarely undergo the change; more commonly a small circular band around the lumen, or only a portion on one side. The explanation of these variations is considered in the chapter on Etiology. There are also many differences found in the thickness reached by the vera.

*Structure.*—I am here able to describe the decidua vera at an earlier period of formation than has yet been recorded. (The case in which this occurred is referred to on page 10.) The only portion of the mucosa affected was an irregular circular band in the ampulla, averaging about half an inch in width. The thickness of the whole tube at this part was about seven-sixteenth inches, elsewhere it was thinner.

On transverse section the thick layer of decidua is well seen. It is irregular in its inner surface owing to the projections of the folds of the mucosa; these are, however, very short and much simpler than are the folds in the ampulla in the normal non-pregnant tube. The resemblance is much nearer the condition found in the uterine end of the tube. Moreover, the nature of the folds differs greatly from the normal tube, in which they extend well into the lumen as delicate branching processes (as seen in transverse section) which occupy the entire lumen. Here they form thickened projections—club-shaped, finger-shaped, wart-shaped, &c.—extending inwards for a short distance, but not filling the entire lumen.

Between the folds the vera shows different degrees of thick-

ness, so that it is impossible to give a measurement which would accurately represent it.

The minute structure of the decidua is shown in Plate III., Figs. 1, 3, and 4, and to best understand the changes from the normal condition which have taken place, it is interesting to compare with them Plate II., Fig. 3, and Plate III., Fig. 2.

The sections show that, just as in the case of uterine pregnancy, the vera consists of:—

1. A superficial compact layer;
2. A deep spongy layer.

The compactness of the superficial or upper layer is due to two causes—viz., the adhesion and fusion in many parts of the free ends of the mucous folds, and also the early multiplication in this layer of large decidual cells.

The spongy appearance of the deep layer is due to the existence of spaces which are the shut off recesses between the bases of the mucous folds. Some of these, however, may have existed from the beginning as gland-like cavities in the mucosa, forming part of a general abnormal condition of this portion of the tube. Plate II., Fig. 1, represents the transverse section of the non-pregnant tube in a case of early pregnancy in the opposite tube. The striking resemblance of the mucosa to that of the uterus is very evident. In it no fringes are seen, the mucosa being more or less of uniform compactness, and containing many gland-like spaces. In other parts of the tube the same condition is found less developed, the more normal tubal characters being better marked, though nowhere very well developed. This specimen is also noticed under Etiology. In the normal tube it is now believed that no glands exist in the mucosa.

*Epithelium.*—Epithelium is found on the surface of the decidua and in the spaces of the deep layer. On the surface it differs greatly from the normal columnar ciliated epithelium

lining the tube, being flattened to various degrees, the cells in several parts appearing to be of a low cubical nature. The cilia have entirely disappeared, the cell outline is often irregular, the cell substance granular and degenerating, so that the nuclei appear relatively larger than in the normal cells. In various places the cells form a mass of granular debris, the nuclei being also seen in different stages of degeneration. Thus the surface of the decidua in several parts has lost its epithelial covering.

In the spaces of the spongy layer the epithelium is not so altered as on the surface of the decidua. In most of them it is more or less attached to the wall, though in many are seen several detached masses of cells in early stages of degeneration. The few spaces completely lined resemble greatly the deep ends of the glands of the mucosa in early uterine pregnancy.

The explanation of the more advanced stage of degeneration in the superficial epithelium is probably connected with the formation of decidual tissue first of all in the upper layer of the decidua. It may be that the great and rapid increase of the large decidual cells interferes with the nutrition of the superjacent epithelium, as well as causing it to be somewhat stretched and its cells partially separated, because they do not grow in correspondence with the connective tissue.

Nowhere is there any appearance suggestive of the transformation of the epithelial layer into the decidual cells—a change thought possible by Frommel, and recently so strongly insisted on by Dixon Jones.<sup>1</sup> The latter author makes the remarkable statement that the epithelial cells split up into cells of a mucoid type, which afterwards develop into decidual cells. I can find no corroboration of this statement. He has probably misinterpreted what are mere degenerative changes in the cells, or has

<sup>1</sup> *Am. Journ. Obst.*, N.Y., 1893.

described stages of development in the connective tissue decidual elements.

There can be no doubt that the epithelium lining the tube plays no rôle in the formation of the decidua. The stimulus which leads to the development of the tissue finds no response save in the sub-epithelial structures; the epithelium is from the first passive, and gradually disappears, because it is not required to help in the establishment of the necessary connection between foetal and maternal parts.

*Connective tissue.*—Great alterations from the normal connective tissue of the mucosa take place. In the normal tube this tissue is small in amount, of a modified embryonic nature, consisting mainly of rounded, oval, and branching cells, with an intercellular stroma slightly fibrillated.

In the early stage of decidua formation, which begins in the upper layers, both hypertrophy and hyperplasia of all the elements take place, being especially marked in the cells which develop the characteristic appearances that have led to their denomination as "decidual cells." As far as I can judge from my sections, the very earliest change seems to be hypertrophy of pre-existing structures.

The decidual cells vary in shape, being rounded, oval, spindle, irregular, and branching; in many parts they are connected by delicate branching filaments. Each cell contains a large round or oval nucleus; *some contain two or three nuclei. Cell multiplication is found in different parts.* As regards the arrangement of the cells, no particular plan seems to be followed. Sometimes they lie with their long axes parallel to the surface, but they are also found running obliquely in various directions.

Throughout the decidua leucocytes are seen varying in numbers in different parts. They may or may not be most abundant

where the decidual cells are farthest advanced. My sections show that in the earliest stages they are not particularly noticeable.

They are far more numerous in the second and third months and most probably are to be associated with the great decidual vascularisation at those periods.

I can find no evidence whatever in favour of the view expressed by Hennig,<sup>1</sup> Ercolani,<sup>2</sup> and others that leucocytes are transformed into decidual cells.

Some authors have described the *first formation of decidual cells* as occurring around the vessels of the mucosa. In my sections this is not so. The changes may begin anywhere between the vessels.

*Blood vessels.*—At this early period there is not much alteration in vessels. The capillaries of the mucosa are increased in size, being here and there dilated to form small spaces. These are lined by a single layer of endothelium, which rests on the surrounding connective tissue. These changes appear to be most marked in the deeper layers of the decidua. The arteries and veins also show slight increase in size.

#### *Decidua Serotina.*

When the ovum becomes attached to the tube wall, that part of the vera in contact with it grows more rapidly than the rest of the decidua, and is known as the serotina. This must have a greater area relative to the whole vera than in the case of uterine gestation.

When the serotina reaches its greatest thickness cannot be definitely stated. There are undoubtedly variations in different cases. It is certainly not later than the end of the third month,

<sup>1</sup> *Op. cit.*

<sup>2</sup> "Della struttura anat. d. caduc. uteri nei casi di gravid. extrauterin," Bologna 1874.

probably usually some time during the third month. After this period it becomes thinner.

*Progressive Changes in the Decidua.*

*Epithelium.*—The degenerative changes already described in the surface epithelium lead largely to its disappearance. Any that exists when the ovum becomes attached is very probably removed by the outer layer of the proliferated foetal epiblast, which appears to have a trophoblastic action, just as is the case in several other mammals.

In the spaces of the spongy layer the epithelium mostly disappears, and the spaces become almost entirely obliterated. Here and there may be found a space, usually running parallel with the surface, which is entirely lined with cubical cells, or partly lined, the other cells lying in the lumen. In other places the walls of the space may be pressed together or separated by a double or a single row of cells, or by degenerated ones. These cells are quite distinct from the decidual tissues surrounding them. For the most part, however, these appearances have disappeared before the second half of pregnancy is reached.

*Connective tissue.*—The inner irregular surface of the early decidua, due to the projecting free edges of the mucous folds, becomes early somewhat smoother, owing to the increased fusion of the folds and the swelling of the whole mucosa. A few projections, however, remain unobliterated.

The early recognised distinction of compact and spongy layers becomes gradually lost. This is, apparently, mainly due to the extension downwards into the deep layers of the decidual changes causing the spaces to become gradually obliterated.

The capillary dilatation which at first appeared to take place

in the deep layers, thereby adding to the spongy appearances, becomes equally characteristic of the upper layers.

In this way, after the early months, the decidua appears of fairly uniform consistence, broken mainly by the blood spaces, which in their well-formed condition appear to be largest near the surface.

On minute examination, the progressive changes are found to be as follows:—

The decidual cells, which at first run in all directions, tend to lie with their long axes more or less parallel to the surface; this probably results from the increasing pressure of the growing ovum. Many exceptions to this general rule are found, however. They are found especially gathered in groups, or in rows parallel to the surface, or regularly or irregularly scattered throughout the tissue.

The cells gradually lose, to a great extent, their original characteristics—*i.e.*, their well-marked outlines, their distinctness from the intercellular substance, and their anastomoses.

They become less numerous relative to the size of the decidua as pregnancy advances. This results from two factors at work—*viz.*, the very slow increase in the number of the cells after the early weeks, along with a marked increase in the amount and density of the intercellular tissue. The extra-nuclear cell substance takes part in the formation of the latter, and very often seems to be blended with it, so that the cell outlines are more or less lost. The nuclei lose their large well-rounded outlines and tend to become more irregular; in many places they shrink away from the surrounding intercellular material covered with little or no cell substance, and thus lie in spaces.

They become more granular, and in many cases often appear to be breaking down.

As a result of these changes, the decidual cells by the end of

pregnancy have largely disappeared, or have lost their original characteristics. Here and there, however, it is to be noted that parts of the decidua, even in the late months, may contain groups of large characteristic cells.

The intercellular substance in the early stage is of a delicate homogeneous character. It gradually becomes denser and coarser, staining more deeply; its consistence is not uniform, but shows considerable variation. It becomes irregularly coarsely and finely fibrillated. At the end of pregnancy this forms almost the entire thickness of the decidua, and it cannot be very easily distinguished from the fibrous tissue forming the rest of the wall of the gestation sac. Very few leucocytes are found at this time.

From an early period of pregnancy there takes place what is apparently marked condensation of this intercellular substance, characterised by the deep stain which it takes on. It occurs in the early months chiefly at or near the surface, where, it is to be noted, the decidual cells begin to show the earliest signs of degeneration. This degenerative change is not a continuous one, but occurs irregularly at different intervals.

It may extend inwards obliquely from the surface. Here and there it also goes on at some distance below the surface. The nature of this change is not quite certain, though it is very likely to be associated with the degeneration of the cell nuclei. The whole degenerative process seems to be a kind of coagulation necrosis. This appearance must be carefully distinguished from that due to the staining of blood fibrin which may be found lying on the surface of the decidua or in its substance resulting from blood extravasation. Occasionally the superficial decidua may be so torn up that it cannot be distinguished from the fibrin.

Besides these changes in the serotina must be remembered



its diminishing actual growth after the early months, and the effects of the pressure of the increasing ovum. Its relation to the foetal structures in contact with it will be considered later.

*Blood vessels.*—The earliest change is one of enlargement, as has been described, especially in the capillaries of the mucosa, giving rise to the large blood sinuses of the decidua. This becomes more marked in the early weeks as the serotina develops. After a time a most noticeable change takes place in these sinuses, especially marked in those near the surface, consisting in the *proliferation of the endothelium*. It begins independently in different vessels; in some parts the change is only slightly marked, and in others extremely well marked. It may go on at several different points in the same sinus wall, or may affect the whole wall at once.

In most cases the proliferation does not greatly diminish the lumen of the sinus, but occasionally this does take place. The cells appear to multiply rapidly; they are mostly oval or rounded, in some cases spindle-shaped on section. The nuclei are large, oval or rounded; in parts they can be seen in a state of division. The cell substance is small, and stains faintly with eosine; the lines of division between the cells are often difficult to make out.

When this growth of the endothelial cells begins it is impossible to state definitely, certainly some time in the early weeks.

Of special interest, however, is the outward extension of these cells into the surrounding decidual tissue, the homogeneous intercellular substance apparently becoming broken up and disappearing before the invading cells, probably by absorption.

In this way a considerable area in the neighbourhood of some of the sinuses comes to be occupied by the cells. In several parts, where the sinuses are situated near the surface of the

decidua, these cell masses may work their way upwards until they form the most superficial layer of the serotina, thus coming into direct contact with foetal structures.

The arteries and veins here and there show the same endothelial proliferation, though to a less extent, and without the extension outwards to surrounding parts. Occasionally in the muscular part of the wall a vessel may show the change; and here, as well, there may be some thickening of the whole intima of an artery. In several vessels free cells may be found which have been thrown off from proliferating masses.

The occurrence of these endothelial changes is of extreme interest, and it is well to study them in the light of recent important investigations into the nature of the changes in the mucosa of certain mammals during pregnancy, especially in the Insectivora.

Hubrecht,<sup>1</sup> in his valuable work on the placenta of the hedgehog, raises speculations as to the possibility of there being close relationship in placentation between the Insectivora and the human female. From the conditions which I have found, it seems to me that there is a good deal of evidence for Hubrecht's statement that the phenomena of placentation in man bears more resemblance to those found in the hedgehog than in any of the lower mammals with which we are acquainted. If this phylogenetic relationship can be completely established in regard to the placenta, it will help to emphasise the importance of the statements made by Huxley<sup>2</sup> regarding the position occupied by the Insectivora among the mammalians. From his studies of comparative anatomy and of palæontology, he regards them as the order which holds the central and primitive place among the monodelphian mammals.

<sup>1</sup> "The Placentation of *Erinaceus Europæus*," &c., *Quart. Journ. Micr. Sc.*, London, Dec. 1889.

<sup>2</sup> *Proc. Zool. Soc. London*, 1880.

In the early formation of the decidua in the hedgehog, Hubrecht has shown that there is an enormous proliferation of the endothelium of the maternal sinuses, which takes place to such an extent that a well-marked layer is formed which enters into close relationship with the fetal epiblast.

The layer is called by him *trophospongia*. A similar change occurs in the decidua of the bat. Frommel<sup>1</sup> gives to the layer the name "epithelial," but Hubrecht shows that it is identical with the trophospongia of the hedgehog.

In my tubal pregnancy specimens there can be no doubt as to the trophospongia formation. It differs from that of the hedgehog in not occupying such an important position in the serotina; it is relatively much smaller, and does not occur uniformly throughout it as a well-defined layer. It varies greatly in different parts, and may help to form the surface of the decidua in only a small extent. Moreover, it can only be well recognised in the early months. It seems to undergo retrogressive changes, so that at the end of pregnancy no marked traces of it can be found in the decidua.

As to changes in the adventitia of some of the arteries described by Lederer<sup>2</sup> and others I can say nothing. I have found no instances of it.

The relation of the decidual blood spaces to the placental circulation is described afterwards, p. 150.

#### *Decidua Reflexa.*

There has been much dispute as to the formation of a reflexa. The older writers—*e.g.*, Kiwisch and Virchow<sup>3</sup>—who denied the existence of even a decidua vera, never thought the develop-

<sup>1</sup> "Ueber d. Entwicklung d. Placenta von *Myotis murinus*," Wiesbaden, 1888.

<sup>2</sup> "Beiträge z. Anat. d. Tubarschwang.," Berlin, 1888.

<sup>3</sup> Zedel, *op. cit.*, p. 110.

ment of a reflexa possible. Recent observers—*e.g.*, Hennig,<sup>1</sup> Frommel,<sup>2</sup> Wyder,<sup>3</sup> Orthmann,<sup>4</sup> Zedel,<sup>5</sup> Abel,<sup>6</sup> Winckel,<sup>7</sup> Eugen Fraenkel,<sup>8</sup> and others, differ considerably in regard to the frequency of its occurrence as well as regards the nature and extent of its structure.

In analysing the cases upon which so many varying opinions are based, one finds that many of them are of such a nature as to furnish no trustworthy evidence in regard to the reflexa. It is of extreme importance that very early cases should be studied in this connection, and studied with great minuteness. The conditions relating to the formation of a reflexa differ considerably in tubal and uterine pregnancy. In the latter, we know, the reflexa is of constant occurrence, and passes through stages which vary but little. Its origin—*viz.*, the blending of the free edges of the rapidly thickening serotina above the ovum, which thus gets completely imbedded, is now well recognised. The reflexa, thereafter, until it is united to the *vera* at the beginning of the third month, acts mainly as a support to the ovum, though it doubtless at first also serves to a slight extent as a source of nutriment to it. The size of the uterine cavity at first, and its rapid increase as pregnancy advances, probably renders necessary the support of such a temporary structure as the reflexa.

In the case of the tube the relation between the size of the ovum and that of the lumen of the tube is altogether different. The latter is relatively very much smaller than the uterine

<sup>1</sup> *Op. cit.*, p. 106.

<sup>2</sup> "Zur Therap. u. Anat. d. Tubenschwang," *Deutsches Arch. f. klin. Med.*, Leipzig, bd. xliii., pp. 91-102.

<sup>3</sup> "Beiträge z. Lehre von d. Extra-uterinsch.," &c., *Arch. f. Gynaek.*, Berlin, bd. xxviii., p. 392.

<sup>4</sup> *Op. cit.*, p. 31.

<sup>5</sup> *Op. cit.*, p. 123.

<sup>6</sup> *Op. cit.*, p. 30.

<sup>7</sup> "Lehrbuch d. Geburtshülfe," Leipzig, 1889.

<sup>8</sup> *Arch. f. Gynaek.*, Berlin, bd. xlvii., chap. i.

cavity. It, no doubt, varies in different cases. In some the lumen may be so small that from the first it may be in very close relation to the ovum, and, as the mucosa thickens to form the decidua, it may soon get in contact with the ovum on all sides, so that the formation of a distinct reflexa is impossible.

In other cases the lumen may be larger, the ovum attaching itself to one side of the tube, the decidua vera thickening and attempting to form a reflexa; this may never reach completion, however, because the free surface of the growing ovum meets the mucosa opposite it, not allowing the edges of the reflexa to meet. In a few cases, where the tube lumen is exceptionally large, a complete reflexa may be undoubtedly formed. A well-preserved specimen of this is to be seen in the museum of the Royal College of Surgeons, Edinburgh.

*Structure.*—The reflexa has much the same structure as the superficial portion of the serotina. In it, however, the degenerative changes, which appear to be also of the nature of coagulation necrosis, progress more rapidly, and it has a large proportion of intercellular substance and fewer decidual cells than the serotina of the same age. In different cases it shows great vascularity, especially near the attachment to the serotina. Eugen Fraenkel<sup>1</sup> says that small arteries and veins may be sometimes found near the base, but that at the pole only capillary spaces are found. Blood is often found escaping from the sinuses into the surrounding decidual tissue, or it may burst through the reflexa either on its inner side coming into relation with fetal structures, or on its outer side forming a clot in the tube outside the gestation sac. Rupture of reflexal vessels is probably the main source of blood found in that part of the tube outside the gestation. Very slight endothelial proliferation appears to take place in the reflexal

<sup>1</sup> *Op cit.*, p. 161.

sinuses. On the outer surface may be found in places remains of the original epithelium lining the tubal mucosa, cubical, flattened, or broken down. Over the greater extent, however, it has completely degenerated.

On its inner surface a greater or less area along with the serotina forms part of the site of attachment for the permanent placenta, the rest of it being related to the temporary *chorion læve*.

This fact, along with the already described hæmorrhagic tendency in the reflexa, helps to explain the almost constant occurrence of blood effusions in the placenta or membranes of tubal pregnancy. They often reach a considerable size, and may lead to the destruction of the fœtus and the formation of a hæmato-salpinx.

Where the reflexa is not destroyed completely by blood effusion, it becomes stretched and thinned, and pressed by the growing ovum against the surrounding portion of the decidua vera, to which it becomes blended at a much earlier period than in uterine pregnancy.

I have no specimen in which it has come into contact with a portion of the mucosa unaltered by decidual formation, and cannot, therefore, say what takes place in such a case.

#### *The Tubal Mucosa outside the attachment of the Ovum.*

This part of the mucosa varies in different cases. Sometimes a part or the whole of it may undergo decidual changes, though, as pregnancy advances, the decidual cells gradually disappear. In some cases no changes are found in the mucosa in the early weeks, the epithelium being apparently normal; in other cases inflammatory changes, slight or marked, have been observed, though not always with disappearance of the epithelium; such changes may have existed before the

pregnancy, or may have followed it. When blood is effused into the lumen the folds of the mucosa are pressed against the wall and massed in irregular heaps.

As the gestation advances, the membranes take up more and more of the lumen of the tube, which also undergoes enlargement; the mucosa outside the ovum is gradually stretched, thinned and broken up, the original folds becoming separated and the epithelium flattened and cast off. The whole tube thus gradually tends to become part of the gestation sac which is lined by the placenta and membranes. At full time, however, small portions of tube may still remain little altered between the gestation sac and uterus.

Olshausen<sup>1</sup> has described an interesting eight months' tubal gestation in which the part of the tube between gestation sac and uterus remaining pervious, and communicating with the amniotic cavity, allowed of the escape of liquor amnii in small quantities from time to time.

#### RELATIONS BETWEEN OVUM AND DECIDUA.

##### EARLY IMPORTANCE OF FŒTAL EPIBLAST.

Neither in uterine nor in extra-uterine pregnancy have the earliest relations between the ovum and decidua been demonstrated.

Published descriptions have been either largely speculative or based upon the conditions found in lower animals, especially in the rabbit, ape, bat, &c.

Though in the large amount of material which I have examined there are wanting some of the very earliest stages, it seems to me that the remnants of these stages found in specimens of four weeks and upwards throw some light upon the

<sup>1</sup> "Ueber Extrauterinschwang," *Deutsche med. Wchnschr.*, Leipzig, 1890, p. 24.

early relations of the ovum to the decidua, and the nature of their attachment to one another. I have also carefully studied early uterine abortions of the third and fourth weeks, and find that they correspond exactly to the tubal specimens in regard to the relationship of epiblast and decidua. These points cannot be definitely settled until the uterus with the ovum *in situ* has been examined in the early days.

All that can be done at present is to indicate their probable nature from a study of the facts as yet at our disposal.

The writer, conscious of the difficulties in the points at issue, desires to advance the following suggestions as to the early relationship of the epiblast and decidua, not as definitely proven, but only as highly probable:—

In all my early specimens (*viz.*, three and four weeks' uterine, four, five, six, and eight weeks' ectopic pregnancies) the surface of the decidua, both serotina and reflexa, is more or less uniformly covered with a nucleated layer of protoplasm in which only occasionally can cell outlines be recognised. The layer might in fact almost be termed *plasmoidal*. This protoplasm stains very deeply with eosine, the nuclei, which are large and oval or rounded, staining darkly with hæmatoxylin. In great part the layer shows on section only a single row of nuclei, as if composed of a single layer of fused cells; in many places it is two or three times as thick, several rows of nuclei being seen on section. Here and there large nucleated masses, rounded, ovoid, or irregular, are seen either broken off from the general layer or forming part of it, and partly embedded in the decidua. Sometimes detached masses are found entirely embedded in the decidua, and having no apparent connection with the surface layer; these are probably sections across portions of the general layer which have extended into the decidua obliquely.



From the surface are found projecting inwards stalks of this material of various shapes and sizes, some of which we shall afterwards see are in direct continuity with a similar protoplasmic structure covering the early villi.

Still more striking are vacuolated *plasmodial* masses,<sup>1</sup> causing a reticulated appearance, found in some places continuous with the layer covering the decidua, in others, lying free near the surface; the interstices of this network vary in size and often contain blood; the trabeculæ *resemble exactly* the surface layer, being only, as a rule, thicker and showing more numerous nuclei.

Among the villi of the early placenta (two, three, and four months), similar bits of this reticulated protoplasm of various sizes may be often found, as well as broken off trabeculæ and large multinucleated plasmodial masses similar to those lying on the decidua, and of different shapes and sizes.

When I describe the nature of the epithelium of the early chorion, it will be found that it is in its superficial portion of the same nature as this structure, having the same appearance and staining reactions. That they are identical is clear, and this is established beyond doubt by the many evidences of their direct continuity. In uterine placentation, Kastschenko<sup>2</sup> has already called attention to the plasmodial nature of the outer epiblastic layer covering the early villi.

Minot<sup>3</sup> has also referred to the embryonic remains found covering the villi, especially in the early human placenta, and Ed. van Beneden<sup>4</sup> has noticed in the young ovum the same

<sup>1</sup> It is extremely interesting to me to find that Koesmann (*Ztschr. f. Geburtsh. u. Gynäk.*, Stuttgart, bd. xxvii., chap. i.) has described in an early uterine and an early ectopic pregnancy precisely similar appearances. Only, he makes the error of regarding the plasmodium or syncytium as derived from the uterine epithelium.

<sup>2</sup> "Das menschliche Chorionepithel, &c." *Arch. f. Anat. u. Entwicklungsgesch.*, Leipzig, 1885.

<sup>3</sup> "Uterus and Embryo," *Journ. Morphol.*, Boston, April 1889.

<sup>4</sup> *Compt. rend. Soc. de biol.*, Paris, ser. viii., tome v., p. 731.

appearances in the outer portion of the epiblast. How are these appearances to be explained?

It is well to consider for a moment the early stages of the hedgehog's development. Hubrecht has shown that here the epiblastic layer of the blastocyst increases rapidly, forming a protoplasmic coat of several thicknesses of cells, a plasmodia-like mass, in fact. This becomes applied to the decidua, and then rapid vacuolation takes place in it, whereby a reticulated structure is formed connecting the ovum and decidua; the outermost layer of the epiblast, that attached to the decidua, being called by him the *trophoblast*.

So, too, it is probable that in the human ovum—whether from the whole blastocyst or parts of it is not certain, although from the early ova described, possibly only part may undergo the change—the outer epiblastic layer, on entering into relationship with the decidua, gets to consist of a thick nucleated protoplasmic mass which attaches itself to the decidua, to the serotina, and also to the reflexa, if there be one. As growth goes on *vacuolation* appears in this mass, so that the ovum becomes connected to the decidua by a reticulated nucleated protoplasmic structure. The cause of the *vacuolation* is *not evident*; it may be due to its not growing at an equal rate in all its parts along with the rapidly enlarging ovum. The outermost portion, which first came into contact with the decidua, forms a layer, which remains, however far the vacuolation is carried on; it corresponds to the outermost portion of the epiblast in the case of the hedgehog, and like it may be called the *trophoblast layer*, being however a much thinner one.

Whether the plasmodial character of the protoplasm in my sections is the same in its first formed condition, or whether it represents some degree of change, such as is found in the outermost layer of the epithelia, generally, cannot be absolutely

settled, though the probability is that it represents a degenerated condition of the cellular mass.

As to the functions to be associated with the marked epiblastic development, there is room for considerable speculation. The following suggestions may be offered:—

1. There is no doubt that one important purpose which it performs is the firm fixation of the ovum to the decidua.

2. The trabeculæ of the reticulum may serve, as has been suggested by Hubrecht, as pathfinders for the future permanent villi.

3. It serves, probably, for the absorption of nutriment from the decidua. It must be remembered that the yolk supply in the human ovum is exceedingly small, and that it requires to be supplemented at an early period for the supply of the rapidly growing blastocyst. In all probability this nutriment is mainly derived by absorption through the trophoblast of the serous fluid of the swollen succulent decidua, as well as from any of this fluid which has transuded through the upper layers of the decidua into the lumen of the tube. It is possible, also, that there is actual absorption of the solids of the decidua by the trophoblastic tissue, but there is no evidence that this occurs to any marked extent. That the trophoblast possesses phagocytic properties has been now well established, not only in the case of the hedgehog, but in other of the insectivora, in several of the carnivora, the rodentia, and the primates, as has been shown by Hubrecht,<sup>1</sup> Ed. van Beneden,<sup>2</sup> Heinricius,<sup>3</sup> Duval,<sup>4</sup> Hart and Gulland,<sup>5</sup> and others, though in these animals the function appears to vary considerably, both as regards the degree of its development and the extent to which it is employed.

<sup>1</sup> *Op. cit.*

<sup>2</sup> *Op. cit.*

<sup>3</sup> *Arch. f. Mikr. Anat.*, Bonn, bd. xxxiii.

<sup>4</sup> "Le placenta des Rongeurs," Paris, 1893.

<sup>5</sup> *Op. cit.*

In the case of man it is extremely probable that this action is not exercised mainly for the nutritive requirements of the early blastocyst, but is of chief importance in relation to the following requirements, viz. :—

(a.) The embedding of the early foetal epiblast in parts, so as to produce a firm union between it and the decidua. This is seen also at a later stage in the fixation of the permanent villi.

(b.) The establishment of a communication between the maternal blood sinuses and the lacunæ of the early epiblastic reticulum connecting the blastocyst and decidua.<sup>1</sup>

It may be that, phylogenetically considered, these functions in the case of the human ovum bear a different relation to the other functions of the trophoblast from what is found in the lower mammals. In some of these an important purpose of the phagocytic action may be the destruction of the epithelium lining the uterus; in providing nutriment it is said also to play a considerable part. As regards these latter functions in tubal gestation, I have already shown that the degeneration and partial disappearance of the mucosa epithelium takes place along with decidual formation—not prior to it by the action of foetal epiblast. The remains of these cells may, of course, be removed by the phagocytic action of the trophoblast.

The absorption of nutriment from the decidua through the epiblast is merely a temporary stage, preliminary to absorption from the maternal blood direct, though at what early period the change takes place cannot yet be decided.

In the hedgehog, Hubrecht has shown that the blood spaces in the decidua gradually communicate with the lacunæ in the trophoblast, before mesodermic tissue has extended outwards

<sup>1</sup> Kossmann is also of the opinion, based upon his study of the specimens to which I have referred (*vide* p. 135), that the vacuolation of the early plasmodial connection between ovum and decidua is the method of origin of the intervillous space, maternal blood early finding its way into the vacuoles.

into the epiblastic strands. The same thing has been shown by Ed. van Beneden<sup>1</sup> as taking place in the bat, *Vespertilio murinus*, and by Duval,<sup>2</sup> Selenka,<sup>3</sup> and Masius,<sup>4</sup> in rodents.

The method by which this communication is brought about has not been, however, satisfactorily explained in the case of any animal. In man it is as yet entirely problematical. One supposition is that the gradually distending maternal sinuses near the surface of the decidua may burst, and thus allow blood to escape into the epiblastic lacunæ. One can scarcely believe that such a haphazard process is the method, because it would probably frequently be attended by such a sudden outpouring of blood that great damage might be done to the ovum. A more gradual process would be best suited to the delicacy of the epiblast reticulum. This seems to be brought about, as my sections indicate by the *phagocytic action of the trophoblast*, the decidual tissue between the surface and the nearest sinuses being eaten through, the blood thereby being allowed to escape slowly into the spaces between the early villi. This process may be clearly studied in various stages in my sections. The trophoblast seems to advance by throwing out processes of different shapes and sizes which absorb the tissue in front of them. After the sinuses are opened these processes may spread along their walls and may even penetrate them, burrowing into the surrounding decidua. Parts of them may also be broken off in the lumen of the vessel, and be carried away by the blood stream. In Plate XVIII., Fig. 1, a vessel is seen in the muscular layer of the tube almost filled by a plasmodial mass.

It is this appearance of foetal epiblast extending from the surface of the decidua down along the sides of the maternal

<sup>1</sup> *Op. cit.*, p. 730.

<sup>2</sup> *Compt. rend. Soc. de biol.*, Paris, 1887, p. 149.

<sup>3</sup> "Keimblätter und Primitivorgane der Maus," 1883.

<sup>4</sup> *Arch. de biol.*, Gand, vol. ix.

sinuses that has so long been misinterpreted, having been described as the outward extension of the sinus endothelium. The study of early sections makes clear the true nature of the process. In the later stages of pregnancy this foetal lining becomes flattened out and more or less disappears, some of it being carried away by the blood and absorbed.

Direct rupture of the maternal sinuses may take place here and there normally, though it cannot be clearly established. One does certainly find in early pregnancy sinuses without any trophoblastic masses lining their walls, but in these there may never have been any downward extension after communication had been opened up, or this might have taken place to a slight extent and the masses then been washed away.

It may be, indeed, that spontaneous rupture is to be considered pathological, and this is strongly supported by the conditions found in the reflexa, where it is so apt to be followed by extensive tearing up of the reflexa, hæmorrhage into the surrounding tube lumen or among the foetal villi causing much damage.

When once the maternal blood is thus established in the lacunæ of the foetal epiblastic reticulum, the structure might be described as the primitive or temporary placenta. Its structure is probably simple, being entirely composed of foetal epiblast bathed in maternal blood, nutriment being absorbed directly from the latter. This, however, is probably only a very short stage on the way to the formation of the permanent placenta, in which the foetal parts consist, not only of epiblast, but of mesoblast containing blood vessels. The epiblastic reticulum in part is broken up, probably because it does not keep pace throughout with the rapidly growing ovum. These broken off masses, as my sections show, become

gradually reduced to smaller portions, which are, by degrees, disintegrated and absorbed. Some bits of considerable size lose their nuclei and appear to degenerate, having a somewhat hyaline staining reaction.

Part of the reticulum however remains, the trabeculæ serving as pathfinders for the foetal (chorionic) mesoblast, which penetrates them as a delicate structure of branching cells, and thus forms a core in them gradually extending out towards the decidua. Thus are established some of the permanent villous stems which connect foetal and maternal parts in the permanent placenta. Probably only a small number of the full time villi take their origin in this way. The majority develop afterwards from the chorion, but it will be necessary to consider this structure before taking up their formation.

That part of the original epiblast which is left on the surface of the decidua does not appear to follow the increase in area of the latter as pregnancy advances, and so gets broken up. At the end of pregnancy it is found only at irregular intervals, and it differs from its early condition in appearing somewhat shrunken, and with smaller and less brightly stained nuclei.

#### THE CHORION.

It is necessary clearly to understand what is meant when this term is used, since it is one which has been employed in different senses by embryologists. Thus, it used to be applied to the zona pellucida, though now this is generally referred to as the "primitive chorion." It has also been given to the epiblastic covering of the blastodermic vesicle, and more recently to the external amniotic fold or false amnion. According to our knowledge up to the present time, the best definition of the

permanent chorion has been either that used by Schäfer,<sup>1</sup> viz., "that external membrane of the ovum, from which the villi spring," or the one given by Minot,<sup>2</sup> viz., "the whole of that portion of the extra-embryonic somatopleure, which is not concerned in the formation of the amnion."

In view, however, of the probable changes in the early foetal epiblast, viz., the formation of a trophoblast and protoplasmic reticulum, it would be necessary to modify somewhat the latter phraseology, in order not to include these structures in the definition. It would be well to use Minot's definition with the additional words, "and which remains after the disappearance of the temporary epiblastic reticulum which at first connects the ovum with the decidua."

Having first fixed this limitation, we are in a position to take up the description of the chorion at a point where comparisons may be instituted with existing descriptions.

#### *Placental portion of Chorion.*

*Structure.*—The membrane is at first composed of an outer epiblastic layer and an inner mesoblastic layer.

As to the outer layer, it is now evident that it is at first but the remnant left on the somatopleure of the early proliferated epiblast, which afterwards became reticulated and gradually disappeared. I have already referred to the plasmodia-like appearance of these structures, the outlines being indistinguishable. The early chorionic epiblast has in its outer portion the very same appearance.

It consists of several layers. Minot says that the greatest thickness reached by it is only a two-layered stage. In the earliest condition it is very rarely as thin as this, being usually three or four layers in thickness. It varies con-

<sup>1</sup> Quain's "Anatomy," vol. i., pt. i., p. 43.

<sup>2</sup> *Op. cit.*, p. 390.



siderably in different parts. With the advance of pregnancy it probably does not increase in size, save at points in connection with the development of new villi, but gradually thins, though slowly, in the early months. From the surface at intervals are found plasmodial projections differing in size and shape. Some of these appear to be broken off trabeculae of the original reticulum, others are buds of newly forming villi. Everywhere throughout the chorion the cells next the mesoblast are different from the superficial ones just described. They are more or less differentiated from one another, the cell substance taking on a lighter stain than the superficial ones; the nuclei are larger and show a well marked intranuclear network. This layer varies in thickness; it may be a single layer with the cells close together or somewhat separated (Plate XIX., Fig. 3), or it may be thickened in parts (Plate XVIII., Fig. 2).

With the advance of pregnancy, the superficial cells get thinned, their nuclei more or less flattened parallel to the surface, degenerating more or less and often becoming split up. The diminution in the number of the active deep cells is very marked. At full time these cannot be specially recognised in many parts, the whole thickness of the epithelium being a homogeneous nucleated mass, degenerating and splitting into layers.

Below the epithelial layer, after the earliest periods, there can often be traced a layer of cells which appears to form a kind of basement membrane—it is probably of connective tissue origin. It can be more easily traced in some parts than in others.

Regarding the mesoblastic portion of the chorion little need be said. In the earliest specimens, it consists of variously branching cells in a homogeneous matrix.

In sections from the third and fourth months, the cells are

less branched, and they appear gradually to become arranged in great part more or less parallel to the epithelial surface. Their cell substance stains more deeply than the surrounding matrix; they may lie in spaces in the latter, or may be apparently continuous with it. Around the vessels in the mesoblast the tissue appears to be more condensed, the cells often being concentrically arranged. Fibrillation becomes also more marked in the matrix, which becomes of denser consistence as pregnancy advances, these changes commencing usually nearest the epithelial layer. The cells become relatively fewer.

In the early stages the chorion is connected with the amnion by delicate strands of matrix in which an occasional cell may be seen. Later these turn somewhat denser, and at full time may have altogether disappeared in places, the amniotic and chorionic mesoblast having become closely united.

*Formation of the villi.*—I have already described how the earliest of the permanent villi are probably formed—viz., by the extension outwards into the epiblastic trabeculae of the reticulum of chorionic mesoblast. In the very early human ovum described by Coste, it is highly probable that the villus-like projections described by him were really the remains of the epiblast reticulum; some of them had a hollow core, into which the mesoblast was probably just beginning to push its way.

It is possible that the *chorion laeve* represents the early villous condition alone, there being, as a rule, in it but little after new formation such as I am about to describe.

The chief source of the villi is undoubtedly the new chorionic outgrowths after the early stage just referred to. This has been established by many investigations. These probably develop

during a great part of pregnancy, though in diminishing numbers as the later months are reached.

They commence as surface projections of the epiblast, varying in thickness and length, into which the mesoblast makes its way. Sometimes there is no marked epiblastic bud formation, the mesoblast projecting with but a thin covering around it. These outgrowths give off secondary branches, which again may ramify until the characteristic villous form is reached. These vary greatly in their degree of branching, some few remaining, indeed, single. Some of the largest trunks may even reach the decidua, though most of them only become attached through their branches. Very few run at right angles to the surface; most have an oblique direction.

In the early months a section of the placenta shows the villi to be relatively less numerous than at the end of pregnancy, and the numbers of large villi greatly to exceed the small ones; they are also thicker and shorter, and not so near one another. At full time a few large stems are seen, but small villi are by far the most abundant in the placenta, and they are more closely packed together than in the early months.

In structure the villi vary according to their age. In the early stages, on section, they consist of an outer covering of chorionic epiblast, inside which is a core of very embryonic connective tissue, consisting of branching cells and a few oval or round ones, and a delicate homogeneous undifferentiated matrix, into which, very soon, capillary loops make their way from the vessels in the chorionic mesoblast. The epiblast presents much the same appearance as that described in connection with the original chorion. It consists of an outer portion of nucleated protoplasm of the thickness of two, three, or four layers of cells, the cell outlines being indistinguishable, and an inner portion composed of cells like the deep ones already

described in the early chorion; these latter may be very scanty and separated, or may form a continuous layer. Often these appear to lie upon flattened cells, perhaps a kind of basement membrane. Here and there the outer epiblast may be heaped up into thickened masses, or may extend out as long processes. Some of these indicate the place of origin of new branch villi; the long processes are probably remains of broken trabeculae from the primitive reticulum.

At the end of pregnancy similar appearances may be seen in a few villi—*i.e.*, in those which are young and recently formed; in these, however, the connective tissue is more advanced than in the villi just described.

As pregnancy advances the following changes occur:—The epithelial covering thins. About the third month the outer nuclei are often flattened somewhat parallel to the surface. For the most part it gets to consist only of a single layer of deeply stained cubical or flattened cells, whose outlines can usually be distinguished; sometimes two or three layers may be left, thickened irregularly at different spots. Often the outermost layer may, at full time, show degeneration, being fissured parallel or oblique to the surface. In some villi the cells may have so degenerated that only a thin membrane is left, in which no nuclei can be seen; in others even this may be absent, and the connective tissue exposed.

The connective tissue also changes as pregnancy advances. It gets denser and more fibrillated, the corpuscles being smaller and, usually, being more oval or spindle shaped, branching being rarely made out. In the larger stems it may become somewhat fibrous, consolidation being especially marked around the vessels.

*Mode of attachment of the villi to the serotina.*—Some of the earliest villi, consisting only of epiblast, have of course become

attached to the decidua before the mesoblast has penetrated them to any extent. It is easy to recognise these in early specimens by the stalk of plasmodial epiblast, which may be short or long, single or multiple, and is attached to the surface of the decidua, where it is continuous with the trophoblastic layer.

As pregnancy advances the stalk becomes gradually altered in appearance, so as to resemble that found in the later formed villi. At full time it is impossible to distinguish these villi; most of those which are outgrowths from the chorion become attached to the decidua in the following manner, which is the same for both villous stems and villi. As they near the decidua, there takes place a marked proliferation of the deep layer of epithelial cells at the end of the villus, varying in extent in different cases. Owing to this change the end of the villus becomes swollen, and the superficial epithelial cells, *i.e.*, the deeply stained plasmodial layer seen in the sections, becomes thinned, stretched, and broken up somewhat, being cast off in pieces of different sizes. The villous end then comes into contact with the trophoblast remains on the decidua, penetrates it, apparently absorbing parts of it, and becomes firmly attached to the decidua proper. Usually the end sinks for a slight distance, probably owing to this absorption.

The bits of superficial epithelium broken off from the villus and unabsorbed portions of the trophoblast layer may be pushed ahead of the villus, and remain unabsorbed for some time. After the villus is well fixed, its superficial layer of epithelium appears to fuse more or less with the trophoblast on the decidua adjacent to the villus, and to become continuous with it.

Occasionally not the end but the side of a villus becomes attached to the decidua, either continuously or only at intervals; in the latter case, between the points of attachment a thin space

may be seen between the villous epithelium and the trophoblast remains on the decidua. There seems to be no reaction in the decidua, as the result of the fixation of the villi; the attachment takes place, also, equally well whether there are few or many decidual cells. In a few instances, where the trophospongia cells, proliferated endothelium from maternal sinuses, have worked their way to the surface of the decidua, the villi may become directly attached to them.

They become fixed indiscriminately to elevations or depressions in the decidua. Sometimes they may get to lie in pits between the remains of the original mucous fringes, and becoming attached to their sides may appear to be deeply embedded in decidual tissue. Apart from this appearance it is extremely rare that a villus is seen burrowing for any distance into the serotina. In the embedded villi, as pregnancy advances, the covering epithelium becomes early degenerated or absorbed, and largely disappears, so that the line of distinction between them and the surrounding decidual tissue becomes less clearly marked. Occasionally the end of one may dip into the opening of a maternal sinus, and may become attached to its wall, though this is rarely found.

In some of the villi the capillary loops do not reach their outer ends; this is especially seen in those which are most deeply embedded in the decidua.

Hart and Gulland<sup>1</sup> have recently suggested that the villi perform an important part in thinning the serotina by absorbing the degenerating decidua. While agreeing with them that the epiblastic covering is trophoblastic, and that it can absorb the decidua, I do not think that this is the main factor in the thinning of the decidua. I have already (p. 124) stated that,

<sup>1</sup> *Rep. Lab. Roy. Coll. Phys., Edin., vol. iv., p. 17. Journ. Anat. and Physiol., London, 1893.*

after the decidua reaches its highest state of development in the early months, its growth must be very slow; it is marked by degeneration, and it must be much affected by the pressure of the growing ovum. The proliferation of epiblast at the ends of the villi is, I believe, to be associated mainly with their fixation.

There can be no nutritive stimulus to absorption of decidua after the placental circulation is established, because the blood in the intervillous spaces is the great source of nourishment to the foetus.

It is also to be noted that, as pregnancy advances, the proliferated epiblastic cells become fewer and smaller, and, in some cases, disappear entirely. The villi, also, are least vascular near their ends, the embedded portion rarely containing any of the capillary loops. These facts are not in favour of the idea of *active* absorptive action on the part of the attached ends of the villi.

#### *Non-Placental Portion of Chorion.*

Whether the villi of the *chorion laeve* are entirely formed from the trabeculae of the original epiblast reticulum, or partly also by a few new outgrowths from the permanent chorion, is not quite certain, though, probably, they are chiefly derived from the former source. Though they may be mainly epiblast, some contain mesoblast. They never reach a high development, nor ramify to any extent. Their relations to the decidua are the same as in the case of the early chorion frondosum. Very often they appear only slightly vascularised, or not at all. As the ovum grows they become flattened against the decidua, into which they may be forced for a distance. They cease to grow, their covering epithelium degenerates, and they become more or less continuous with the surrounding decidua. Here and there in early specimens, under the villi may be seen the trophoblast

remains on the surface of the decidua, distinct from the epithelium of the villus, though of the same nature. The chorionic membrane, which presses these villi outwards on the decidua, comes directly into contact with the decidual trophoblast between the villi—to the reflexa, or where this is not developed to the vera alone; or when partly developed both to vera and reflexa.

Its structure is the same as that already described in the case of the frondose portion. Its epithelium blends with the trophoblast, and afterwards with the decidua as pregnancy advances, the epithelial layer gradually degenerating and thinning.

#### *Intervillous Circulation.*

The probable nature of the early establishment of the intervillous circulation I have already described. In its first formed condition, the blood which has come from the maternal sinuses flows in the lacunar spaces of the primitive epiblastic reticulum, and later among the more numerous permanent villi.

As to the nature of the lining of this great blood space, there can be no doubt that it is mainly of foetal epiblast—in the early stages entirely; but in the late stages of pregnancy, when the trophoblastic layer on the decidual surface becomes broken up, the layer may in places be in direct contact with the blood stream.

I have not been able to discover any maternal arteries opening directly into the intervillous space—only the large sinuses in the manner already described.

There is no extension of endothelium from the maternal vessels forming a layer covering the villi. On the other hand, I have shown (p. 139) that the original trophoblast may extend into some of the maternal sinuses and line their walls, a con-



dition which has hitherto been overlooked. It has undoubtedly been recognised, but always described as a maternal layer of endothelium which has extended outwards. The error of this opinion is now clearly established, especially since the part played by the foetal epiblast has been recognised, as a result of the examination of many sections by the most careful staining methods.

I have not noticed a well marked circular sinus, though Zedel claims that it is formed in tubal pregnancy. An appearance somewhat resembling it is often seen.

The intervillous circulation may be studied in Plates IX., XI., XII., XIII., XVII.

I have already referred to the great frequency with which clots are found in the placenta, associated with the occurrence of hæmorrhages from the decidua, especially from the reflexal portion.

#### THE AMNION.

Little need be said regarding this membrane. It resembles exactly the amnion of uterine gestation. With Minot's description I am in entire accord. It consists of epiblast and mesoblast, the former being a single layer (occasionally double) of cells, which are mostly cubical, though in some cases columnar; sometimes they are considerably flattened. These variations depend probably upon differences in cells according to the pressure upon them.

The free surface of the cells may be flat, rounded, or irregular. The nuclei are very distinct and stain deeply.

The mesoblast consists of a layer of more or less undifferentiated tissue containing cells, which lie in spaces, arranged mostly parallel to the surface. The intercellular substance is denser near the epiblast, and fibrillated deeper down.

The connective tissue cells are mainly in the deeper portions, there being left under the epithelium a non-cellular part which varies in thickness—the mesoblastic non-vascular. It is connected with the chorionic mesoblast by delicate fibrils, which get denser as pregnancy advances. In parts they may not be seen in the late months, the amnion and chorion having become firmly united.

## CHAPTER VII.

### SYMPTOMS AND SIGNS.

I SHALL consider these under the following heads:—

- I. Those resulting from the pregnancy *per se*.
- II. Those resulting from complications.

#### SYMPTOMS AND SIGNS RESULTING FROM THE PREGNANCY *PER SE*.

It is of the greatest importance to bear in mind that these may sometimes be practically the same as in cases of uterine gestation. The patient may reach full time without being aware that there is anything unusual in her pregnancy. Such cases are, however, extremely rare. The great majority of cases are characterised in the early months by symptoms which are associated with certain complications that result from the ectopic nature of the gestation, and which are not found in cases of uterine pregnancy. But before these special complications arise, it cannot be too strongly emphasised, there are no subjective symptoms of such marked character as to lead the woman to suspect the peculiar nature of her condition.

It is different with the conditions found by the physician on physical *examination*. There are few cases in which these are not sufficiently marked to enable the physician, *if he has the opportunity of making a thorough examination of the patient*, to establish the ectopic nature of the gestation, or at least decide

that the case is not one of uterine gestation, for it is extremely difficult in certain cases to establish a positive diagnosis of ectopic gestation, especially in the early weeks.

*The Constitutional and Sympathic changes* in the system occur in as great variations as in uterine pregnancy. They may be classified as follows:—

1. Changes in the Skin, *e.g.*, darkening of the complexion, pigmentation of the breasts around the nipples, formation of the linea nigra, though this may sometimes be wanting; darkening of the skin in various parts; *striae gravidarum* in the abdomen; prickings and itchiness in various parts.
2. Changes in the Nervous System, *e.g.*, neuralgia, various psychical disturbances, &c.
3. Changes in the Circulatory and Hæmopoietic Systems, *e.g.*, prominence of the thyroid, tendency to varix, and hæmorrhoids in the external genitals and lower extremities, increased hydræmia of blood, and increased tension in pulse in later months, giddiness, palpitation, &c.
4. Changes in Alimentary and Emunctory Organs, *e.g.*, salivation, indigestion, constipation, morning sickness, frequency of micturition.

*Menstrual history.*—Many variations are found. In a certain number of cases there is a cessation of menstruation throughout the pregnancy. In 54 cases Fränkel<sup>1</sup> found that this was so in 26. Sometimes the menstrual discharge appears regularly for the first few months, and not afterwards. Sometimes it may appear two or three times at first at regular intervals, and afterwards at irregular intervals, or after the first appearance an interval may elapse, followed by a return of the periods in

<sup>1</sup> *Arch. f. Gynaek.*, Berlin, 1878, pp. 79, 80.

the later months. Sometimes at the beginning there may be amenorrhœa for one or more months, and a return in the later months. Sometimes there may be irregular discharges of blood during part or the whole of the pregnancy. The amount of blood lost varies greatly at different times and in different cases. Only a few drops may escape or a considerable quantity. It may last for a few minutes, a few hours, or for one or more days. Hennig<sup>1</sup> mentions two cases where blood was lost continuously for several weeks. The discharge may be nearly pure blood, or it may, as well, contain mucous, serum, or bits of the uterine mucosa.

The source of the blood is the mucous membrane of the uterus. Hennig<sup>2</sup> believes that in some cases it may also come from the tube, *i.e.*, where the lumen of the latter is not closed internal to the gestation sac.

That this is possible cannot be denied, for in tubal gestation blood may, as I have shown (p. 131), be found in the tube lumen in some cases external to the ovum and its coverings; in the two cases mentioned by him, to which I have just referred, he believed that this condition existed.

Accompanying the discharge of blood there are often pains of a colicky nature in the region of the uterus; in many cases there is no discomfort at all, and in others only slight pains.

*Periodic colicky pains.*—These pains may begin very early in the pregnancy, but usually after the second month. They may persist if pregnancy goes to full time, or they may diminish and disappear. In some cases there are no pains throughout the gestation. Sometimes they may not be felt for an interval, and then reappear at a later period. Each attack usually consists of a series of irregular, intermittent pains, felt

<sup>1</sup> *Op. cit.*, p. 123.

<sup>2</sup> *Op. cit.*, p. 123.

in the hypogastrium, and also in the side of the gestation sac.

These pains are caused, according to most authorities, by contractions of the uterus and gestation sac.

There is a considerable difference of opinion as to the part played by each of these. A few have asserted, *e.g.*, Hohl,<sup>1</sup> that no contractions take place in the uterus during these pains, but this statement does not agree with the observations of most authorities. Dezeimeris<sup>2</sup> believes that the pains are caused by the uterus alone. There may be more doubt as to the part the ectopic gestation sac plays in producing the pains.

It might be thought that, owing to the thinness of the wall and the small amount of muscle in it, the amount of contraction could not be very great. As I have shown, however (p. 116), in the early months there is both hypertrophy and hyperplasia of the muscle in the tube wall, and in the later months a relatively much greater increase in the connective tissue elements of the wall, so that one would expect the contractions and the pains to be most marked in the first four or five months of pregnancy. It is found that this supposition, based on anatomical facts, is in agreement with clinical experience. Not infrequently, it is interesting to note, rupture of the tube sac terminates one of these periods of pain. But there is one method by which it can be established that contractions can occur in the tube, *viz.*, by direct observation at the time of abdominal section.

Several observers,<sup>3</sup> *e.g.*, Naegele, Hohl, and others, have noted this. Moreover, cases have been described in which, after early rupture of the tubal sac, the foetus has partly escaped

<sup>1</sup> "Lehrbuch d. Geburtshilfe," Leipzig, 1855.

<sup>2</sup> *Journ. d. conn. méd.-chir.*, Jan. 1837, p. 16.

<sup>3</sup> Charpentier, *op. cit.*, p. 364.

through the rent, and the tube has contracted firmly around it.

The relation of these pains to peritonitis and other conditions I shall consider later on.

It is to be remembered that contractions take place in the uterus during normal pregnancy, sometimes causing pain to the woman. The same thing has been noticed in horn pregnancy.<sup>1</sup>

*Discharge of uterine decidua.*—The formation of a decidua in the uterus will be fully considered when I speak of the other changes in the uterus.

In some of the periodic discharges of blood which have just been alluded to, small shreds of tissue or pieces of considerable size may be found, which, on careful microscopic examination, are found to be the uterine mucosa altered by decidual formation. This occurrence is of the greatest importance, and in any case of suspected ectopic pregnancy the discharge should be carefully examined with a view to the detection of decidual cells. As far as our knowledge goes, such cells are only formed in connection with pregnancy.

Klein<sup>2</sup> has recently attempted to disprove this by referring to a case of endometritis described by Ruge,<sup>3</sup> in which some large cells were found, and to another of Overlach's<sup>4</sup>—a case of phosphorus poisoning. Wyder<sup>5</sup> has carefully studied these cases, and has shown that in neither of them could the influence of past abortion be excluded. In another case of dysmenorrhœa, described by Leopold, Klein claimed that certain large cells found in the discharge were of the decidual type, though

<sup>1</sup> Fränkel "Ueber die Diag. u. Behand. d. Extrauterinschwang. in i. d. ersten Monaten."

<sup>2</sup> *Centralbl. f. Gynäk.*, Leipzig, 1890, p. 444.

<sup>3</sup> *Ztschr. f. Geburtsh. u. Gynäk.*, Stuttgart, 1881, bd. v.

<sup>4</sup> *Arch. f. mikr. Anat.*, Bonn, bd., xxv. <sup>5</sup> *Arch. f. Gynaek.*, Berlin, 1891, p. 452.

Leopold himself did not think so. Wyder showed that they were probably vaginal cells mixed with the uterine discharge. Ayres<sup>1</sup> has recently carefully considered this subject, and is of the opinion which I have given above, viz., that decidual cells are alone due to the influence of pregnancy.

*Changes in the breasts.*—Mammary changes occur in ectopic as well as in normal pregnancy. I have already referred to the development of an areola. While this may sometimes be well marked, it is, as a rule, not so pronounced as in uterine pregnancy.

Mammary secretion also takes place, but in the great majority of cases *only to a slight or moderate extent*, though its first appearance may be as early as in normal pregnancy. The breasts rarely reach the degree of fulness and hardness met with in normal cases. In several recorded descriptions of advanced ectopic pregnancy they are mentioned as being flabby, and as containing only a small amount of secretion. Occasionally only one breast may contain secretion. After the death of the child the breasts tend to get smaller, and the secretion to cease (Hennig).

In regard to cases which go to full time and have a spurious labour, an occurrence which is, as far as is known, accompanied with the death of the child (*vide* p. 172), different statements are made. A statement,<sup>2</sup> made as long ago as 1678, viz., that this spurious labour is followed by increased secretion of milk in the breasts, has since been oftentimes repeated.

The quantity has been described by some<sup>3</sup> as being excessive

<sup>1</sup> *Am. Journ. Obst.*, N. Y., 1892. vol. xxvi., Nr. 3.

<sup>2</sup> Le Boursier du Courdray, "Abrégé de l'art des Accouchements," &c., Paris, 1759, p. 36.

<sup>3</sup> Bell, *Med. and Philos. Comment.* Edin., vol. ii., p. 74. Johnson, *Med. Times and Gaz.*, 1872, p. 655. Macartney, *Dublin Journ. Med. Sc.*, 1835, vol. vii., p. 412. Parry, *op. cit.*, p. 120.



in some cases, and it is said that the secretion may continue for days, weeks, or even years. The amount of credence to be placed on these statements cannot be determined.

After the death of the foetus it is difficult to know why there should be any *marked* secretion of milk, though there is no reason why there should not be a slight amount, owing to the mere presence of the gestation sac and its contents in the abdomen.

It is well known that ovarian and other tumours may be accompanied with slight mammary secretion.

It is also well known that after normal pregnancy there may be a condition of prolonged or abnormal galactorrhœa, lasting for two or three years, and it is possible that the same thing may occur occasionally after ectopic gestation.

*Stirrage.*—Movements of the foetus are felt by the mother just as in uterine pregnancy. The date of commencement is about the same, being usually felt between the fourth and fifth month. Variations occur, just as in normal cases. It has been stated by several authors<sup>1</sup> that the movements are more distinctly felt by the woman than in uterine pregnancy. This is very often true, owing to the greater thinness of the gestation sac in ectopic cases. It must, however, be remembered that in normal pregnancy many variations are found in the degree of intensity with which foetal movements are appreciated. One fact of importance is to be specially noted, viz., *that the movements in ectopic gestation are often felt at first on one side.*

*Abdominal enlargement.*—While in uterine gestations, after the uterus has begun to rise above the brim, there is a fairly constant progressive rate and method of distension of the abdominal walls, there is *no such uniformity in ectopic gestations.*

<sup>1</sup> Parry, *op. cit.*, p. 102.

The further advanced the pregnancy the more will the abdominal swellings in the different ectopic varieties tend to resemble one another; and at full time the eye of the physician will not generally be able to distinguish the condition from that caused by an advanced uterine pregnancy. Occasionally, also, the changes in shape of the abdomen during the last five or six months will correspond closely to those found in normal cases.

In the majority of cases, however, *the enlargement of the abdomen*, especially in the first five or six months, is mainly one-sided. At an early period this peculiarity may be detected. Van Cauwenberghe<sup>1</sup> mentions that an early ectopic gestation has been first noted as a swelling the size of a walnut, egg, or orange, in the groin. In the tubo-peritoneal case described by me<sup>2</sup> the woman noticed a swelling in the iliac region during the third month.

This is an important point to bear in mind. In normal pregnancy no change can be detected by the eye in the abdominal wall until after the fourth month has begun. In tubal gestation, owing to the higher position of the tube, the pregnancy may cause a bulging of the abdominal wall at a period when, in normal cases, it would not do so, from being still below the pelvic brim.

This appearance will be found only in certain ectopic cases. It cannot be expected in tubal gestation, where the tube early falls into the pouch of Douglas; interstitial cases, also, will probably not cause any early lateral swelling, and they may be supposed to cause an abdominal projection at about the same time as in normal pregnancy.

As the one-sided ectopic swelling increases, it has not the regular outline of a normal pregnancy. Instead of the longest

<sup>1</sup> *Op. cit.*, p. 104.

<sup>2</sup> *Op. cit.*, p. 45.

diameter being vertical, it is generally oblique or transverse; sometimes the various diameters of the sac are about equal.

Changes occur in the umbilicus similar to those found in normal cases.

*Fœtal movements.*—Movements of the fœtus in ectopic gestation sacs, which early lie close to the anterior abdominal wall, can be detected by the stethoscope before the mother feels them, and they may be recognised with greater ease than in cases of uterine pregnancy.

After the mid term, the movements may often be recognised with great facility on inspection of the abdomen, and, sometimes, distinct irregularities may be seen, caused by the moulding of the abdomen and gestation sac on the fœtus.

On palpation, the fœtal parts may be made out more readily than in normal cases; and in thin-walled women they may, towards the end of pregnancy, be very distinctly felt.

*Fœtal heart sounds.*—These may be heard with the stethoscope, as in uterine pregnancy. In some cases they may be heard with *great distinctness*, but many variations occur in the ease with which they may be distinguished, depending upon the health of the fœtus, its position, the relation of the sac to the abdominal wall, and the thickness of the latter.

*Maternal souffle.*—A souffle may generally be heard after the first two or three months, though there are numerous variations, both in regard to the time of its commencement and also in regard to its intensity. Sometimes it may be heard very faintly, or not at all; at other times it may be heard very loudly. It is most marked on the side corresponding to the gestation. In many cases it cannot be detected on the opposite side.

*Changes in the vagina.*—Changes occur in the vagina similar to those found in normal pregnancy, varying in degree in different cases. Its walls become softer, more relaxed, and acquire a dusky hue. These characteristics are most marked in the last half of gestation.

*Changes in the uterus.*—It has long been known that, in ectopic pregnancy, the uterus undergoes certain changes, viz., enlargement, and decidual transformation of the mucosa of the body. These were first pointed out by Boehmer.<sup>1</sup> About twenty-one years later, William Hunter<sup>2</sup> corroborated this discovery, and has, as a result, been attributed by many with having first noted it.

The enlargement occurs in all cases of ectopic gestation, but with considerable variations. Thus, in the following full time cases, the following measurements were found:—in Spiegelberg's,<sup>3</sup>  $4\frac{1}{8}$  in.; in Martin's,<sup>4</sup>  $7\frac{1}{2}$  in.; in Fränkel's,<sup>5</sup>  $4\frac{1}{2}$  in.; in Hart's,<sup>6</sup> 4 in. These were all of the subperitoneo-abdominal variety. In a pure tubal pregnancy,<sup>7</sup> at the sixth month, the uterus measured  $5\frac{3}{8}$  in. in length; in another,<sup>8</sup> advanced to full time,  $4\frac{5}{8}$  in.; in the full time tubo-peritoneal case,<sup>9</sup> described by me,  $4\frac{3}{8}$  in.

According to Bandl,<sup>10</sup> Küstner,<sup>11</sup> Hecker,<sup>12</sup> and others, the enlargement is greatest in interstitial pregnancies.

While this is probably true, it must be remembered that, in the other varieties, exceptional length may be found as in

<sup>1</sup> "Observat. Anatom.," 1752.

<sup>2</sup> *Med. Comment.*, London, 1773.

<sup>3</sup> *Arch. f. Gynaek.*, Berlin, bd. i., p. 406.

<sup>4</sup> *Trans. Obst. Soc. London*, vol. vi., p. 57.

<sup>5</sup> *Arch. f. Gynaek.*, Berlin, bd. xvi., pp. 5, 299.

<sup>6</sup> "Sect. Anat. of advanced Extra-uterine Gest.," *Rep. Lab. Roy. Coll. Phys.*, Edin., vol. i., p. 26.

<sup>7</sup> Litzmann, *Arch. f. Gynaek.*, Berlin, bd. xvi., p. 336.

<sup>8</sup> Depaul, *Arch. de toc.*, Paris, tome ii., obs. 9.

<sup>9</sup> "Tubo-Peritoneal Ectopic Gestation," Edin. 1892.

<sup>10</sup> "Cycl. of Obst. and Gyn.," vol. xii., p. 59.

<sup>11</sup> *Op. cit.*, p. 499.

<sup>12</sup> *Op. cit.*

Litzmann's case, quoted above, and in an 8 month tubal case of Fränkel's,<sup>1</sup> where it was over 7 in.) Bandl has stated as a law that the nearer to the uterus the ovum is developed, the greater will be the enlargement. On comparing the measurements from a large number of cases, however, I find it impossible to corroborate this statement, except in regard to interstitial pregnancies, where the average length of the uterus is greater than in other cases.

Fränkel<sup>2</sup> notes that the increase in size is especially marked in the long diameter, less in the transverse, and least in the antero-posterior. At any rate, the uterus *does not change in shape so as to resemble the condition found when the organ is itself pregnant*. It retains more or less the shape found in the non-pregnant state.

As the uterus increases, it becomes softer, but the softness is not that of a pregnant uterus; it is more that of a uterus in the second or third week of the puerperium. The peculiar rounding and indistinctness in outline, which is so characteristic of early uterine pregnancy, is entirely wanting in ectopic cases. Another difference important to note is absence of the thinning of the uterine wall immediately above the cervix, so as to form an easily distinguishable lower segment, which is an important characteristic of normal pregnancy from an early period, and recognised on rectal examination. The cervix softens somewhat, varying considerably in different cases, rarely being found as soft as at the end of normal gestation.

It very often tends to become patulous in its lower part, so that it may even admit a finger. Sometimes it may not become opened at all, or only to a small extent. Often a tenacious plug of mucus is found filling the cervical canal.

<sup>1</sup> *Arch. f. Gynaek.*, Berlin, bd. xiv., chap. ii.

<sup>2</sup> "Ueber die Diag. u. Behand. d. Extrauterinschwang. in d. ersten Monaten."

Shortening of the cervix has been described by some authors,<sup>1</sup> but there is no proof that this occurs. As I have shown elsewhere,<sup>2</sup> this statement is not true in normal pregnancy, in the sense understood by the older authors, who believed that it was gradually taken up into the uterus, and so shortened as pregnancy advanced. Sectional anatomy has shown that the cervix is as big at the end of pregnancy as at the beginning, that it may even be larger, and that the apparent diminution in its length, usually only slight, is mechanically produced as a result of the uterine body with its contents pressing on the softened cervix from above.

In ectopic gestation the cervix is not usually so softened, and the pressure factors are wanting to bring about the mechanical shortening. The frozen sections made by Hart and myself are sufficient evidence in regard to this point. When the uterus is drawn up and displaced, the fornices may be partly or wholly obliterated,<sup>3</sup> thus causing an apparent shortening of the vaginal portion of the cervix.

The decidual changes in the uterus in ectopic pregnancy were first carefully investigated by Ercolani.<sup>4</sup> They have also been studied by Conrad and Langhans,<sup>5</sup> Abel and others. One of the most exhaustive accounts is that of Abel.<sup>6</sup> The changes begin very early in the gestation. An early specimen has been described by the latter author. On opening the uterus, the mucosa is found to be arranged in a series of elevations bounded by furrows, varying in complexity on the

<sup>1</sup> Strahan "Extra-Uterine Pregnancy," Phila., 1889.

<sup>2</sup> "Researches in Female Pelvic Anatomy," Edin., 1892, p. 120.

<sup>3</sup> Barbour, *Edin. Med. Journ.*, Sept. 1882.

<sup>4</sup> "Della struttura anat. d. caduca uterina nei casi di Gravidanza extrauterina," Bologna, 1874.

<sup>5</sup> "Tubenschwangerschaft," &c., *Arch. f. Gynaek.*, Berlin, bd. ix.

<sup>6</sup> *Arch. f. Gynaek.*, Berlin, bd. xxxix, p. 393.

anterior and posterior walls. The elevations vary considerably in size, and the furrows may be deep or shallow.

In specimens from later periods of pregnancy the same changes are found, but there are relatively fewer furrows, and the areas of elevation are larger.<sup>1</sup> It has been suggested by Langhans that these swellings are to be associated with the distribution of the vessels in the mucosa, the increase in size taking place chiefly around vascular trunks. This view has not been corroborated.

On close inspection, the openings of the glands may be seen

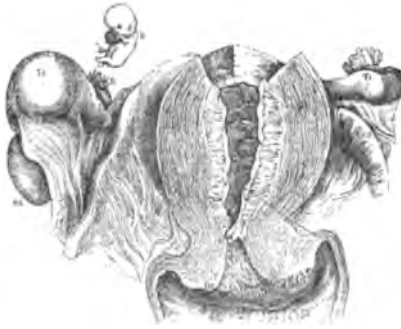


FIG. 14.—Ruptured tubal pregnancy at end of second month. (BANDL.)

*R.* Seat of rupture in right tube.  
*Td.* Site of gestation in right tube.  
*Od.* Right ovary.  
*Mr.* Decidua lining uterus, a quarter of an inch in thickness.

over the surface, mainly in the furrows. They become, to a large extent, obliterated on the elevated areas.

Microscopically, the following conditions are found:—In an early specimen the connective tissue cells show transformation into decidual cells, especially in the uppermost layers of the mucosa. This interglandular increase leads to some compression and obliteration of superficial portions of the glands,

<sup>1</sup> Conrad and Langhans, *op. cit.* Virchow, *Gesammelte Abhand. zur Wissenschaft. Med.*, Frankfurt a/M., 1856.

the earliest indication of the formation of a superficial compact layer (Plate XXII.).

The decidual cells are of various shapes and sizes, being irregular, rounded, oval, or spindle-shaped—mainly the latter, and are arranged in no special order. They do not reach the size found at later periods.

The epithelium on the surface of the mucosa becomes considerably altered, so that instead of remaining columnar, it becomes cubical or somewhat flattened, and is easily detached.

The epithelium in the superficial parts of the glands is somewhat similarly altered, and is, to a large extent, thrown off and found lying in the lumen, where it gradually degenerates. Deeper down, nearer the muscular wall of the uterus, the gland spaces are larger than in the superficial layers, and, being more numerous, owing to the branchings which exist in the uterine glands in their lowest portions, the appearance is produced in the mucosa of a meshwork—the spongy layer of the decidua. The cells lining these spaces have become somewhat cubical, are in some parts swollen, and in other parts detached from the wall and found lying in the lumen.

If at this period the entire decidua be discharged from the uterus, a complete triangular-shaped cast of the cavity of the body is obtained with an opening at each angle representing the *os internum* and the Fallopian tube endings in the uterus.

Vascular changes also occur in the mucosa. Dilatation of the capillaries takes place both in the superficial and deep layers. These vessels run in every direction,—parallel, horizontal, or oblique to the surface. Here and there they lie immediately under the surface. In the deep layers they are more or less tortuous, but in the upper part they do not show



this characteristic. The sinus-like spaces thus formed are lined with a single layer of endothelium. Occasionally, the arteries and veins can be seen to open gradually into these spaces. The former run tortuously from the muscular wall into the mucosa, their walls being gradually thinned. The veins on transverse section are not round like the arteries, but appear as elongated or irregular slits.

Wyder<sup>1</sup> and Charpentier<sup>2</sup> are of the opinion that the most marked and rapid development of uterine decidua is obtained the nearer to the uterus is the seat of the ectopic gestation.

We are not as yet in possession of a sufficient number of facts to state the various changes which may take place in the uterine decidua during the course of gestation. According to the authorities to whom I have referred, the decidual changes in the mucosa are found best marked in the late months. Charpentier<sup>3</sup> suggests that the changes which occur correspond to those which take place in uterine pregnancy; more especially as the decidua is useless in ectopic gestation. These changes are, of course, atrophy, degeneration, and absorption, progressive from an early period of pregnancy.

One fact, however, is thoroughly established, viz., *that the decidua may be expelled from the uterus during the progress of an ectopic gestation.*

Sometimes the complete decidua may be expelled, but generally it is expelled only in bits. This expulsion may occur only once or several times during a pregnancy. In regard to this point careful inquiries have yet to be made. The woman may not see any shreds in the discharges of blood which occur, and the physician rarely has an opportunity of examining them.

<sup>1</sup> "Beiträge z. Lehre von d. Extrauterinschwang.," &c., *Arch. f. Gynaek.*, Berlin, bd. xxviii.

<sup>2</sup> *Op. cit.*, p. 358.

<sup>3</sup> *Op. cit.*, p. 357.

The cases in which decidual shreds have been observed on several occasions are probably those in which the membrane has been detached and expelled piecemeal. I know of no instance in which two complete casts have been obtained during the course of a pregnancy. It would be extremely interesting to know what changes occur in the endometrium after the complete discharge of the decidua, and whether they result in the formation of a normal mucosa or of a decidual mucosa.

Until our knowledge on these points is extended, we cannot settle the question of the constant formation of a uterine decidua in ectopic cases. Küstner<sup>1</sup> and others state that in some cases no decidua is formed. There is no proof of this however. A few cases have been recorded *in which no decidua was noticed, e.g.*, Hecker<sup>2</sup> reports 3 such cases out of 40 tubal pregnancies which he studied. These reported cases prove nothing. Only a small portion of the mucosa may have been examined; the decidua may have been in an early stage of formation and may thus have been overlooked; *it may have been entirely expelled from the uterus before the examination.* Considering all the facts of which we are in possession, there is a strong presumption in favour of the belief that in all ectopic gestations a decidua forms in the uterus, though probably to a varying degree in different cases.

While, then, the recognition of decidual tissue discharged from the uterine cavity, when no ovum exists there, is a positive fact of the greatest value in helping to establish the existence of an ectopic gestation, the absence of this tissue in the uterine discharges from any suspected case does not negative the possibility of pregnancy. Nor, even, if a scraping of the mucosa be examined and no decidual cell be found, can

<sup>1</sup> Küstner, *op. cit.*, p. 499.

<sup>2</sup> *Op. cit.*, p. 542.

any conclusion be reached, until all the possibilities to which I have alluded have been most carefully considered.

*Phenomena occurring at full term.*—When an ectopic gestation reaches full time, the woman passes through what has been termed a “*spurious labour.*” According to Tait<sup>1</sup> this was first described by Vassal in 1652. This is characterised by the occurrence of a series of pains, rhythmic and periodic, resembling those of normal labour. In fact, in cases where there was no suspicion of the ectopic nature of the gestation, both patient and physician have believed that normal labour was in progress, and measures have actually been taken to remove the child by artificial means, under the belief that its progress from the uterus was delayed.

Occasionally a case has been reported in which no pains came on at full time. In other cases, they have come on prematurely during the seventh<sup>2</sup> or eighth month.<sup>3</sup> It has also been reported that they have not appeared until a month or two after full time has been reached; such reports must be received with great caution. It is extremely difficult to calculate the exact age of an ectopic gestation during life, and a mistake of a month or two might easily be made.

Different accounts are given of the duration of the spurious labour. They may last only for a few hours, for one, two, or more days, or, it is said, for weeks.<sup>4</sup> In the majority of cases, after the labour-like pains have passed off there is no return. But several cases are on record where they reappeared at varying intervals. Thus, in one recorded by Hohl,<sup>5</sup> at intervals of four weeks spurious labour pains came on, becoming less

<sup>1</sup> *Op. cit.*, p. 500.

<sup>2</sup> Parry, *op. cit.*, p. 111.

<sup>3</sup> Meadows, *Trans. Obst. Soc. London*, vol. xiv., p. 310.

<sup>4</sup> Parry, *op. cit.*, p. 111; Van Cauwenberghe, *op. cit.*, p. 203.

<sup>5</sup> “*Lehrbuch d. Geburtshülfe*,” Leipzig, 1855.

severe in character until they ceased, and were succeeded by the ordinary menstrual periods. Schmidt<sup>1</sup> described a case in which they occurred eight times in three years, lasting on each occasion for several weeks. In Lospiekler's<sup>2</sup> case they recurred once a year for six years at a time, which corresponded to the date when full term had been reached. Other cases have been recorded in which they have returned at very irregular intervals.

These records require the most careful consideration. It is quite possible that the observers are correct in calling these attacks of pain "spurious labour," but they may only have been severe attacks of dysmenorrhœa, or they may have been caused by peritonitis in connection with the gestation sac.

The pains of the "spurious labour" vary greatly in intensity. They may be very slight throughout; they may become more and more severe; they may be severe from the first or they may vary from pain to pain. They may be felt in the region of the sacrum or in the lower part of the abdomen and pelvis; sometimes, chiefly on one side.

The exact source of the pains is a debated question. Dezeimeris, Küstner, and others, are strongly of the opinion that they are associated entirely with contractions of the uterus. Others, *e.g.*, Velpeau and Marc,<sup>3</sup> think that the contractions occur in the gestation sac. Van Cauwenberghe, Parry, and others, say that both uterus and gestation sac participate in the "spurious labour."

That the uterus contracts at these times cannot be doubted. The dilatation which occurs in the cervix, allowing of the admission into the uterus of one or more fingers and the expulsion of blood or decidual membrane during the labour,

<sup>1</sup> Dezeimeris, *op. cit.*, p. 45.

<sup>2</sup> *Acta Acad. nat. curios.*, vol. iv., p. 92.

<sup>3</sup> "Dict. des sc. méd." Paris, 1817, tome xix., p. 402.

can only result from uterine contraction. This contraction has actually been seen during an abdominal section performed while the spurious labour was in progress.<sup>1</sup> As to the gestation sac, there may be more doubt. I have already pointed out that, in those cases which have gone to full term, the sac wall is thin and consists mainly of fibrous tissue, the muscle being small in amount and irregularly scattered throughout the wall, an appearance which suggests that the latter could not be of much use in bringing about contractions of the sac. Against this supposition, however, there are direct observations of the following nature. Zwank,<sup>2</sup> in an abdominal section for ectopic gestation, having removed the fœtus from the sac, noticed a contraction of its walls whereby the placenta was detached and expelled through the opening. Nægele has observed a similar case. Hohl<sup>3</sup> noticed the sac undergoing variations in consistence, alternately hardening and softening.

Baudelocque<sup>4</sup> observed contractions taking place both in the uterus and in the gestation sac. In interstitial pregnancies there can be no doubt that both contract.

The spurious labour is generally associated with hæmorrhagic discharge from the uterine cavity, though it is wanting occasionally. Sometimes the loss of blood may be very excessive. Often there is as well a discharge of the uterine decidua in small pieces, or, rarely, as a complete cast. In some cases this is absent from the discharge, probably because it has been expelled earlier in the pregnancy.

After the cessation of the labour, the discharges may pass through changes similar to those found after normal labour.

The cause of this spurious labour is not known. It is

<sup>1</sup> Scott, *Trans. Obst. Soc. London*, vol. xiv., p. 370.

<sup>2</sup> Van Cauwenberghe, *op. cit.*, p. 204.

<sup>3</sup> Hohl, *op. cit.*, p. 417.

<sup>4</sup> "L'art des accouchements," tome ii., p. 474.

probably not in the uterus. Some have suggested that the decidua is so degenerated at the end of pregnancy that it acts as a foreign body,<sup>1</sup> and so stimulates the uterus to contraction. But, in regard to this, we do not know about the degeneration in the decidua at full time, and in some cases there is no decidua discharged at full time, it having been expelled previously. Moreover, there is no reason why these uterine contractions should be accompanied by the phenomena of the "spurious labour," seeing that, in so many instances, there may be during pregnancy several periods of uterine action and decidual expulsion, without any change in the well-being of the fœtus. Again, seeing that there is some evidence<sup>2</sup> to the effect that the uterus is sometimes inactive during the "spurious labour," it is reasonable to look elsewhere than to the uterus for the initial cause of the phenomena.

This initial or determining cause is probably the same in ectopic cases as in uterine pregnancy, but is, as yet, entirely unknown.

What, now, are the changes which accompany the "spurious labour"?

As far as is known, it can be said that the fœtus always dies. There have been a few cases reported<sup>3</sup> in which it was reported to have lived for days or months, but these are very doubtful.

According to Küstner<sup>4</sup> death is due to the interference with the placental circulation by the contractions of the sac wall, and by partial separation of the placenta and consequent escape of blood into its substance, tearing it to pieces. Should rupture of the sac occur, it is easy to understand how the child's life may

<sup>1</sup> Hennig, *op. cit.*, p. 131.

<sup>2</sup> Hohl, Baudelocque, van Cauwenberghe, *op. cit.*

<sup>3</sup> Parry, *op. cit.*, p. 121.

<sup>4</sup> *Op. cit.*

be endangered. But experience shows that this accident very rarely occurs in full time cases, because, owing to the large amount of the abdomen occupied by the sac, its walls must be well supported by pressure of the surrounding structures against it, many of which have become adherent to it by peritonitis.

I believe that another factor is of importance in explaining rupture of the sac or partial separation of the placenta, viz., the violent straining efforts often made by the patient during the spurious labour. The strong contractions of the abdominal muscle might cause such changes in the intra-abdominal pressure that these mal-conditions could result.

It has been noted that before the death of the child it often moves very vigorously, sometimes causing the mother great pain.

While rupture of the sac during the labour is a very rare occurrence, it is to be noted that neither separation of the placenta nor hæmorrhage into it may take place in some cases, though the fœtus may die. The cause of this death is, as yet, uncertain, and requires investigation. Possibly the contractions which occur in the sac may alone suffice to interfere with the maternal placental circulation to such an extent as to cause asphyxiation of the child.

Afterwards the abdominal swelling gradually becomes smaller. The *liquor amnii* is no longer secreted, and gets absorbed, the gestation sac shrinking on the fœtus. Later the changes already indicated (p. 92) may take place.

Sometimes the *liquor amnii* may not be absorbed for a long period, causing the size of the swelling to remain stationary for a considerable time. Rarely it may continue to be secreted for a time, leading to an increase in the size of the abdomen.<sup>1</sup>

*Bimanual examination.*—For the thorough investigation of a

<sup>1</sup> Jonathan Hutchinson, *Lancet*, 1873, vol. ii., p. 72.

case of ectopic gestation, especially of a doubtful one, the employment of an anæsthetic is of the greatest advantage, and in many instances is indispensable. It should also be remembered that the abdomino-recto-vaginal is of greater value in the exploration of the pelvis than the ordinary abdomino-vaginal examination.

Many variations in the conditions found in ectopic gestations are obtained on bimanual examination, and herein lies a great difference between them and normal pregnancies in which the physical changes in the abdomen and pelvis occur in pretty uniform manner in different cases.

Relaxation and softening of the vaginal walls may be felt in most cases, though variations are found in the extent to which these signs are marked. They are most developed in the late months. Pulsation of vessels may often be recognised in the walls; sometimes this may be very strongly felt.

In the first two months of pregnancy the position and size of the vagina may not be different from the normal. In some cases, *e.g.*, in some interstitial gestations, it may not be much altered throughout pregnancy. In other cases, few in number, in which the pregnant tube early falls in front of the uterus, and there continues to grow, the vagina may be gradually pushed backwards and downwards against the posterior part of the pelvic wall.

In a larger number of cases, in which the tube grows in the pouch of Douglas, the vagina is pushed forwards and upwards close behind the symphysis.

In other cases where the tube has remained at the side of the uterus, especially where the ovum has burst into the broad ligament and there developed, the vagina tends to be pushed towards the opposite side.

In many cases the lateral displacement may exist along with



one of the other forms. Sometimes the upper part may be slightly twisted, owing to a rotation of the uterus which may take place.

Often the upper part of the passage is diminished by the encroachment of the growing gestation sac outside it. Or the length may be sometimes lessened owing to the uterus being forced downwards by pressure from above.

The position of the uterus is subject to many changes. In the early months it may not be altered. Later, the following conditions are found. It may be retroverted or retroposed, but this displacement is unusual. More commonly it is pushed upwards and forwards behind the symphysis; this is owing to the frequent development of the gestation sac posterior to the uterus. There is, also, generally some lateral displacement either of the whole organ or of the body. The most marked displacements occur where the ovum develops after having burst from the tube into the broad ligament.

Sometimes the uterus may be considerably rotated on its long axis; sometimes it may be forced downwards into the vagina by pressure from above.

When the uterus is felt between the hands it will be found to be enlarged. In the first two or three months this may not easily be distinguished. One fact can be determined, however, viz., that the enlargement is *not of the same shape or size which is found at corresponding periods of normal pregnancy*. Though not so hard as the nulliparous uterus, it has not the characteristic softness of the pregnant uterus. Its fundus does not become rounded as in the latter, and the body when grasped antero-posteriorly between the examining hands feels flattened. *Per rectum* no thinning above the cervix can be found such as occurs in the pregnant uterus. The most commonly recognised change is the elongation of the uterus.

In correspondence with the altered relations of the body, the vaginal portion of the cervix is found in different positions. When the uterus is much elevated, or when the gestation sac presses much against the vagina, the vaginal portion may be difficult of access, or may appear more or less indistinguishable.

The variations in the patulous condition of the cervix have already been alluded to (p. 163).

The relation of the uterus to the gestation sac varies greatly. In interstitial pregnancy throughout, it is felt practically as part of the sac; in the very early weeks the gestation may be felt as a rounded, softened projection of one angle of the uterus; afterwards the pregnant swelling becomes gradually larger than the rest of the organ, which may be felt as a somewhat harder projection on the side opposite the pregnancy. Generally it gets to lie also on the under surface of the sac, but it may sometimes be found on the anterior or posterior surface. It becomes markedly elongated. In some cases it is so incorporated with the gestation sac that it cannot be distinguished as a separate body. In early tubal non-interstitial pregnancies the uterus may often be felt distinct from the gestation sac, and may be made to move independent of it. This is especially the case where the tubal swelling is placed lateral to the uterus, and is not adherent to it. The pregnant tube feels elastic, fluctuating or semi-fluctuating. Its size is usually somewhat less than that of the uterus at the corresponding period of pregnancy, owing to the difference in the thickness of their respective walls. When the tube lies in the pouch of Douglas, or, rarely, in the utero-vesical pouch, the distinction may readily be made out if the gestation sac can be pushed upwards out of the pouches.

When, however, the sacs are wedged in the pouches or adherent to the uterus, so that they cannot be elevated, one

may often feel a distinct grooving between the two swellings, and usually the softer cystic nature of the one and the firmer nature of the other can be made out. Sometimes this grooving is obliterated by adhesions, and cannot be distinguished; in these cases it may be very difficult to determine the outlines of the uterus or the position of the fundus.

In advanced purely tubal cases the uterus may be made out in one or other of the positions above mentioned, but it may be quite indistinguishable from the gestation sac, because it may lie so close to it or be bound to it by adhesions.

In early cases in which the tubal gestation had burst into the broad ligament and continued to develop, the uterus is felt displaced towards the side opposite that in which the ovum is growing. At first, before the broad ligament has become entirely distended, the uterus may be made out to be quite distinct from the gestation sac, though its movements are much restricted. Later on, it may be felt as a mere projection on the wall of the latter, both being fixed in position. In some cases it may be felt at the side of the pelvis.

In the advanced condition of this variety, *i.e.*, when it has become subperitoneo-abdominal, the uterus may be considerably elevated, and, as well as being laterally placed, it may lie on the anterior or posterior aspect of the sac, according to whether the upward growth of the ovum has stripped the peritoneum mainly from the anterior or posterior surface of the uterus. Most commonly the uterus lies to the front, forming part of the gestation sac wall, and it may or may not be easily detected on examination. The irregular outline of the sac may be recognised with the abdominal hand.

In some cases, especially in the subperitoneo-pelvic variety, or in those in which the gravid tube has early fallen into the

pouch of Douglas, ballottement may easily be obtained *per rectum* or *per vaginam*.

Hodge,<sup>1</sup> Thomas,<sup>2</sup> and others, have been able to recognise the fœtus by ballottement during the third month. In most cases, however, it is not apt to be so detected before the fourth or fifth month. The movements of the fœtus may also be felt. Sometimes the fœtal parts can be made out easily in these cases through the vagina or rectum, but sometimes with difficulty. The position of the placenta will explain these differences. When it is placed low, the examining fingers will not readily distinguish the fœtus.

The external hand may generally make out the parts of the fœtus with ease through the abdominal walls, and external ballottement may often be readily obtainable.

#### SYMPTOMS AND SIGNS RESULTING FROM COMPLICATIONS.

*Pressure effects.*—The bladder may be displaced in various directions—viz., upwards, laterally, or sometimes downwards. These are especially marked in the subperitoneo-abdominal variety. In other cases it may not be altered in position to any extent, except when it may become adherent to the growing gestation sac and when the uterus is pushed forwards. In the latter circumstance the bladder is usually compressed behind and partly above the symphysis.

There may thus occur frequency of micturition, difficulty or complete inability to pass water.

It is interesting to note that whereas in the first three months, in uterine gestation, frequency is a common symptom, in ectopic cases, on the other hand, it is of less common occurrence. In normal cases it is caused by the pressure of the

<sup>1</sup> "Principles and Practice of Obstetrics," Phila., 1866.

<sup>2</sup> *New York Med. Journ.*, June, 1875.

growing uterus on the bladder; in ectopic cases, however, owing to the anatomical relations of the tube, there will not be the same pressure on the bladder in a large number of instances. In interstitial pregnancies, however, or in ampullar or infundibular cases where the tube early falls behind or in front of the uterus, micturition troubles may occur in the early months. Usually the most marked micturition disturbances are met with after the early months, especially in cases where development of the ovum continues after rupture of the tube into the broad ligament.

It is important to remember that the kidneys and ureters may be displaced or compressed to such an extent that dilatation and alteration in their structure may occur; these changes are also chiefly marked in the subperitoneo-abdominal variety. There can be very little doubt that these conditions are associated with the albuminuria and eclampsia met with in no small proportion of advanced ectopic cases.

The *rectum* may be pressed upon so as to lead to difficulty in defæcation or to complete obstruction. In some cases an irritative diarrhoea may be set up. When the stomach and intestines are much displaced there may be vomiting, indigestion, &c. though, in some cases, very little digestive trouble may be found. Probably a great deal depends on the amount of peritonitis present, matting the bowels together and affecting their action.

The *circulation* may be sometimes interfered with when the gestation is advanced, so that œdema or varix may be found in the external genitals or lower limbs on one or both sides.

Pressure of the growing ovum on *nerves* in the pelvis and abdomen undoubtedly leads to pains in these regions as well as in the thighs, and may also sometimes lead to muscular weakness in the latter. These symptoms tend to develop after the first few months, and are probably most marked when the

ovum continues to develop after rupture of the tube into the broad ligament. It is impossible, however, to draw any sharp distinction between the pain produced by pressure and that caused by peritonitis on the wall of the gestation sac, so that it is best to consider this symptom in general, without attempting to associate it with its particular causes. Clinically, the distinction can only be made in certain cases.

*Pain in ectopic gestation.*—Apart from the periodic pains of labour-like character which may occur during pregnancy, and those which are met with during the “spurious labour” at full term, the patient may suffer from other pains due to mechanical pressure on nerves in the abdomen and pelvis, or to the peritonitis. I have elsewhere (p. 113) discussed the occurrence of peritonitis in ectopic cases. The symptoms produced by it vary considerably.

Rarely does typical acute peritonitis develop, marked by tympanitic distension and intense pain in the abdomen, quick pulse, elevated temperature, rigors, &c. It sometimes does occur after rupture of the tube into the abdomen, but very rarely. It may be also found, of course, as part of a septic process which leads to abscess formation within the gestation sac. In some cases this process begins in the sac wall, and acute peritonitis may early develop.

In the great run of ectopic gestations, however, the peritonitis is of a chronic nature, leading to changes on the wall of the gestation sac, to adhesions between it and surrounding structures, and to the binding of the latter together.

In some cases the woman may complain of no pain whatever throughout pregnancy. This is somewhat remarkable, but it has been noticed also in cases of tumours in the abdomen. Lawson Tait<sup>1</sup> notes that “it is surprising to what extent a

<sup>1</sup> “Diseases of the Ovaries,” 1883, p. 191.

tumour may be found to be adherent, and yet throughout its history no indications of inflammatory attacks have been given." Olshausen<sup>1</sup> says that, "in the *large* majority of cases, adhesive inflammations which result in parietal adhesions run an apyrexial and latent course, but that in other cases they are attended with pains which may last for days or weeks." The same absence of pain may be noticed as I have shown<sup>2</sup> when, after partial escape of the ovum into the peritoneal cavity, the membranes become adherent to a large area of peritoneum, their attachment being marked by its thickening, which is apparently due to a chronic inflammatory process.

In other cases pains may be felt by the patient varying in their position as well as in intensity.

They may be in the iliac, umbilical, hypogastric, or other regions of the abdomen, and may be dull, sharp, mild, or intense. On abdominal or bimanual examination, increased pain may sometimes be felt by the patient, though in some cases no suffering may be caused.

One more cause of pain must here be mentioned, viz., rupture of a tubal gestation into the broad ligament, or into the peritoneal cavity. In some cases this may be severe, being of a tearing character, the patient feeling that something has given way. The chief symptoms caused by this accident, however, are those associated with the internal hæmorrhage which occurs. In some cases only a small amount of pain is caused. In other cases no pain whatever may be felt on rupture. This happens, probably, when the ovum escapes very gradually as a hernia-like projection through a thinned-out portion of the tube wall. It is also to be remembered that the same gradual escape of the ovum may take place through the fimbriated end, without the occurrence of

<sup>1</sup> "Cycl. of Obst. and Gyn.," vol. viii., p. 88.

<sup>2</sup> *Op. cit.*, p. 44.

marked symptoms, though in some cases this method of escape may be marked with pain and loss of blood.

*Symptoms and signs associated with hæmorrhage in connection with ectopic gestation.*—When hæmorrhage occurs inside the tube, destroying the ovum, and giving rise to a hæmato-salpinx, without any secondary escape into the peritoneal cavity, the symptoms may be so slight as to escape notice. Localised pain may be felt in some cases, but there are usually no marked symptoms due to the pouring out of blood, the amount not being great—in the early months at least.

The hæmato-salpinx may increase by successive hæmorrhages at intervals, and more pain may be felt on these occasions.

When perisalpingitis occurs, as it often does in these cases, pain may be felt in the affected region.

On bimanual examination, after the formation of the hæmato-salpinx, the distended tube is felt, and, if the patient had been examined previous to the blood escape, it is recognised as being less cystic, firmer, and larger. The mass is usually painful, though it may be so only to a slight extent. At later periods, after some consolidation has taken place in the blood clot, the mass gets harder, and, in some cases, gradually sinks in size.

When rupture of the gestation sac occurs, the symptoms vary according to the seat of rupture, its suddenness and the amount of blood lost. First, rupture may occur into the broad ligament only, giving rise to a *hæmatoma*. I have already pointed out (p. 46) that the amount of blood poured out depends, probably, mainly on the amount of placenta torn through. The symptoms of this occurrence vary, accordingly, in intensity. In a well marked case pain is felt in the pelvis, especially on one side; the patient becomes somewhat anæmic, the pulse is quickened, and there may be some degree of shock.



The patient may sometimes feel faint. Retention of urine, difficulty of micturition, and defæcation may follow. The worst cases are those in which much blood escapes and

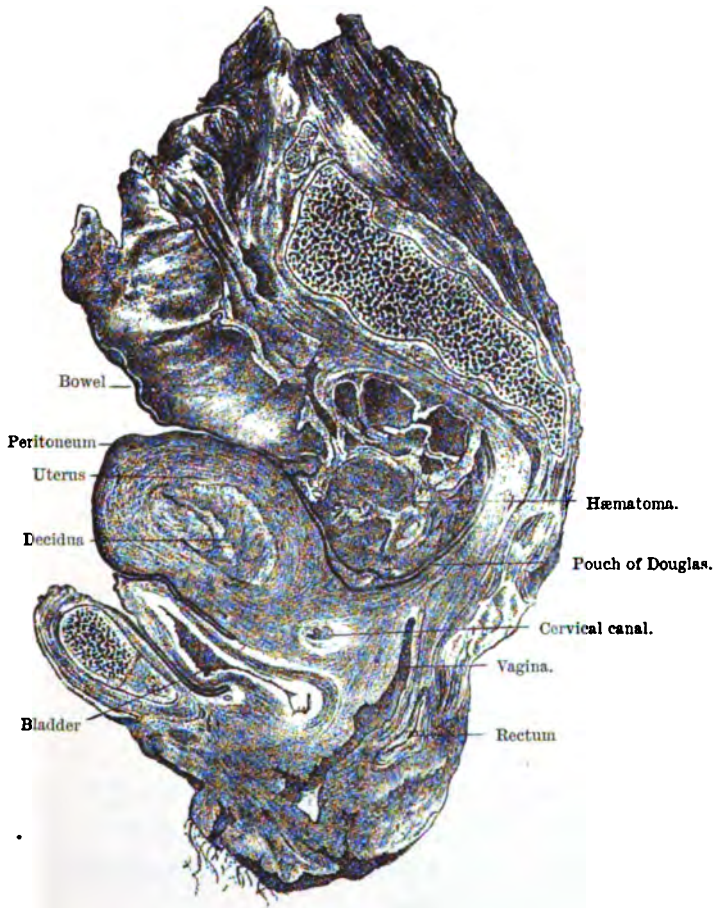


FIG. 15.—Sagittal mesial section of pelvis, with sub-peritoneo-pelvic gestation on right side. The uterine cavity is exposed, showing the decidua. A hæmatoma is seen posterior to the pouch of Douglas. (HARR.)

burrows around the rectum, or out to the side of the pelvis following the psoas iliacus.

On examination, the conditions found vary according to the amount of blood poured out. When in the broad ligament alone, the mass is felt as a tense swelling, obliterating the lateral fornix, it may be, or extending down the side of the vagina for a distance. If the blood has spread outwards, it may be felt in the region of the psoas iliacus or round ligament. The uterus is displaced towards the opposite side of the pelvis. If the blood has spread around the pouch of Douglas, a mass is felt behind the uterus, pressing it forwards along with the upper part of the vagina, the rectum being compressed. The upper surface of the hæmatoma is irregularly convex, the lower more or less concave. Just after its formation the mass feels tense; after consolidation and organisation has begun, it has a firmer elastic feeling, and gradually becomes harder.

When the ovum is not destroyed, but remains intact above the hæmatoma, it may still be felt as a cystic swelling, though probably more tense than before the hæmorrhage took place.

When rupture of the gestation sac takes place into the peritoneal cavity, either by escape of blood through the wall or through the fimbriated end of the tube, giving rise to a hæmatocele, the symptoms vary in different cases, but are in general of a much *more severe type* than in the case of a hæmatoma.

In the majority of cases a large quantity of blood escapes, accompanied with sudden pain, anæmia, faintness, quickened and smaller pulse, collapse, vomiting. Sometimes there are convulsions and delirium.

On palpation of the abdomen, dulness may be made out in its lower regions in extreme cases. On bimanual examination, soon after the loss of blood, the fluid may only be felt as an indefinite fulness, in the midst of which the gestation sac may be made out. If the patient does not die, and consolidation

of the blood takes place, the mass is felt as a solid structure bulging down into the pelvis and reaching up into the abdomen, often higher on one side than on the other, and to a varying height. This mass has a resistant elastic feeling. The uterus may be felt pushed to the front, close behind the symphysis; it may be felt lying retroverted; or it may not be felt between the hands, on account of its being surrounded on all sides by the blood which then bulges down the fornices, the *portio vaginae* being scarcely distinguishable. It is also often felt laterally displaced. The intestines are made out on percussion to be pushed above the blood mass. The bladder and bowel disturbances in these cases may be very marked. Escape of blood from the uterine mucosa into the vagina may sometimes accompany the internal loss of blood.

In a certain number of cases these symptoms may be much less marked, *i.e.*, where the blood escapes but slowly or in small quantities at successive periods. The causes of these variations I have already given (p. 62). Sometimes, indeed, the symptoms may be very slight indeed.

If the patient does not die immediately from the loss of blood, the symptoms and signs which follow vary according to the course taken by the hæmatocele. Its absorption may take place in process of time, the patient suffering mainly from weakness and some bladder and bowel disturbances. Only rarely does acute peritonitis follow, and it is generally septic. Sometimes the patient may suffer from chronic peritonitis. In some cases repeated hæmorrhages may follow, causing death. Suppuration of the hæmatocele may sometimes occur.

*Signs and symptoms associated with suppuration.*—I have already (*vide* p. 47) discussed the conditions under which the various forms of ectopic gestation may undergo septic changes. The result of these changes is the formation of pus,

either intra-peritoneal, extra-peritoneal, or both intra- and extra-peritoneal. The symptoms and signs vary considerably in different cases, though there are certain well-marked characteristics common to all.

Occasionally the septic process is of the nature of *acute septicæmia*, the patient rapidly succumbing after symptoms of rigors, exhaustion, high temperature, quick feeble pulse, and, it may be, delirium and coma.

In the majority of instances the affection is a more chronic one, the pus working its way to the exterior by the bowel, vagina, skin, &c., as has already been described. The discharge varies greatly in different cases, and may be prolonged for years. The main element affecting its continuance is the condition of the fœtus. The older the fœtus, the more difficult the escape of its bones and the longer the condition of pyæmia.

The symptoms in these cases are well known. The patient loses strength and weight, becomes hectic; night sweats and diarrhœa may occur, and the temperature is elevated and irregular. Pain is a very variable feature. It may be severe before the abscess bursts, afterwards disappearing more or less. Later there may be returns, especially marked where large bits of bone are working their way to the outside.

When the bladder is opened into, symptoms of cystitis supervene, causing much discomfort; if a further opening through its base develops, the symptoms of vesico-vaginal fistula are added. Sometimes without the latter condition being produced, calculi may form in the bladder, the nuclei being usually bits of fœtal bones. When the bladder is affected the septic process may spread to the kidney, giving rise to a pyo-nephritis, a most serious condition.

If the gestation sac communicates with some other part as

well as with the bladder, the urine may be partly discharged by the other opening.

When the bowel is opened into, its mucosa becomes irritated and inflamed, and diarrhœa often results, which may sometimes be bloody. Diarrhœa in long standing cases may also be caused by waxy disease. Difficulty in the passage of bones through the rectum may cause pain, a feeling of weight and heat and tenesmus in the region of the anus; sloughing may take place, giving rise to a fistulous opening into the rectum or on the surface.

When the gestation sac opens into the bowel, and communicates at the same time with the surface by skin, vagina, &c., fœces may pass by the latter opening. In the rare cases where the bowel is opened into high up, the digestive process may be greatly interfered with, the partly digested food passing into the abscess cavity and thence to the surface by another opening when one exists. If the stomach be opened into, distressing vomiting occurs.

Sometimes symptoms of strangulation of the gut may develop when it becomes constricted or twisted by peritoneal adhesion to the gestation sac.

In many cases where discharge of the contents of the gestation sac is taking place, the odour is extremely fœtid and offensive.

The conditions felt on examination are much the same as in ordinary septic peritonitis and cellulitis. Fluctuation may be obtained, and pain is usually caused on palpation. Before the abscess opens it may be recognised as pointing in the abdominal wall, perineum, buttocks, vagina, &c. After bursting has occurred, the fœtal structures may be seen issuing from the abscess cavity, or the exploring finger may readily detect them.

In some cases where the gestation sac communicates with the bowel, the percussion note over the former, which was at first dull, becomes resonant from the passage of gas into it.

In cases where an abscess has formed around a lithopædion which has remained quiescent for a number of years, there may be no escape to the surface of the foetal parts, or only a very gradual escape, the lithopædion tending to remain in the abscess cavity as a solid hard mass.

*Rupture of the gestation sac at the time of spurious labour.*— Various forms of rupture of the gestation sac at the time of the spurious labour are described. The rarest is rupture into the peritoneal cavity. In Parry's analysis<sup>1</sup> of five hundred cases of ectopic gestation, not a single example occurred. It is doubtful if it has been observed.

In a few cases,<sup>2</sup> under the influence of the pains, the burst has occurred into the vagina and the child expelled.

These have probably been examples of the subperitoneo-abdominal varieties, in which the ovum had grown extra-peritoneally, after having burst from the tube into the broad ligament, and had spread over the tissues of the pelvic floor.

Rupture has occurred into the large intestine where the spurious labour has been premature, the foetus being born through the anus. This has happened at the sixth,<sup>3</sup> seventh,<sup>4</sup> and eighth<sup>5</sup> months of pregnancy. I do not know that it has been witnessed at full term.

Such cases are probably also subperitoneo-abdominal where the gestation sac enters into close relation with the lower part of the large intestine, especially with the rectum.

<sup>1</sup> *Op. cit.*, p. 118.

<sup>2</sup> Emmons, *Bost. Med. and S. Journ.*, July 1833. Hugier, *Lancet*, Nov. 20, 1852.

<sup>3</sup> Giffard "Cases in Midwifry," London, 1794.

<sup>4</sup> Clark, *Phila. M. Museum*, 1806, vol. ii., p. 292.

<sup>5</sup> Adelon, *Arch. de méd.*, 1826, tome xii.

In interstitial pregnancies occasionally the foetus bursts through the septum which shuts it off from the true uterine cavity, afterwards being delivered through the vagina, though generally by artificial means. This happened at full time in the cases of Langier<sup>1</sup> and Fielitz.<sup>2</sup> Braxton Hicks<sup>3</sup> described an instance of rupture during the fifth month of gestation.

*Changes following the death of the foetus.*—The maternal souffle gradually disappears, though at varying periods in different cases; in one instance it was not heard after the fourteenth day. I have already (pp. 158, 169) alluded to the change in the milk secretion, as well as to the labour-like pains which may return from time to time.

Menstruation may return gradually, but may be delayed for a considerable time.

The abdomen diminishes in size, the *liquor amnii* having ceased to be secreted and its partial or complete absorption having followed.

A few cases have been reported in which it has not altered its shape, and a few others in which it actually appears to have become enlarged.

The sac gradually shrinks on the foetus. I have already considered the changes which afterwards may follow, *e.g.*, mummification, suppuration, &c. When no suppuration takes place, the mass may be carried for many years, causing no trouble, or very little, to the woman.

<sup>1</sup> *Arch. gén. de méd.*, Paris, tome xxviii., p. 332.

<sup>2</sup> "Biblioth. d. chir." tome vii., p. 782.

<sup>3</sup> Petch, *Brit. Med. Journ.*, London, Dec. 4, 1886.

## CHAPTER VIII.

### DIAGNOSIS.

ONE striking fact is revealed by a careful study of the previous chapter, viz., that the signs and symptoms of ectopic gestation are met with *in many variations in different cases*. Herein lies the great difficulty of establishing an accurate diagnosis. Several of these signs and symptoms may be met with in other conditions, and there may be in certain cases much perplexity as to which of these conditions is present.

In examining any supposed case, it is necessary to prove that the uterus is not pregnant, that a swelling exists in the abdomen or pelvis, that it is due to ectopic development of an ovum, and not to some other cause.

There can be no doubt that the most valuable factor in the formation of a diagnosis is the *physical examination* of the pelvis and abdomen, especially by the *abdomino-recto-vaginal bimanual*.

If this cannot be carried out with complete satisfaction apart from the use of chloroform, the latter should be employed without hesitation.

Anæsthesia has proved of enormous assistance in the examination of obscure pelvic and abdominal conditions, and nowhere has it been used to greater advantage than in doubtful ectopic gestation cases. The danger of post-anæsthetic rupture of the sac from vomiting has been exaggerated by some authors in a



most unwarranted manner. It is forgotten how much greater is the danger the woman runs if her ectopic gestation remains undiagnosed, or is set down, as has often been done, as "a harmless cyst or tumour," which might possibly require removal after several months.

It cannot be too strongly emphasised that an opinion based upon an uncertain or difficult bimanual may be as wrong as one formed without examination at all.

While, then, the examination of the patient under an anæsthetic helps us to greater precision in diagnosis, it must be admitted that a certain proportion of cases will be found in which, after the most thorough investigation, uncertainty will still exist.

It is necessary, therefore, to mention the various conditions which may be mistaken for ectopic gestation, or for which it may be mistaken, and to describe in some detail the characteristics by which we may differentiate them.

1. *Uterine Pregnancy.*—A uterine pregnancy has been mistaken for an ectopic gestation. In the first month or two this error may be made, when there is alongside the uterus a swelling, *e.g.*, tubal, ovarian, or ligamentous in nature. The lateral swelling is thought to be an ectopic sac, and the increase in size of the uterus is attributed to the influence of the ectopic pregnancy. If the uterus had been previously in a state of chronic metritis, so that it is harder than it otherwise should be, the deception is greater. In such cases, the false opinion may be strengthened by the passage of a sound one or more times into the cavity of the uterus without an abortion occurring. I may, in passing, state that it is not safe to trust to a negative result derived from the passage of the sound. In early pregnancy it is not an uncommon experience that a sound may be passed into the uterine cavity one

or more times without causing abortion. Moreover, if there be some irregularity in the ordinary signs and symptoms, especially if there be one or more discharges of blood from the uterus, such as may take place in normal cases in the early months, or where the uterus is septate or bicornuate, the danger of making an error is greater.

In these cases, the coitus history may be so definite that we can estimate whether the uterus or the ectopic swelling most nearly corresponds to it—we may be able positively to state that the swelling is not a gestation sac—but we must most of all depend upon the careful bimanual examination of the uterus itself. The early pregnant uterus is softer than the empty uterus in an ectopic gestation of corresponding duration. This characteristic varies, however, especially according to the amount of metritis in its walls. The fundus is rounded and more difficult to define accurately; *per rectum* the thinning and softening in the commencing lower uterine segment can be made out.

Rasch<sup>1</sup> and others insist also upon the detection of fluctuation in the uterus owing to the presence of *liquor amnii* as early as the eighth week.

It is also interesting to note<sup>2</sup> that in some cases while uterine pregnancy may actually be present, the other swelling may sometimes be mistaken for an ectopic gestation.

In the late months, also, the error has been made of mistaking uterine for ectopic gestation. Pajot<sup>3</sup> and others have described cases in which this happened. The chief cause of their error appears to have been abnormal thinness of the uterine and abdominal walls, associated with a small amount of

<sup>1</sup> *Brit. Med. Journ.*, London, 1873, vol. ii., p. 261.

<sup>2</sup> Griffith, *Trans. Obst. Soc. London*, vol. xxxiii., p. 140.

<sup>3</sup> *Ann. de gynéc.*, Paris, 1874, tome i., p. 212.

*liquor amnii*, allowing the parts of the foetus to be unusually readily distinguished by the palpating hand. I have also seen the mistake made when a tumour or an over-distended bowel pushed the uterus markedly to one side. It may also occur when there is a fibroid or fibro-cystic tumour in the uterine wall. In these cases the menstrual history will be of aid to us, though, of course, it may be uncertain. But of greater value is the physical examination; the absence of such a uterine enlargement as one would expect to find were the gestation ectopic, and the positive evidence of changes in the organ which only normal pregnancy can cause, are of the very greatest importance.

Ectopic gestation has also been mistaken for uterine pregnancy by several skilled physicians, *e.g.*, Tarnier<sup>1</sup> and Depaul.<sup>2</sup> This error will in most cases be made during the last half of pregnancy, though an interstitial gestation might be mistaken during any month. This mistake is one which anyone is liable to make if only a casual examination of the patient be made, for most physicians in the routine of work do not always think of the possibility of ectopic gestation in every case, and, as Thorburn<sup>3</sup> puts it, granted that pregnancy exists even with a suspicion of its being ectopic, the probabilities are greatly in favour of its turning out to be intra-uterine.

In some cases, however, after the most searching examination an error may be made. It is easy to see how this arises. The gestation sac extending into the abdomen is felt as a cystic mass; the uterus may be so incorporated with the wall, or so displaced, as not to be easily felt, and if it is missed altogether the gestation may be considered as uterine. This

<sup>1</sup> Boinet, *Arch. de tocol.*, Paris, 1874, p. 126.

<sup>2</sup> *Arch. de tocol.*, Paris, 1874, p. 578.

<sup>3</sup> Strahan, *op. cit.*, p. 47.

should rarely happen. In the majority the signs and symptoms are abnormal or irregular, and generally the empty uterus may be distinguished.

In the few cases where doubt exists, but where the suspicion is strongly in favour of the gestation being ectopic, the only means of definitely deciding is to prove that the uterus is or is not pregnant by examination of its cavity. This may be done by exploration with a sound. Then, if it be not pregnant, a scraping of the mucosa can be made in two or three places, and examined microscopically for decidual tissue.

This may be considered by some as a bold and unnecessary step to take. But careful consideration will show that it is not so. It is necessary to consider the risks not only of interference, but of non-interference. The decision in any case is, it must be remembered, between two courses, and the one chosen should be the less hazardous.

If the uterus be found to be the seat of gestation, the passage of the sound, under careful antiseptic precautions, may certainly lead to a premature delivery, but there is a possibility that this may not happen.

But even should the uterus be emptied, who will say that the loss is not more than balanced by the satisfaction gained—that the woman is not the subject of an ectopic gestation?

If, on the other hand, the gestation be ectopic, where is the danger in exploring the uterine cavity?

Should the uterus be roughly handled or forcibly pulled about there is undoubtedly great risk of a rupture of adhesions or of the ectopic sac, but such manipulation is not necessary to the passage of a sound.

When great care is used this risk is removed. It is said that contractions will be set up in the uterus or gestation sac, which may lead to the death of the child or to the rupture of the sac.

That this may be so is possible, but there is no evidence to enable us to speak definitely in regard to this point. Certainly the sound may be passed without these results following, and it is possible, in some cases at least, that their relationship may only have been one of coincidence. *Post* is not necessarily *propter*. If after the sound be used opiates be given to the woman, the risk of contractions being set up will be greatly diminished.

But even if spurious labour were started, so that it might be thought necessary to perform an abdominal section, the patient would be as favourably placed as though she had gone to full time and then had undergone the operation.

It must also be pointed out that vigorous contractions have followed the bimanual examination in cases of ectopic pregnancy, though this occurrence need not be expected, at least when great care be used.

The information to be derived from curetting is very valuable. While the pressure of decidual tissue is quite sufficient, when taken along with the signs and symptoms of ectopic gestation, to establish a diagnosis of pregnancy, I have already shown that the absence of this tissue in any particular scraping does not exclude its diagnosis. Though in all cases of ectopic pregnancy there is at some period decidual change in the uterine mucosa under certain conditions, *e.g.*, after expulsion of the mucosa from the uterus, a scraping may not, of course, show anything conclusive.

2. *Retroversion of the gravid uterus.*—Ectopic gestation has been often mistaken for retroversion or retroflexion of the gravid uterus. This is apt to occur only during the early months, and the physician may be led into error both through symptoms and through physical examination—mostly through an imperfect bimanual. This mistake should be made very rarely;

a chloroform examination should enable a correct diagnosis to be established.

When a retroverted gravid uterus begins to press on surrounding structures the following symptoms develop, viz., difficulty in micturition, retention of urine or frequency of micturition from an over-distended bladder; the second of these is common. Then pains in the pelvis and thighs, constipation and difficulty in moving the bowels may develop. On examination, if the bladder be over-distended, it is felt as a round or oval mass above the pubes; the cervix of the uterus is usually close behind the symphysis, directed forwards or even upwards; the corpus uteri is felt as a soft cystic swelling in the pouch of Douglas, continuous with the cervix.

In ectopic gestation these various symptoms mentioned are found very rarely. They are most apt to occur when the pregnant uterus falls early into the pouch of Douglas and continues to develop there. There may then be the same bladder troubles, though retention is very rare, as well as pelvic pains. On examination a soft cystic mass is felt in the pouch of Douglas, but the uterus is pushed forwards, and can be felt bimanually separate from the cystic mass. The cervix looks downwards, and usually to one or other side, but not forwards or upwards. If the uterus and the gestation sac be bound together by many adhesions, it is more difficult to define the former.

In cases, also, where, after rupture of the tube into the broad ligament, the gestation has continued to develop passing behind the uterus towards the opposite side, the same resemblance to a retroverted uterus may be found. Here the previous history of the gestation would probably help to decide the nature of the condition.

So thoroughly mistaken have some men been that they

have tried to replace the supposed displaced uterus or to empty it.

Similarly, retroversion of the gravid uterus has been mistaken for ectopic gestation. This should be a rare occurrence where careful examination methods are employed.

3. *Ovarian tumours.*—An ovarian tumour may be mistaken for ectopic pregnancy when it is small, when it is large, when its pedicle becomes twisted, or when it ruptures.

With a small ovarian there are not found the signs and symptoms of pregnancy save, perhaps, occasionally colostrum in the breasts, so that in most cases the history should throw much light on the nature of the condition. Physical examination shows that the uterus is not enlarged as it is in ectopic pregnancy (of course, it might be accidentally enlarged from metritis), and, if a scraping of the mucosa be examined, it is found not to have undergone decidual changes.

There may be more difficulty in deciding when the tumour has grown in the pouch of Douglas, displacing the uterus, but careful examination along with the history should establish the diagnosis.

With a large ovarian tumour there may be more difficulty. There may be occasional pains with it, due either to peritonitis or to bowel disturbance, and the menstruation may be sometimes irregular. On careful examination the signs and symptoms of pregnancy are absent, no broad ligament souffle is heard, no foetal heart beats or movements are made out, no ballottement can be obtained. The uterus is not usually enlarged with an ovarian tumour, though it may become considerably increased if it becomes adherent to a growing tumour. The diagnosis of the tumour from a growing ectopic pregnancy should, therefore, be easy.

More difficult is the diagnosis from a gestation which has

gone beyond full time, spurious labour and death of the child having happened. In such a case, if the history can be correctly ascertained, it would show, first, a period of increase in size of the abdominal swelling, accompanied with the signs and symptoms of ectopic pregnancy; there would probably be a short period marked by a spurious labour, the cessation of foetal movements and non-increase in the abdominal swelling; and, finally, a period characterised by the gradual disappearance of the pregnancy symptoms and the slow diminution in the size of the abdominal enlargement. Sometimes the diminution in size in this last period is not present, and there may rarely be an increased secretion of *liquor amnii*. Several authors<sup>1</sup> have described cases in which there was difficulty of diagnosis because of these exceptional conditions.

Now, in the history of an ovarian tumour these periods cannot be made out, and in most cases the diagnosis can be established. When, however, the history of the ectopic gestation is exceptional—*i.e.*, in that the size of the sac increases or remains stationary after full time—there is undoubtedly more trouble in distinguishing the condition from an ovarian tumour.

Here, as Hutchinson has pointed out, by ballottement, putting the patient on her hands and knees if necessary, the physician should ascertain if a foetus be present. In the cases where diminution of the gestation sac has occurred, owing to the absorption of *liquor amnii*, no ballottement can be made out.

In diagnosing between a large ovarian tumour and an ectopic gestation, the physical examination is also of the greatest importance. In the former the presence of small cysts in the wall may be made out, and are very characteristic, the uterus

<sup>1</sup> Jonathan Hutchinson, *Lancet*, 1873, vol. ii.



has not the soft enlargement that it has in ectopic pregnancy, and its mucosa is not changed to decidual tissue. The mobility which is often obtained in an ovarian tumour of not too large a size is rarely found in ectopic gestation after the early months.

Torsion of the pedicle of an ovarian tumour may lead to a condition simulating rupture of an ectopic gestation sac into the broad ligament or peritoneum. After torsion, in a well marked case, there is severe pain in the abdomen and shock; if much hæmorrhage occur in the tumour, there may be as well the symptoms of anæmia.

In such a case the absence of the signs and symptoms of pregnancy are of most importance in removing the suspicion of an ectopic gestation. Physical examination may be very difficult, but it will show that there is no hæmorrhage into the broad ligament, and in most cases none in the peritoneal cavity; only rarely after torsion may rupture of the tumour occur, causing hæmorrhage into the abdomen.

Rupture of an ovarian tumour may be sometimes followed by symptoms which resemble a ruptured ectopic gestation, *e.g.*, abdominal pain, collapse, &c. If the presence of the tumour had been unknown, the diagnosis might be uncertain, but the absence of signs or symptoms of ectopic pregnancy is sufficient to exclude the latter. Moreover, the symptoms following rupture of a tumour are due to shock and peritonitis, and not to hæmorrhage; there is not often much loss of blood.

An ovarian tumour along with uterine pregnancy may be mistaken for ectopic gestation. Careful bimanual examination, however, should reveal the fact that the uterus at least is pregnant; its shape and consistence when pregnant are quite different from the conditions found in it when the gestation is ectopic, as I have already pointed out.

An ovarian tumour, along with a uterus from which an incomplete early abortion has occurred, may sometimes be diagnosed as an ectopic gestation; if the patient has failed to recognise the ovum there will be more doubt as to the nature of the case. Many of the signs and symptoms of pregnancy are present. The uterus is somewhat enlarged, irregular discharges have occurred from it, and scrapings of the mucosa show decidual tissue. The lateral swelling is felt, and if it was not known to exist before, or to have developed as an inflammatory sequela of the abortion, it may be mistaken for an ectopic gestation.

In these cases, even if the uterus be known to have contained an ovum, there may be doubt as to the nature of the lateral swelling, and it must never be forgotten that intra-uterine and ectopic pregnancy may exist at the same time. If the cyst be not of small size, the absence from it of a souffle, foetal movements, heart sounds or ballottement, will help to prove that it is not a gestation swelling.

Sometimes, also, with an ovarian tumour on one side there may be a tubal gestation on the other.

4. *Cysts of the broad ligament or distended Fallopian tubes.*—What has been said about small ovarian cysts may be applied to these.

5. *Fibro-myoma and fibro-cystic tumour of the uterus.*—The ordinary fibroid tumour of the uterus should rarely be mistaken for an ectopic gestation, and the latter should rarely be mistaken for the former. The hardness of the tumour, its slow growth and the absence of the signs and symptoms of pregnancy, should preclude the existence of ectopic gestation. This is especially true of the sub-peritoneal fibroid. An intra-mural soft myoma or a fibro-cystic condition may simulate somewhat an interstitial gestation as regards the shape of the uterus,

and the resemblance may be increased as a result of the discharges of blood from the cavity which may occur. The signs and symptoms of pregnancy are wanting, however, and the diagnosis should be easy in most cases.

When the uterus is much enlarged by fibroids there may be much difficulty in diagnosing the condition from an ectopic gestation which has gone to full time, and in which, after death of the fœtus, absorption of the liquor amnii and diminution in the size of the gestation sac have taken place. The ectopic mass may resemble very closely, on bimanual examination, fibroids in connection with the uterus, but the history of the case should throw much light on its nature. In a certain number of instances, however, it is impossible to be sure of a diagnosis.

I have seen a woman with a fibroid uterus seized with acute pains owing to constipation and localised peritonitis, who was thought to have had an ectopic pregnancy which had ruptured extra-peritoneally. It occurred about the time of the menopause, after a period of amenorrhœa, colostrum being present in the breasts. The nature of the case was made evident after a copious evacuation of the bowels.

6. *Pelvic hæmatocele and hæmatoma.*—In recent years, owing chiefly to the work of Lawson Tait, the formation of pelvic hæmatoma and hæmatocele, apart from the rupture of an ectopic gestation, has come to be regarded as a rare occurrence. While all experience tends to substantiate this teaching, it must not be forgotten that hæmorrhage may result from other causes, apart from operative procedure. The following are generally recognised, viz., profuse menstruation accompanied with regurgitation along the Fallopian tubes, violent exercise during menstruation, rupture of varicose veins in the broad ligament, purpura, scorbutus, hæmophilia. The blood may thus come from uterus, ovary, tubes or ligaments.

In any given case it may be a matter of the greatest difficulty to diagnose the nature of the hæmorrhage.

In many instances the presence of some of the signs and symptoms of ectopic pregnancy, along with a cystic swelling alongside the uterus, may determine the diagnosis of ectopic gestation. Often the cystic swelling may not exist after it has ruptured, and as this generally occurs early in ectopic pregnancy, the young ovum cannot be felt distinctly among the blood, so that a definite opinion may be difficult to formulate. Then there are some cases where immediately after the hæmorrhage the patient is too ill to be thoroughly examined by the bimanual.

The importance of making an accurate diagnosis cannot be too strongly urged, when it is remembered that rupture of an ectopic pregnancy into the peritoneal cavity is generally followed by the patient's death unless abdominal section be performed.

7. *Pelvic inflammatory exudations.*—Collections of serum or pus in the broad ligament or in the pelvic part of the peritoneal cavity have been mistaken for early ectopic gestation, and *vice versa*. When these collections have followed upon an incomplete abortion, the resemblance will be greater owing to the condition of the uterus. The history of the case is an important guide. The temperature changes, perhaps rigors, the pain and the tenderness on examination, point to an inflammatory origin. Moreover, where no abortion has occurred very recently, all signs and symptoms of pregnancy will be wanting in the inflammatory cases.

There are certain cases of suppuration of ectopic gestations, however, which may undoubtedly be regarded merely as a peritonitis or cellulitis which has gone on to abscess formation. Unless the past history be clear or the foetal parts be felt in

the abscess mass, the true nature of these cases cannot be settled until the abscess works its way to the surface or is opened artificially.

8. *Malignant disease in the abdomen or pelvis.*—Malignant disease in the abdomen or pelvis starting from ovaries, omentum, mesentery, liver, &c., may be mistaken for ectopic gestation. In most cases the mistake has arisen when the cancer growth has assumed a shape resembling that of a foetus in its gestation sac. The case has been supposed to be one in which the foetus has gone to full time and has died, the *liquor amnii* having been absorbed and the sac having contracted on the foetus.

In these cases a careful investigation into the history is of great importance. Also examination at successive intervals shows changes in the malignant growth and in the condition of the woman, which would not be found in the case of ectopic pregnancy. Important among these are the development of cachexia and the formation of ascitic fluid in the abdomen.

These cases are the more perplexing when they occur at the time of the menopause, when menstruation may be irregular, and when colostrum may be found in the breasts.

9. *Pregnancy in the rudimentary horn of a malformed uterus.*—For practical purposes this condition need not be diagnosed from a tubal gestation. The treatment is the same in both. Very rarely is it possible to distinguish one from the other by clinical examination. In the early months it might be done by means of a careful bimanual. If the developed horn could be well palpated, its shape and size might be distinctly enough made out to establish the nature of the case. At a later period, after this horn has undergone some enlargement, it would probably be considered as the normal uterus displaced by the ectopic mass.

10. *Pregnancy in a well-formed bicornuate uterus.*—When pregnancy occurs in one half of a bicornuate uterus the condition may simulate an ectopic gestation. The ordinary symptoms of pregnancy are found, but the position and relations of the gestation sac will cause doubt as to its nature. If the bicornuate condition is only partial, the case may exactly resemble an interstitial or a normal pregnancy. If the two horns be quite distinct above the cervix the pregnant horn may be mistaken for an ampullar gestation or for a rudimentary horn gestation.

When in these cases a vaginal or cervical septum exists, the diagnosis of horn gestation may be easily established. If this does not exist, there is much greater difficulty. If the round ligament can be made out it will be found attached to the outer end of the gestation sac. In the well-marked bicornuate uterus the non-gravid horn enlarges somewhat and gets displaced by the gravid horn, being usually pushed downwards and backwards. Where the division is only partial, the furrow at the fundus may sometimes be distinguished even when the gestation is some months advanced.

The menstruation history varies in these cases. Sometimes it occurs from the non-gravid horn at regular intervals, sometimes at irregular intervals, sometimes it is entirely absent.

The importance of forming an exact diagnosis is evident, because one's decision may involve the question of performing an abdominal section or not. It is well known that in the case of pregnancy in a fully developed horn the fœtus may be delivered by the natural passages, if not by the natural powers, certainly by artificial means.

11. *Spurious pregnancy.*—This condition may be mistaken for ectopic gestation, especially at the menopause. There may be a period of amenorrhœa, or of irregular menstruation, along

with, perhaps, pigmentation of the breasts and colostrum in them. On examination the uterus is found empty, and it may be concluded that there is a pregnancy in the tube. If there be present any swelling of the appendages the danger of making a mistake is greater. The use of an anæsthetic in examining the patient will be of the greatest service.

Stevenson reports a case in which the abdomen was opened and the supposed ectopic sac turned out to be a small ovarian cyst.

In conclusion, it should be noted that besides the conditions already mentioned for which rupture of an ectopic gestation has been mistaken, the following have been also reported, viz., intestinal obstruction, perforation of the stomach or intestines, rupture of an aneurism, renal and biliary colic, gangrenous changes in a myoma.

During the last few years, owing to the important light which research has thrown on the subject of ectopic gestation, as well as to the greater thoroughness insisted upon in the examination of cases, much progress has been made in the direction of accuracy of diagnosis, though, as I have already pointed out, a residuum of cases will remain in which absolute certainty of diagnosis cannot be established.

In the first weeks of an ectopic pregnancy the physician rarely gets the chance of forming a diagnosis until some complication, *e.g.*, rupture, has occurred.

Most women during this period either do not know that they are pregnant or believe that the pregnancy is uterine. If the signs and symptoms are not of the classical type, very few women think it worth while to consult a physician, and in the case of a primipara, especially, the irregularities are not a source of anxiety, but are looked upon as the necessary accompaniments of pregnancy.

Even rupture of the gestation sac may occur without special notice being taken of it by the patient, provided that the symptoms be not severe. This is a rare occurrence, however.

When the physician has the opportunity of examining early uncomplicated cases there is often very great difficulty in deciding their nature.

Given a swelling external to the uterine cavity, it is much easier to establish or to negative the supposition that it is an ectopic pregnancy at a time when a foetus, foetal heart, and movements may be looked for. Most writers have, therefore, in discussing the diagnosis of ectopic pregnancy, considered it under two heads, viz. :—

1. Before the foetal heart is heard ;
2. After the foetal heart is heard.



## CHAPTER IX.

### TREATMENT.

FOR a long period the dangerous nature of an ectopic gestation has been recognised, and various methods of treatment have been adopted for the purpose either of checking the growth of the ovum or of removing it from the body. Many of these methods have been discarded, and I do not propose to make more than a short reference to them. Full accounts will be found in the works of Parry and Strahan.

*Destruction of the ovum by influences brought to bear on the mother.*—Various attempts have been made to kill the foetus by weakening the mother through restricting her diet,<sup>1</sup> bleeding,<sup>2</sup> or purging her, giving her iodide of potassium,<sup>3</sup> mercury,<sup>4</sup> &c. Drugs have been administered for the purpose of destroying the foetus, *e.g.*, strychnine.<sup>5</sup> It has even been suggested that the mother should be syphilised,<sup>6</sup> in order that the foetus might be destroyed. These methods have been entirely abandoned.

*Evacuation of the liquor amnii by puncture of the gestation sac.*—According to Baart de la Faille,<sup>6</sup> Baudelocque and Querin first proposed this method, Delisse and Kiner carrying it out

<sup>1</sup> *Neue Ztschr. f. Geburtsh.*, 1840, vol. ix., p. 206.

<sup>2</sup> Cazeaux, "Traité théorique et pratique de l'art des accouchements," Paris 1844.

<sup>3</sup> Keller, "Des grossesses extra-utérines," Paris, 1872.

<sup>4</sup> Moreau, "Des grossesses extra-utérines," Paris, 1853.

<sup>5</sup> Barnes, "Diseases of Women," London, 1870.

<sup>6</sup> *Op. cit.*

in 1818. Kiwisch, however, says that Basedow first recommended it. During this century it has been employed by several physicians either for the purpose here mentioned or for diagnosis, puncture being made either through the vagina or through the abdomen. It may sometimes lead to the death of the child, but this is very uncertain, as the experience of Sir J. Y. Simpson<sup>1</sup> and Fränkel<sup>2</sup> shows. So great are the risks attending its employment that the method has been entirely abandoned. These dangers are internal hæmorrhage, peritonitis, and septicæmia. Jonathan Hutchinson<sup>3</sup> has ably considered this subject.

*Injection of drugs into the gestation sac for the purpose of destroying the fœtus.*—Joulin<sup>4</sup> first proposed this method, which was first employed soon afterwards by Friedreich.<sup>5</sup> It has since been employed on several occasions. The injections employed have been of morphia, and they have been made through the abdominal wall or vagina. A few cases have been described in which death of the fœtus has occurred, followed by absorption of the ectopic mass, but the reports show that this method is uncertain in its effects on the child, while as regards the mother there are risks of peritonitis, hæmorrhage, or septicæmia.

*Compression of the gestation sac.*—It has actually been proposed to compress the sac by means of bags of sand placed on the patient's abdomen, in the hope of destroying the fœtus. This would be a most dangerous proceeding, because of the risk of causing rupture of the sac or separation of the placenta. I have never heard of its actual employment.

<sup>1</sup> *Edin. Med. Journ.*, March, 1864, p. 865.

<sup>2</sup> "Zur Diagnostik und operativen Behandlung der Tubenschwang," *Arch. f. Gynaek.*, Berlin, bd. xiv., p. 197.      <sup>3</sup> *Lancet*, 1873, vol. ii., p. 72.

<sup>4</sup> "Traité complet des accouchements," Paris, 1863, p. 968.

<sup>5</sup> *Virchow's Archiv*, 1864, bd. xxix., p. 312.

<sup>6</sup> Malin, *vide* Keller, *op. cit.*, p. 59.

*Destruction of the ovum by the passage of an electric current through the gestation sac.*—The first to employ this method is generally believed to have been Bachetti,<sup>1</sup> of Pisa, Burci having proposed the idea to him. It has since been carried out in many countries, especially in America. Papers by Thomas,<sup>2</sup> Garrigues,<sup>3</sup> and Brothers,<sup>4</sup> should be consulted for details regarding its use in that country. The following plans have been tried, viz., puncture of the sac by the two needles attached to the wires, passage of the current without puncture, one pole being placed on the abdomen and the other (negative) in the rectum or vagina close to the sac. Both galvanic and faradic electricity have been used.

The value of this method is as yet undecided, but the tendency at the present time is undoubtedly towards its non-employment.

There is a difference of opinion as to the relative values of the two currents; their action cannot be depended on to kill the foetus, and there are serious risks to the mother. The use of electro-puncture must be condemned because of the danger of inflammation, sepsis, or hæmorrhage. The mere passage of the current without puncture may cause inflammation, and may start contractions in the gestation sac, causing rupture of blood vessels or of the sac wall, though Brothers finds that in seventy-eight cases only one death occurred.

Landis<sup>5</sup> has published the following conclusions based upon a series of experiments:—1. If the faradic current be used, the application should be continued for an hour. 2. The application should be repeated several times to ensure death of the

<sup>1</sup> *Gaz. med. ital. feder. tosc.*, 1853, vol. iii., p. 137.

<sup>2</sup> *Trans. Am. Gynec. Soc.*, 1882, 1884.

<sup>3</sup> *Trans. Am. Gynec. Soc.*, 1883.

<sup>4</sup> *Am. Journ. Obst.*, N. Y., 1888, vol. xxi., p. 474; 1894, vol. xxix., p. 56.

<sup>5</sup> *Am. Journ. Med. Sc.*, Phila., Oct. 1885.

fœtus. 3. During at least one application, a very great current should be employed.

These conditions must entail great discomfort to the patient, apart from the risks she runs.

Steavenson,<sup>1</sup> whose experience in the use of electricity is great, says that the galvanic current, *when puncture is used*, can destroy the fœtus, but he doubts whether the faradic current without puncture can kill. He says that the tenacity of life in the fœtus is as great as in lower animals, *e.g.*, tadpoles, and that any current capable of destroying the life of the fœtus is much more likely to destroy the mother's life.

Baldy<sup>2</sup> has written an interesting paper against the electrical treatment, advocating instead the surgical. The opinion of Lawson Tait in favour of the latter is widely known.

*Elytrotomy.*—The operation of opening into the gestation sac through the vagina and removing the fœtus is an old one, but it is impossible to say when it was first performed. Campbell<sup>3</sup> mentions several cases in which it was carried out during the last century, one of them having been described in 1722. Kelly<sup>4</sup> in 1756 advocated the operation. During the early part of the present century, Cazeaux<sup>5</sup> and Velpeau<sup>6</sup> were among those who recommended it. During the last fifty years quite a number of cases have been reported.

The incision through the vaginal roof in this operation has generally been made with a knife. In 1875 Thomas<sup>7</sup> used a galvano-caustic battery for the purpose.

In 1887, at a meeting of the Obstetrical Society of London, an important discussion<sup>8</sup> on the subject took place following

<sup>1</sup> *Brit. Med. Journ.*, 1886, vol. ii., p. 1094.

<sup>2</sup> *Obstetrical Gazette*, June, 1888.      <sup>3</sup> *Op. cit.*, p. 151.

<sup>4</sup> "Med. Obs. Soc. Phys. London," 1797, p. 44.

<sup>5</sup> *Op. cit.*, p. 602.

<sup>6</sup> "Dict. de méd.," Paris, 1863, tome xiv., p. 420.

<sup>7</sup> *New York Med. Journ.*, June, 1875.

<sup>8</sup> *Trans. Obs. Soc. London*, 1887.

the reading of a paper by Herman, who gave the results of his study of thirty-three cases in which an ectopic gestation sac had been opened through the vagina. Among his conclusions were the following:—

1. In early pregnancy, before rupture occurs, the vaginal operation is not to be performed. Only abdominal section is to be employed at this period.

After rupture the hæmorrhage can best be checked by laparotomy. If, however, after the hæmorrhage there is pyrexia, the indications for incision through the vagina are the same as in hæmatocele from any other cause.

2. At or soon after full time, before any suppuration has occurred, delivery of the fœtus by vaginal incision is preferable to the abdominal operation when the fœtus presents by head, feet, or breech, so that it can be extracted without being turned, and when it is certain that the placenta is not situated on the lowest part of the gestation sac wall, there being at the same time no certainty that it is not attached to the anterior abdominal wall.

With these opinions very few are in accord. The chief opponent of them has been Lawson Tait, whose large operative experience has led him to prefer abdominal to vaginal section.

The objection to the employment of the vaginal incision in the circumstances above mentioned by Herman are as follows:—

The placenta might be torn into, giving rise to great hæmorrhage from the maternal sinuses. It is no easy matter

to say, on clinical examination, where exactly the placenta is placed. It is rarely made out. Undoubtedly, in most cases, if the presenting part of the fœtus be very distinctly felt through the vagina, the placenta is not likely to be situated mainly on the lowermost part of the sac. In some cases, however, it is difficult to know whether a thinned-out marginal portion of placenta might not intervene between the fœtus and the vaginal wall.

Even if the placenta be not directly torn through there is danger of great hæmorrhage from tearing of the enlarged vessels which are always found in the paravaginal and parametric tissues, both in uterine<sup>1</sup> and ectopic pregnancies. The extraction of the fœtus might easily cause the tear to extend into that part of the gestation sac wall to which the placenta is attached.

Under these circumstances there is no possibility of successfully and immediately grasping torn vessels and ligaturing them.

Another risk in the vaginal operation is sepsis. There can be no doubt that it is more difficult to avoid this complication after the vaginal operation, even if the sac has been successfully opened, than after the abdominal operation.

One advantage supposed to be peculiar to the vaginal method is that the sac can be evacuated, in advanced cases at any rate, without the peritoneum being opened. While this is true, it is to be remembered that, in cases of tubal gestation which have never ruptured into the broad ligament, the pelvic peritoneum might undoubtedly be opened into, and in tubo-peritoneal cases the sac which contains the fœtus is the peritoneal cavity lined with the membranes.

<sup>1</sup> Barbour and Webster, *Rep. Lab. Roy. Coll. Phys., Edin.*, vol. ii., pl. vii., fig. 2.

But abdominal section can claim the same advantage in a very large number of cases. The majority of cases which reach the late months of pregnancy are the sub-peritoneo-abdominal in which the ovum, growing extra-peritoneally, has pushed the peritoneum upwards as it has increased in size. In these cases, by carefully selecting the line of incision, the peritoneal cavity need never be opened.

Moreover, sometimes, the placenta, if diagnosed as being situated on that part of the sac next the abdominal wall, may be avoided by making the incision lateral to it.

Then another great advantage of the abdominal operation is that the operator is most favourably placed for dealing with the hæmorrhage.

The only cases in which, it seems to me, the vaginal operation may be performed, are those in which suppuration has occurred, the fœtus being macerated and the pus bulging downwards into the vagina.

Having considered these various methods, we may now take up the treatment proper of Ectopic Gestation. It may be discussed under the following heads :—

- I. When the gestation is entirely tubal, no rupture having occurred either into the broad ligament or peritoneal cavity :—
  - a.* Ampullar and Infundibular ;
  - b.* Interstitial.
  
- II. In cases where rupture of a tubal gestation has taken place into the peritoneal cavity :—
  - a.* Accompanied with acute symptoms due to loss of blood and shock ;
  - b.* Where there are no acute symptoms, but where

only a small rupture has occurred, causing but a slight loss or a succession of slight losses of blood ;

c. Where there are no signs whatever of rupture.

III. Where rupture of a tubal pregnancy takes place into the broad ligament :—

a. At time of rupture ;

b. After rupture, a sub-peritoneo-pelvic or abdominal gestation having been established ;

c. When a secondary rupture into the peritoneal cavity takes place.

IV. When a gestation has reached full term.

V. When the patient has passed through a spurious labour, the child having died.

VI. In cases where death of the fœtus has occurred, and where mummification or lithopædion formation, &c., has followed.

VII. In cases where suppuration has taken place in an old or recent ectopic gestation :—

a. Before the pus has worked its way to the exterior.

b. After the pus has opened to the exterior.

VIII. In cases of combined ectopic and intra-uterine gestation :—

a. When the ectopic gestation is of old standing, *e.g.*, a lithopædion ;

b. When the ectopic gestation is actively growing.

IX. In pregnancy in a rudimentary horn.



I. *When the gestation is entirely tubal, no rupture having occurred either into the broad ligament or peritoneal cavity.*

(a.) *Ampullar and Infundibular.*

When the gestation is diagnosed, the patient and her friends should be informed of the seriousness of her condition. She should take great care of herself while her case may be under consideration, avoiding every form of exertion which might, by producing sudden strain, bring about a rupture of the gestation sac.

The only form of treatment to be recommended is abdominal section, which should be carried out under the conditions now so well recognised as essential to success.

In the early months the operation consists in removing the entire tube by the ordinary method. The broad ligament is ligatured below the tube, either by the Staffordshire knot or by interlacing sutures. The ovary is usually removed along with the tube.

The first case in which a tubal gestation was successfully diagnosed and removed by laparotomy was reported by Veit<sup>1</sup> in 1885.

The operation is, when uncomplicated, a very simple one.

Difficulty may arise from the following causes:—

The tube may be adherent to surrounding parts. Great care must be used in separating the adhesions, which are treated in the ordinary manner, lest rupture of the sac should occur. Some gestation sacs are so matted down by adhesions that they cannot be raised up, so as to allow of the easy passage of ligatures below. In such a case, it is best to ligature the broad ligament and tube internal to the swelling by a series of sutures passed from above downwards. The sac may then

<sup>1</sup> *Ztschr. f. Geburtsh. u. Gynäk.*, Stuttgart, 1885, bd. xi., p. 384.

be cut from its uterine attachments; it can then be raised so that the ligatures can be passed outwards below the sac, through the whole broad ligament, allowing the tube to be cut away. If this procedure is impossible, the case must be treated as a sub-peritoneo-pelvic gestation (*q.v.*, p. 224).

When the tube has fallen behind the uterus and has become fixed in the pouch of Douglas, either because of incarceration or adhesions, there may be considerable difficulty in raising it up. This may not be managed without the withdrawal of the *liquor amnii* from the sac with an aspirator. As a result of the diminution the fingers can more easily get below the sac. The aspiration may lead to hæmorrhage, and the tube wall may tear around the opening made by the needle. This must be controlled by forceps.

In all cases of bleeding from the tube in these operations, the hæmorrhage may be greatly controlled if the ovarian arteries on the affected side be ligatured as they enter the broad ligament, as Olshausen<sup>1</sup> and Sippel<sup>2</sup> have pointed out. If the uterine arteries can also be secured, the control will be greater; this may be effected to a considerable extent if a pair of forceps embrace the broad ligament close to the uterus.

In advanced purely tubal cases the operation is the same in principle as in the early months. Rarely it may be found possible to remove the whole gestation sac after ligature of its pedicle, which is usually well marked. To accomplish this, the *liquor amnii* may require to be aspirated.

In most cases, owing to the adhesions which have formed around the sac, its entire removal is impossible, and the method of procedure is practically the same as in the more common sub-peritoneo-abdominal cases (*q.v.*, p. 225).

<sup>1</sup> "Ueber Extra-uterinschwang," *op. cit.*, p. 40.

<sup>2</sup> *Deutsche med. Wchnschr.*, Leipzig, 1892.

*(b.) Interstitial.*

Several cases have been reported in which, after the diagnosis of this condition, the cervix uteri was dilated, and the septum between the uterine cavity and gestation sac divided, the foetus and placenta being delivered through the opening. The case of Lenox Hodge, described by Parry,<sup>1</sup> is an interesting one.

In these cases, the life of the foetus should be of very secondary consideration, and if it were feared that its extraction *in toto* might tear the opening too much, it should be broken up and extracted in bits.

The chief danger in this operation is the rupture of a part of the wall of the gestation sac which has been greatly thinned. If the placenta has to be removed manually, the greatest care must be exercised in separating it from the wall, if nature fails to do this completely.

After the cavity is emptied, it should be packed with iodoform gauze for three or four days, to stimulate the wall to contraction and to check any tendency to hæmorrhage.

If the position of the uterus or the size of the vagina makes the successful accomplishment of this method of operation very doubtful, abdominal section must be performed. If the gestation were early, it might be possible to remove the ovum and close the cavity very thoroughly in the manner recommended by Martin<sup>2</sup> for the closure of the cavity in the wall of a uterus after enucleation of an interstitial fibroid. During this procedure it would be advantageous to compress the broad ligaments temporarily in order to control the blood supply to the uterus.

When the pregnancy is advanced so that this method is

<sup>1</sup> *Op. cit.*, p. 266.

<sup>2</sup> "Pathologie u. Therapie d. Frauenkrankheiten."

impracticable on account of the size of the gestation sac, removal of the whole uterus by the operation of abdominal hysterectomy is the best for the patient.

II. *In cases where rupture of the tubal gestation has taken place into the peritoneal cavity.*

(a.) *Accompanied with acute symptoms due to loss of blood, shock, &c.*

This occurrence, which takes place in most cases during the earliest months of pregnancy, is such a dangerous complication that only one form of treatment is to be thought of, viz., abdominal section, removal of the ruptured tube, and cleansing of the peritoneum. One of the earliest to suggest this method was Heister,<sup>1</sup> in 1719. Kiwisch<sup>2</sup> in this century recommended the same treatment. Harbert<sup>3</sup> and Rogers<sup>4</sup> of America also urged it. It has only been adopted, however, as a recognised procedure during the last ten years. Lawson Tait's<sup>5</sup> brilliant results have proved beyond dispute its great value, and the testimony of many other operators points in the same direction.

The operation should be performed as soon as possible after rupture. The longer the delay the greater the loss of blood, and the consequent diminution of the chance of the mother's recovery after operation.

Gusserow<sup>6</sup> recommends that, whenever symptoms of intra-peritoneal hæmorrhage occur, even if diagnosis of ectopic pregnancy be doubtful, laparotomy be performed.

<sup>1</sup> Hennig, *op. cit.*, p. 154.

<sup>2</sup> *Ibid.*

<sup>3</sup> *West. Journ. Med. and Surg.*, 1849, vol. iii.

<sup>4</sup> *Trans. Amer. Med. Assoc.*, 1866.

<sup>5</sup> *Brit. Med. Journ.*, London, 1884, vol. i. p. 1250 ; p. 317 ; 1885, vol. i. p. 778 ; *op. cit.*

<sup>6</sup> *Berl. klin. Wehnschr.*, Nr., 22, 1892.

While waiting for the operation, the patient should be kept at rest in a cool room, and bags of ice, or the ice water coil, should be applied to the abdomen.

It is recommended by some that the abdominal aorta should be compressed during this period.

If the gestation sac be small, and mainly pelvic, and the abdomen be not too distended, this may be satisfactorily accomplished, and may considerably check the loss of blood from the torn sac. If, however, in attempting to carry out compression, there is a risk of enlarging the rupture by the manipulations, and, at the same time, of not completely controlling the aortic current, it should be abandoned, because it increases the risk to the patient and may make the operation a more troublesome one.

If the patient be much collapsed, it is well to transfuse blood, or to give an intravenous or subcutaneous injection of saline solution, in order to improve her for the operation. Hypodermic stimulant injections may also be needed, *e.g.*, brandy, ether, nitro-glycerine.

The operation must be performed as rapidly as possible. It is carried out, practically, in the same manner as has been described in the case of the unruptured tube. The first step, after opening the abdomen, is to find the rupture and check bleeding from it by forceps or ligatures, while the removal of the sac is then proceeded with.

If the tear be large or irregular, it may be impossible to do this quickly; or attempts to check the hæmorrhage may make the tear worse, owing to the thinness of the sac. In these circumstances no time should be lost, but the whole tube should be raised up, and the broad ligament compressed by an assistant, while the operator ligatures and removes the gestation sac.

The contents of the sac that have escaped into the peritoneal cavity should then be removed, and the peritoneal toilette carefully attended to, before the abdomen is closed.

If the rupture be in an interstitial pregnancy, the rules to be followed are the same as those I have indicated for the abdominal treatment of unruptured interstitial gestation sacs.

(b.) *Where there are no acute symptoms of shock, or of serious loss of blood, but where only a slight rupture has occurred, causing but a slight loss or a succession of slight losses.*

These are the cases that the physician may not see until days, or even weeks, have passed after the rupture. The treatment is the same as above, viz., abdominal section and removal of the gestation sac. These cases are generally considerably complicated by peritonitis, which has occurred as a sequel to the rupture. There may be a good deal of trouble in cleaning the peritoneal cavity. It will generally be found best to drain for a time after the operation.

(c.) *Where there are no signs whatever of rupture.*

These are the rare cases in which the membranes containing the fœtus escape so gradually into the peritoneal cavity as not to cause any symptoms, or such slight symptoms that the patient does not complain. The membranes become attached to the parietal and visceral peritoneum, and the fœtus continues to develop in this secondary sac, the placenta remaining in the tube—the form of gestation which I have described as “tubo-peritoneal.” Such cases are, usually, only seen by the physician when advanced in pregnancy.

The treatment is as follows:—

The abdomen should be opened by the usual mesial incision. The transverse colon may be found fixed in position behind the abdominal wall, and the omentum may be greatly thickened. It is to be remembered that in this variety the membranes become adherent to the peritoneum by an inflammatory process, and the viscera also become matted together, the small intestines being displaced upwards and to the sides. The cavity containing the foetus is opened into; it is, of course, the peritoneal cavity lined with the membranes—the so-called secondary gestation sac. The membranes may be distinctly seen as a thin layer, or, in some parts, considerably thickened by inflammation. The *liquor amnii* is removed along with the foetus. Adhesions may have formed between the latter and the amnion, and must be divided. The cord is cut close to the foetus, both ends being tied. The placenta is seen to be lying in the pelvis, *enclosed in the tubal or primary gestation sac*; this relation may not be readily made out on account of the thinness of the sac wall and its close investment of the placenta.

If this primary sac is movable, or if the adhesions surrounding it can be easily divided, there can be no doubt that the proper thing to do is to ligature the broad ligament below the whole mass and remove it. If the amnion be easily separable from the secondary sac wall, it might be stripped off cautiously; the chorion cannot be removed, being so incorporated with the peritoneum. In many places the amnion will be inseparable, because of inflammatory thickening, and no effort is to be made to remove it, because of the risk of tearing into the viscera, to which it may be attached.

If the primary sac is too firmly embedded in the pelvis, it will be best not to remove the placenta, because of the impos-

sibility of checking the hæmorrhage at the time. It would, undoubtedly, be advantageous to ligature the ovarian artery on the affected side, in order to diminish the blood supply to the maternal sinuses in relation to the placenta. In this case, the secondary sac should be stuffed with iodoform gauze, the umbilical cord being brought to the lower angle of the abdominal incision.

This method is to be preferred to drainage by means of a tube, because it allows of a gradual restoration of intra-abdominal pressure conditions. If the *liquor amnii* and fœtus be removed, and the cavity be not carefully packed, there will be a greater liability to tearing up of the placenta by extravasation of blood into it, owing to the sudden change in intra-abdominal pressure.

The packing should be done carefully, to be of service in this direction. Another advantage of this method is that it is a valuable means of preventing sepsis.

After four or five days, the patient should again be chloroformed and the placenta entirely removed. This is usually an easy matter at this time, and there may be little or no bleeding. The cavity should again be packed with gauze for a few days, and afterwards a drainage tube can be used, all debris and fluid accumulating in it being withdrawn several times a day.

Should signs of sepsis develop before the fourth or fifth day, it may be necessary to remove the placenta, though, it is to be remembered, the earlier this is done the greater the liability to hæmorrhage. When hæmorrhage does occur, the best treatment is the thorough plugging of the cavity with iodoform gauze for a few days.

On 14th February 1894, an interesting case<sup>1</sup> of tubo-perito-

<sup>1</sup> *Trans. Edin. Obst. Soc.*, vol. xix.



neal gestation was read at the Edinburgh Obstetrical Society, in which the operative treatment was very carefully described by my friend Dr. Moss of Madagascar.

It was carried out as I have described, except that the cavity was drained after the operation by a glass tube. Sepsis developed, and on the fifth day the placenta was removed from the primary sac with the greatest ease. Septic inflammation had started and it was quite foetid.

III. *Where rupture of a tubal pregnancy takes place into the broad ligament.*

(a.) *At time of rupture.*

When rupture of an early tubal pregnancy takes place into the broad ligament, the danger to the patient is not so great as when intra-peritoneal rupture occurs, because of the limited outpouring of blood in the extra-peritoneal tissues. The possibility must also be remembered in every case that the ovum may be destroyed so that it cannot develop further.

The treatment should, therefore, be in the first place that of pelvic hæmatoma or hæmatocele occurring apart from ectopic pregnancy. The patient should be kept at absolute rest, the diet should be non-stimulating; icebags or the ice water coil should be applied to the abdomen, and ergot or hamamelis should be given internally. A careful examination of the pelvis must be made from time to time in order to know if the mass is getting smaller or larger and, if the latter, whether it is due to the continued increase of the ovum.

If the ovum be found to enlarge, so that a sub-peritoneo-pelvic gestation is fairly established, the treatment will be the same as that described in the next section.

(b.) *After rupture has taken place, the extra-peritoneal development of the ovum continuing, giving rise to the sub-peritoneo-pelvic or sub-peritoneo-abdominal variety.*

If the gestation has not advanced beyond the fourth month the place of incision is the usual mesial one. The relations of the gestation sac should be carefully studied, for, if possible, it should be entirely removed after ligatures have been applied below it so as to secure all vessels. In some cases, the sac can only be removed along with the uterus.<sup>1</sup> The abdomen is then cleaned and closed.

If the entire removal is impossible, the sac should be opened and the foetus and *liquor amnii* removed. One of the following methods may now be adopted in disposing of the sac and placenta, after ligature of the ovarian artery on the affected side:—

1. The placenta and membranes may be stripped from the sac and the raw cavity may be closed from below upwards by a long continuous catgut suture. The upper part of the sac may be removed and the edges carefully turned in so that the suture brings their peritoneal surfaces together.

2. The edges of the sac may be stitched to the edges of the lower part of the abdominal incision; the placenta and membranes can then be stripped off and the cavity of the sac firmly plugged with iodoform gauze. The rest of the abdominal wound is then closed. After four or five days, the gauze can be removed and changed. This process is to be repeated until contraction of the sac and the passage leading to it gradually takes place.

3. The first part of this procedure may be carried out, but

<sup>1</sup> "De l'intervention chirurgicale dans la grossesse extra-uterine," &c., Paris, 1894.

the placenta may be left *in situ*. In this case the sac cavity is packed with gauze. On the fourth or fifth day it is removed and the placenta taken away. Afterwards the cavity is packed from time to time until it closes.

It is impossible to say, at present, which of these methods is the best. In some cases the operator may be free to choose any one of them. But when the sac wall is so thin that it is impossible to stitch it to the abdominal wall, the first method must be adopted. Or, when in opening the sac the placenta is cut into, either the first or the second method should be adopted. If in carrying out either of these methods the loss of blood should be very great, even after ligaturing the ovarian artery before the entire placenta is removed, it may be necessary, to save further hæmorrhage, to pack the sac at once with iodoform gauze, and to stitch its edges to the sides of the abdominal incision. After four or five days, the plug may be carefully taken out, the rest of the placenta removed and a fresh gauze plug stuffed in.

There is still another procedure, viz., to allow the placenta to remain *in situ*, having cut the cord through close to it.

Gradual diminution in size and absorption may take place. This method has certainly succeeded in a good many cases, but the danger of sepsis is so great that the tendency at present is to abolish its employment.

In more advanced gestations of this variety the method of procedure is somewhat different. The great extra-peritoneal extension of the sac must be remembered. The stripping upwards of the peritoneum is most marked usually on the side on which the gestation began.

The choice of the abdominal incision is important. As it is desirable to open into the gestation sac without touching the peritoneal cavity, the incision must be made in the lowermost

region of the abdomen. It should also be made on that side on which the gestation extends highest, to ensure further that the peritoneum will be avoided. If, however, it is possible to make out before the operation that the placenta lies on the anterior wall of the gestation sac, the incision should be so made as to avoid cutting through it.

When nothing can be made out regarding the position of the placenta, the incision should be made in the lower part of the abdomen, and generally on the side where the gestation is most developed.

If in making the incision the peritoneum should be opened above the sac, it should be at once closed off by sutures, and the incision continued in a downward direction so as to come into relation only with the gestation sac.

The latter being opened, the foetus and *liquor amnii* should be removed, the umbilical cord being ligatured close to the foetus. If the placenta has not been injured, how is it to be treated?

As far as experience goes, there can be no doubt that it is best to leave it *in situ*, the cavity of the gestation sac being packed with iodoform gauze. After four or five days this can be removed, the placenta taken away and fresh gauze inserted, without risk of hæmorrhage, though if bleeding should start it may be checked by the fresh packing.

The great danger in these cases after the operation is that septic matter may pass from the bowel, which is in very close relationship with the placenta, and may start putrefactive changes in the latter. The patient should be carefully watched for any indication of this, and on the appearance of signs, the gauze should be taken out and the placenta removed, even before the fourth or fifth day.

In cases where the placenta is cut through by the incision,

it is best, after extraction of the child, to remove it from the sac wall and to plug the cavity quickly with gauze. During this operation it may be necessary to plug before the entire removal is accomplished, owing to the loss of blood. The remainder must be taken away after a few days.

When the foetus has been dead for some time before the operation, the placenta may be removed with ease, and usually without the loss of much blood.

From this description, then, it is evident that in advanced extra-peritoneal cases there is to be no question of removing the gestation sac. Its nature and relations make this impossible.

(c) *When, after rupture of a tubal gestation into the broad ligament, a secondary rupture occurs into the peritoneal cavity.*

If the secondary rupture occurs soon after the primary rupture abdominal section must be performed, and the case treated according to the rules laid down for treatment of a tubal gestation which has ruptured directly into the peritoneal cavity.

If the secondary rupture does not occur until some time after the primary, *i.e.*, after a sub-peritoneal development of the ovum has been in progress, abdominal section must be performed, and the case treated on the lines laid down for sub-peritoneo-pelvic cases. The abdominal cavity must of course be opened. If possible the whole sac should be removed. If this is not possible, the rent in the sac, if near the anterior abdominal wall, may be stitched to the edge of the abdominal incision. If it is too far away it should be thoroughly closed with catgut, the peritoneal cavity cleaned out, and the sac opened from the front and treated as above described.

IV. *When gestation has reached full term.*

If a patient has reached full term, and the physician is called upon to decide as to the treatment, should an immediate operation be performed? If the child be dead, there is no doubt that it should. If the child be living, according to a widely held opinion, the operation should be delayed until spurious labour begins. This time is said to be most favourable both for mother and child.

I can see no reason for following this advice, except that, possibly for the sake of the child, it is better for it to complete its time *in utero*. This is somewhat fanciful; a few days do not count for much as regards the health of the child at full time. But it may be a possible disadvantage in many cases to let the child go on, because of the progressive degenerative changes which are so frequent in the ectopic placenta.

As regards the mother, there can be no advantage in waiting for the spurious labour.

I can only conceive of one good reason for allowing the gestation to go to full time, and to pass through a spurious labour, viz., that the operator wishes the growth of the gestation to end in the death of the child, in order that the operation, carried out shortly afterwards, may be rendered as safe as possible, from the greater ease with which the placenta is dealt with under such circumstances.

The treatment in full time cases is the same as that described for advanced pregnancy cases.

One of the earliest to recommend laparotomy—the extraction of a living child—was Simon,<sup>1</sup> though Heim<sup>2</sup> was probably the first to perform it in 1807.

<sup>1</sup> "Mém. Académie royal de ohirurgie," 1768, tome v.

<sup>2</sup> *Mag. f. d. ges. Heilk.*, Berlin, 1813, bd. iii.

In advanced pregnancy, say in the seventh or eighth month, the question will arise as to the advisability of operating immediately after diagnosis is made, or of allowing the patient to go to full time, in the hope of getting a living child. The advice of the physician should certainly be given in favour of *non-delay*. Waiting will but increase the discomforts and risks to the patient; and as regards the child, there is great uncertainty. Ectopic children are weaker and less robust than those developed *in utero*, and are liable to die at or near full time.

V. *When the patient has passed through a spurious labour, the child having died.*

In these cases abdominal section should be performed in the same manner as already detailed for advanced pregnancy. If the child has been dead for some time, it will be found that the placenta may easily be removed at the time of operation, and with less risk of hæmorrhage, than in cases of pregnancy operated on where the child is living. The reason of this is probably as follows:—When the foetal circulation stops, the placenta, which is almost entirely a foetal structure, becomes practically a foreign body, and, being in close relation to the maternal vessels, which open into the intervillous spaces, leads to coagulation and closure of these vessels.

The same thing takes place when the placenta is left behind in cases where a living child was removed by operation, when, undoubtedly, the process will be aided by the ligature of the ovarian artery at the time of the operation.

The teaching advocated by Parry<sup>1</sup> and others, that these cases should be allowed to go on until some complication occurred, must be strongly opposed.

<sup>1</sup> *Op. cit.*, p. 260.

VI. *In cases where the fetus has died, and where mummification, adipocere formation, or lithopædion formation has occurred.*

It is quite true that cases have been recorded where a woman has carried one of these masses in her abdomen for a lifetime.

There is usually, however, more or less discomfort to the patient. She suffers from gastro-intestinal disturbances, pains in the abdomen, ill-health, &c. Besides, she may have attacks of peritonitis from time to time, and suppuration may occur in connection with the mass. Moreover, it is important to note that this mass may cause trouble should the uterus become pregnant.

Abdominal section should therefore be advised in these cases. The foetal mass should be removed from the sac in which it lies. The latter cannot usually be removed because of its intimate union to surrounding structures.

VII. *In cases where suppuration has taken place in an old or recent ectopic gestation.*

(a.) *Before the pus has worked its way to the exterior.*

The purulent cavity must be evacuated. This must be done by an opening through the vagina or through the abdominal wall. As regards the choice of one of these, there may be a difference of opinion. One desideratum to be aimed at is to avoid opening the peritoneal cavity, *i.e.*, in cases where the suppuration is extra-peritoneal. If in these cases the pus be bulging into the vagina, and the foetus is macerated, so that it can be easily removed, the vaginal operation may be performed. It is followed by antiseptic irrigation and drainage of the cavity.



When the indications do not point so clearly to the vaginal incision, it may be best to open the pus cavity through the anterior abdominal wall. In peritoneal cases, the incision should be made in the lower abdominal region, to ensure that the peritoneum shall not be opened, because of its having been stripped upwards. The foetus, placenta, and pus must be removed, the cavity washed out with an antiseptic lotion, and then drained. The drainage may be well carried out by a packing of iodoform gauze.

(b.) *After the pus has opened to the exterior.*

If the pus has opened through the abdominal wall, the sinus should be enlarged, so that the foetal bones and debris in the sac can be thoroughly removed.<sup>1</sup> The same thing is to be done if an opening has taken place into the vagina.

When the pus has opened into the bladder, or into the vagina through the bladder, the base of the viscus should be incised sufficiently to allow of the removal of the bones. If the condition of the foetus is such as not to allow this to be done without risk of considerably injuring the bladder walls or ureters, then the gestation sac should be opened above the symphysis. This may be done extra-peritoneally, for rupture of a purulent ectopic gestation into the bladder probably only takes place in the sub-peritoneo-pelvic or abdominal variety. In this way the sac contents could be thoroughly removed and the cavity cleansed.

When a rectal communication has established itself, it may be possible to dilate the anus so as to remove the foetal parts and sac contents. If this cannot be done, the case will drag on for a very long time. It would be best to make another opening into the sac either through the vagina or the abdominal

<sup>1</sup> See Kimura's case reported by Whitney, *Univ. Med. Journ.*, Phila., May 1892.

wall, provided the operation could be done extra peritoneally. This could probably easily be accomplished, because of the fact that almost all cases in which a suppurating gestation cavity opens into the rectum, the pregnancy is sub-peritoneo-pelvic or sub-peritoneo-abdominal. In these cases the gestation sac is partly formed, in most cases, by the rectal wall. This subject has been recently considered in an interesting paper by Harrison Cripps.<sup>1</sup>

VIII. *In cases of combined ectopic and intra-uterine gestation.*

(a.) *When the ectopic gestation is of old standing, e.g., a lithopædion.*

The uterine pregnancy may go on, in some cases, to full time, and the child be born normally.

It may end prematurely owing to the interference of the ectopic mass with the growth of the ovum. The child may go to full time, but natural labour may be obstructed by the pressure of the ectopic mass and artificial delivery or embryulcia may be required.

(b.) *When the ectopic gestation is actively growing.*

These are very serious cases. The increased vascularity of the pelvis makes rupture of the ectopic sac a most dangerous complication to be feared. Cases have been described undoubtedly in which full time was reached by the uterine gestation, and delivery accomplished without rupture of the sac. In other cases, abdominal section has been carried out, the ectopic sac opened or removed, and a Porro or Cæsarean

<sup>1</sup> *Brit. Med. Journ.*, 1894, vol. i., p. 291.

section being also performed on the uterus. Franklin,<sup>1</sup> of Leicester, has recently given details of a case of this kind in which both pregnancies had reached full time. The patient died from the great loss of blood following the opening of the ectopic sac, which was apparently *sub-peritoneo-abdominal*.

In some cases it might be possible to remove an early ectopic gestation satisfactorily without interfering with the uterine gestation, and the latter might go on to full time just as it may after the removal of an ovarian tumour during pregnancy.

In these cases, happily rare, undoubtedly no consideration whatever should be given to the life of either foetus, if the mother is to be saved, and the indications for removal of the ectopic mass as early as possible are even stronger than in cases not complicated by uterine pregnancy.

#### IX. *In gestation in a rudimentary horn.*<sup>2</sup>

In rupture of this form of gestation, the danger is so great that abdominal section should be performed as soon as the condition is diagnosed. The rules to be observed in operating are exactly the same as those laid down for tubal gestations.

<sup>1</sup> *Brit. Med. Journ.*, 1894, vol. i., p. 1019.

<sup>2</sup> Cases have been described by Koeberlé (1866), Salin (1880), Werth and Litzmann (1881), Säger (1882), Angus MacDonald (1884) Wiener (1885). The papers of Säger (*Centralt. f. Gynäk.*, Leipzig, 1883), and Wiener (*Arch. f. Gynaek.*, Berlin, bd. xxvi.) may be consulted for details.

# I N D E X.

	PAGE		PAGE
Abdomen, Appearance of, . . .	159	Constitutional and Sympathetic	
„ Auscultation of, . . .	161	Signs and Symptoms of Ectopic	
„ Diminution in Size of,		Pregnancy, . . . . .	154
„ after Full Time, . . .	173	Cornual Pregnancy, . . . . .	85
„ Examination of, . . .	177		
Abdominal Gestation, so-called, 14, 17, 60,		Death of Fœtus at Full Time, . . .	172
„ Section, . . . . .	213	Decidua Reflexa, . . . . .	129
„ Wall, Escape of Fœtus		„ Serotina, . . . . .	123
through, . . . . .	50	„ Vera, . . . . .	117
Abdomino-recto-vaginal Examination, 190		Developmental Changes, . . . . .	113
Absorption of Ovum, . . . . .	66, 74	Diagnosis, . . . . .	190
Adhesions between Fœtus and		„ differential from Broad	
Gestation Sac, . . . . .	34, 112	Ligament	
Adipocere Formation, . . . . .	93	Cysts, . . . . .	200
Age in relation to Ectopic Pregnancy, 105		„ „ distended	
Amenorrhœa, . . . . .	155	Fallopian	
Amnion, . . . . .	151	Tubes, . . . . .	200
Ampullar Tubal Gestation, . . . . .	33	„ „ Fibro-Myo-	
Anæsthesia, importance of, in		matous and	
Examination, . . . . .	190	Fibro-Cystic	
Ballottement, . . . . .	178	Tumours of	
Bimanual Examination, . . . . .	173	Uterus, . . . . .	200
Bladder, Discharge of Ovum		„ „ Malignant	
through, . . . . .	50, 186	Disease in	
„ Displacement of, . . . . .	37, 178	Abdomen	
„ Pregnancy, so-called, . . . . .	18	and Pelvis, . . . . .	203
Breasts, Changes in, . . . . .	158	„ „ Ovarian	
Calcification, . . . . .	94	Tumours, . . . . .	197
Causes of Ectopic Pregnancy, . . . . .	1	„ „ Pelvic Hæ-	
Cervix, Condition of, . . . . .	163	matocele	
Changes in Fœtus after Full Time, 189		and Hæ-	
Child-bearing History in relation to		matoma, . . . . .	201
Ectopic Gestation, . . . . .	106	„ „ Pelvic In-	
Chorion, . . . . .	141	flamma-	
„ Non-Placental Portion of,		tory Exu-	
„ Placental Portion of, . . . . .	142	dations, . . . . .	202
Classification, . . . . .	16	„ „ Pregnancy in	
„ Author's, . . . . .	27	Bi-Cornuate	
„ Bianchi's, . . . . .	21	Uterus, . . . . .	204
„ Dezeimeris', . . . . .	22	„ „ „ in a Rudi-	
„ Josephi's, . . . . .	21	mentary	
„ Tait's, . . . . .	26	Horn, . . . . .	203
Combined Intra- and Extra-Uterine		„ „ Retroversion	
Gestation, . . . . .	18	of Gravid	
Concurrent Ectopic and Uterine		Uterus, . . . . .	195
Gestation, . . . . .	110	„ „ Spurious	
		Pregnancy, . . . . .	204

	PAGE		PAGE
Diagnosis, differential from Uterine Pregnancy, . . . . .	191	Labour, Spurious, duration of, . . . . .	169
Discharge of Uterine Decidua, . . . . .	157	"    "    influence of, on Fœtus, . . . . .	172
Electricity, use of, to destroy Ovum, . . . . .	209	"    "    premature, . . . . .	169
Elytrotomy, . . . . .	210	"    "    repeated, . . . . .	169
Enlargement of Abdomen, . . . . .	159	Ligament, Broad, Gestation, . . . . .	36
Etiology, . . . . .	1	Liquor Amnii, . . . . .	173
External wandering of Ovum, . . . . .	90	Lithopædion, . . . . .	94
Extra-Peritoneal Growth of Ovum, . . . . .	19, 24	Mammæ, Changes in, . . . . .	158
"    Hæmorrhage, . . . . .	46	Menstruation, Normal, Nature of, . . . . .	8
"    Rupture of Tube, . . . . .	38	"    Relation of, to Pregnancy, . . . . .	7
Fæcal Fistula, . . . . .	49	"    History of, in Ectopic Pregnancy, . . . . .	154
Fertilisation of Ovum, . . . . .	3	Micturition Troubles, . . . . .	178
Fœtal Heart, . . . . .	161	Mole, Tubal, . . . . .	74
"    Movements, . . . . .	161	Multiparity in Relation to Ectopic Gestation, . . . . .	105
Fœtus in Ectopic Gestation, . . . . .	112	Mummification, . . . . .	92
"    death of, at term, . . . . .	172	Muscular Part of Tube Wall, Changes in, . . . . .	115
"    destruction of, in Peritoneal Cavity, . . . . .	66	Nerves, Results of Pressure on, . . . . .	179
"    development of, . . . . .	112	Ovarian Pregnancy, so-called, . . . . .	14, 44
"    discharge of, through Abdominal Wall, . . . . .	50	"    "    first described Case of, . . . . .	17
"    "    "    Bladder, . . . . .	50	Pain in Ectopic Pregnancy, . . . . .	180
"    "    "    Bowel, . . . . .	49	Peritoneum, Changes in, . . . . .	41, 113
"    "    "    Perineum, . . . . .	50	Perineal Discharge of Fœtus, . . . . .	50
"    "    "    Uterus, . . . . .	50	Periodic Colicky Pains, . . . . .	155
"    "    "    Vagina, . . . . .	50	Peritonitis, . . . . .	28, 115, 180
Full Time Ectopic Gestation, changes at, . . . . .	169	Petrification, so-called, . . . . .	95
Genetic reaction in Müllerian Tract, after fertilisation of Ovum, . . . . .	11	Phylogeny of Genital Tract, . . . . .	4
Growth of Placenta, supposed, after death of Fœtus, . . . . .	101	"    "    Placenta, . . . . .	128
Hæmatocele, Sequelæ of, . . . . .	65	"    Displacement of, . . . . .	142
Hæmato-salpinx, . . . . .	73	"    Supposed growth of, after Death of Fœtus, . . . . .	101
Hæmorrhage from Uterus during Pregnancy, . . . . .	154	Plural Ectopic Gestation, . . . . .	109
"    into Broad Ligament, accompanying Rupture of Tube, . . . . .	46, 182	Pressure Symptoms, . . . . .	179
"    "    Peritoneal Cavity, . . . . .	61, 184	Primary Abdominal Pregnancy, so-called, . . . . .	28
Hernia of Ectopic Gestation, . . . . .	111	"    "    "    Koeberlé's supposed Case of, . . . . .	29
Hunter's Experiments on the fate of Blood poured into the Peritoneal Cavity, . . . . .	67	"    "    "    Lecluyse's supposed Case of, . . . . .	28
Injection of Poisons into Gestation Sac, . . . . .	208	Post-mortem Examination, Fallacies in, . . . . .	28
Intercurrent Uterine Gestation, . . . . .	110	Primiparity in relation to Ectopic Pregnancy, . . . . .	105
Interstitial Pregnancy, . . . . .	75	Proportion of Ectopic to Normal Gestations, . . . . .	106
"    "    first described, . . . . .	19	Puncture of Gestation Sac, . . . . .	207
Intervillous Circulation, . . . . .	139, 150	Pyo-salpinx, . . . . .	74
Intestines, relation of, to Ectopic Sac, . . . . .	37, 47, 49, 51, 179	Rectum, Delivery by, . . . . .	49
Intestinal Escape of Fœtus, . . . . .	49, 187	"    Examination by, . . . . .	190
Labour, Spurious, at Full Time, . . . . .	169		

	PAGE		PAGE
Rectum, Pressure on, . . . . .	179	Treatment, . . . . .	207
Repeated Ectopic Gestation, . . . . .	107, 169	Elytrotomy, . . . . .	201
Retention of Fœtus, . . . . .	92, 99, 111	Old methods of destroying Ovum through influences brought to bear on Mother, . . . . .	207
Rudimentary Uterine Cornu, Preg- nancy in, . . . . .	86	Compression of Gestation Sac, . . . . .	208
Rupture of Gestation Sac, . . . . .	56, 61, 181	Injection of Drugs into Sac, . . . . .	208
" " " at time of spurious Labour, . . . . .	188	Puncture of Sac, . . . . .	207
Side of Gestation, . . . . .	106	Use of Electricity, . . . . .	209
Signs and Symptoms of Ectopic Pregnancy, . . . . .	153	The best Methods to Adopt, . . . . .	213
Site of Gestation in Tube, . . . . .	106	Where combined Ectopic and Uterine Gestation exist, . . . . .	232
Souffle, . . . . .	161	" the Ectopic Gestation is of old stand- ing, . . . . .	232
Sound, use of, in Diagnosis, . . . . .	194	" " " is actively growing, . . . . .	232
Spurious Labour, . . . . .	169	" " " has passed Full Time, the Fœtus having died, . . . . .	229
Stirrage, . . . . .	159	" " " has reached Full Time, . . . . .	228
Sub-peritoneo-Pelvic Pregnancy, . . . . .	36	" " " is entirely Tubal, . . . . .	215
" " " first described, . . . . .	19	" " " Ampullar and Infun- dibular, . . . . .	215
" " Abdominal Pregnancy, . . . . .	37	" " " Interstitial, . . . . .	217
Suppuration, . . . . .	47, 51	" Mummification, &c., have followed Death of the Fœtus, . . . . .	230
" Symptoms of, . . . . .	185	" Pregnancy exists in a Rudimentary Horn, . . . . .	233
Symptoms and Signs of Ectopic Pregnancy, . . . . .	153	" Rupture into Broad Liga- ment has occurred, . . . . .	223
Those resulting from the Preg- nancy <i>per se</i> , . . . . .	153	" at time of Rupture, . . . . .	223
Abdominal Examination, . . . . .	159	" after Rupture, develop- ment of Ovum has continued, . . . . .	224
Bimanual Examination, . . . . .	173	" when a Secondary Rup- ture into Peritoneal Cavity occurs, . . . . .	218
Changes in Breasts, . . . . .	158	" Rupture into Peritoneal Cavity occurs, . . . . .	218
" " Uterus, . . . . .	162	" with marked Loss of Blood, Shock, &c., . . . . .	218
" " Vagina, . . . . .	162	" " Slight Symptoms, . . . . .	220
Constitutional and Sympa- thetic Changes, . . . . .	154	" " no Symptoms, . . . . .	220
Discharge of Uterine Decidua, . . . . .	157	" Suppuration has occurred in old or recent Ectopic Gestations, . . . . .	230
Fœtal Movements, . . . . .	161	" before the Pus has worked its way to the Exterior, . . . . .	230
" Heart-sounds, . . . . .	161	" after " . . . . .	231
Maternal Souffle, . . . . .	161	Tubal Abortion, . . . . .	70
Menstruation History, . . . . .	154	" Gestation, Developmental Changes in, . . . . .	118
Periodic Colicky Pains, . . . . .	155		
Phenomena at Full Time, . . . . .	169		
Stirrage, . . . . .	159		
Those resulting from Compli- cations, . . . . .	178		
Bladder, . . . . .	178		
Circulation, . . . . .	179		
Death of Fœtus, . . . . .	189		
Inflammation, . . . . .	180		
Internal Hæmatocele, . . . . .	184		
" Hæmatoma, . . . . .	182		
" Hæmato-salpinx, . . . . .	182		
" Hæmorrhage, . . . . .	182		
Nerve, . . . . .	179		
Pain, . . . . .	180		
Pressure Effects, . . . . .	178		
Rectum, . . . . .	179		
Rupture of Gestation Sac at Spurious Labour, . . . . .	188		
Suppuration, . . . . .	185		

	PAGE		PAGE
Tubal Gestation, Mucous Membrane,	117	Varieties of Ectopic Gestation studied	
"  "  Decidua Reflexa, . . .	129	in detail—	
"  "  "  Serotina, . . .	123	Mole Formation, . . .	74
"  "  "  Progressive Changes		Mummification, &c., . . .	74
in Blood		Pyo-salpinx, . . .	74
Vessels, 127, 129		Tubal Abortion, . . .	70
"  "  "  Connective		Persistent, . . .	33
Tissue, . . .	124	Ruptures into broad	
"  "  "  Epithelium,	124	ligament, . . .	36
"  "  "  Vera, . . .	117	Sub-Peritoneo-Pelvic	
"  "  Muscular Wall, . . .	115	Gestation, . . .	36
"  "  Peritoneum, . . .	113	May Grow to Full Time, 39	
"  "  Relations between Ovum		Rupture into Peritoneal	
and Decidua, . . .	133	Cavity, . . .	45
"  "  Early Importance of Fœtal		Terminate by Adipocere	
Epiblast, . . .	133	Formation, . . .	53
"  "  Amnion, . . .	151	"  Hæmatoma, 46	
"  "  Chorion, . . .	141	"  Lithopædion, 153	
"  "  Non-Placental Portion,	149	"  Mummifica-	
"  "  Placental Portion, . . .	142	tion, . . .	153
"  "  Attachment of Villi to		"  Suppuration, 47	
Decidua Serotina, . . .	146	Ruptures into Peritoneal	
"  "  Intervillous Circulation, 139,	150	Cavity, . . .	53
"  "  Formation of Villi, . . .	144	May Grow to Full Time,	
"  "  Mucosa outside Ovum, . . .	132	Tubo-Peritoneal, . . .	53
Tubo-Abdominal Gestation, so-called,	20	May Terminate, . . .	61
"  -Ovarian " " " "	20	Sequæ of Hæmatocele, 63	
"  -Peritoneal Gestation, . . .	53	Infundibular Tubal, . . .	83
Twin Pregnancy, . . .	111	Tubo-Ovarian and Tubo-	
Uterine Escape of Fœtus, . . .	50	Abdominal, so-called, 32, 83	
Uterus in Ectopic Gestation, . . .	162	Interstitial Tubal, . . .	75
Utero-Interstitial Gestation, so-called,	19	Ovum may die and	
"  -Tubal " " " "	20	be retained under-	
"  -Tubo-Abdominal, " " "	20	going various Changes, 83	
Vaginal Changes, . . .	162	Persistent, . . .	179
"  Discharge of Ovum, . . .	50	Rupture may occur into	
"  Pregnancy, so-called, . . .	18	Broad Ligament, 82	
"  Section, . . .	210	"  Peritoneal Cavity, 79	
Varieties of Ectopic Gestation studied		"  Uterine " " 81	
in detail, . . .	33	"  Peritoneal and	
"  Ampullar Tubal, . . .	33	Uterine Cavities, 81	
"  Gestation Destroyed, . . .	70	Vesical Fistula, . . .	50, 186, 231
"  Hæmato-salpinx, . . .	73	Villi Attachment to Serotina, . . .	146
		"  Changes in, . . .	146
		"  Formation of, . . .	141, 144

## PLATE I.

FIG. 1.

Wall of gestation sac (tubal) at full time. The membranes are not shown.

(a) Connective tissue.

(b) Muscular bundles.

× 175.

FIG. 2.

Transverse section through ampullary part of Fallopian tube (referred to on pp. 11, 119) showing simple arrangement of folds of mucosa, and also decidual changes in them. The tube of the opposite side was occupied by a two months' pregnancy.

(a) Folds of mucosa showing decidual changes.

(b) Muscular part of wall.

× 10.

FIG. 3.

Another portion of the same.

× 10.






Fig 1

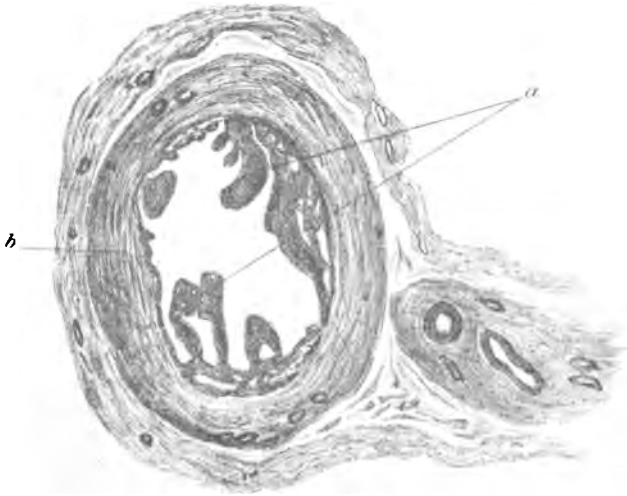


Fig 2

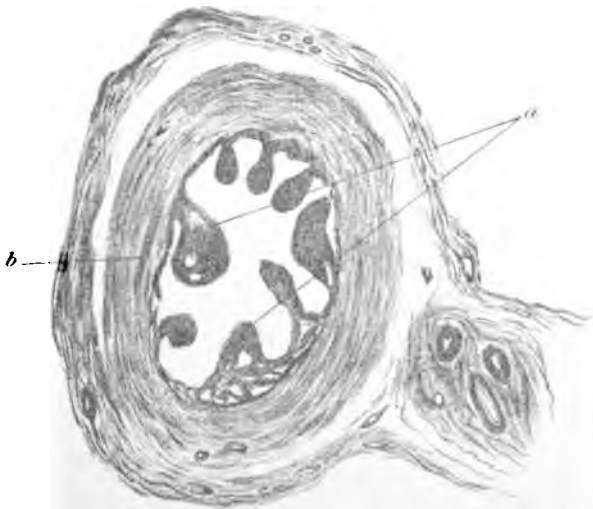

Fig 3

## PLATE II.

FIG. 1.

Transverse section of ampulla of Fallopian tube in the case mentioned on p. 120, in which the opposite tube was in a state of early pregnancy. Note the abnormal appearance of the mucosa. It bears considerable resemblance to the uterine cornu of several mammals. Decidual cells were found in several places in it. (This condition of the mucosa might be supposed to have resulted from endosalpingitis; there is, however, not a trace of inflammation to be found).

× 25-30.

FIG. 2.

A small portion of the normal tubal mucosa, ampullary portion, from a transverse section.

- (a) Branching fringes of mucosa.
- (b) Muscular part of tube wall.

× 50

FIG. 3.

A small piece of normal tube wall.

- (a) Columnar ciliated epithelium of mucosa; this is from a part between two fringes.
- (b) Muscular part of wall. Note the small quantity of sub-epithelial connective tissue in the mucosa.

× 435.



Fig 1.

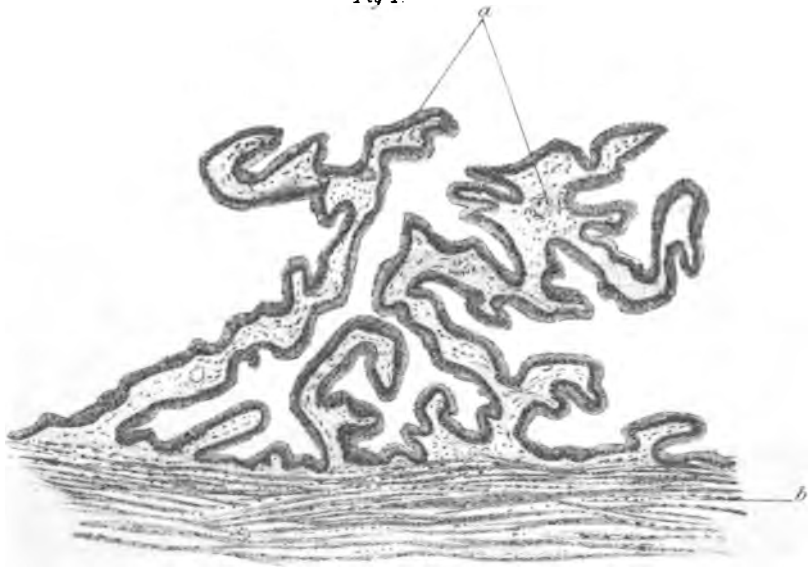


Fig 2



Fig 3

## PLATE III.

### FIG. 1.

Decidual formation in tubal mucosa. Specimen referred to in Plate I., figs. 2 and 3.

- (a) Flattened and partly separated mucosal epithelium (originally columnar).
- (b) Decidual cells in various stages of formation.
- (c) Muscular bundles.

× 230.

### FIG. 2.

Section across one of the fringes of mucosa in a normal tube.

- (a) Columnar ciliated epithelium.
- (b) Delicate connective tissue core.

× 435.

### FIG. 3.

Section across one of the fringes of mucosa in tube showing decidual changes.

- (a) Flattened epithelium.
- (b) Broken and degenerating epithelium.
- (c) Decidual changes in connective tissue core.

× 230.

### FIG. 4.

Decidual tissue torn up by blood extravasation.

- (a) Branching decidual cells.
- (b) Blood corpuscles.

× 435.

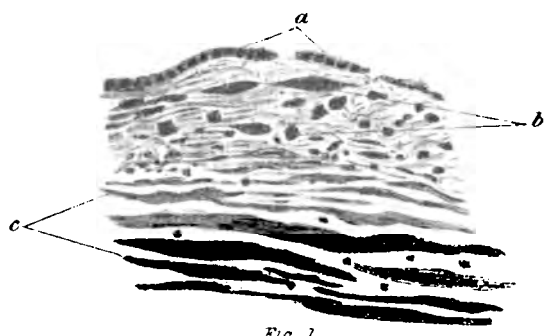


Fig 1

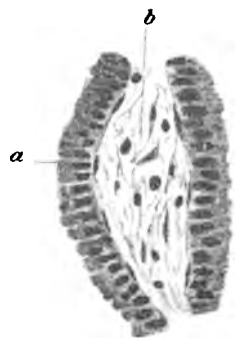

Fig 2

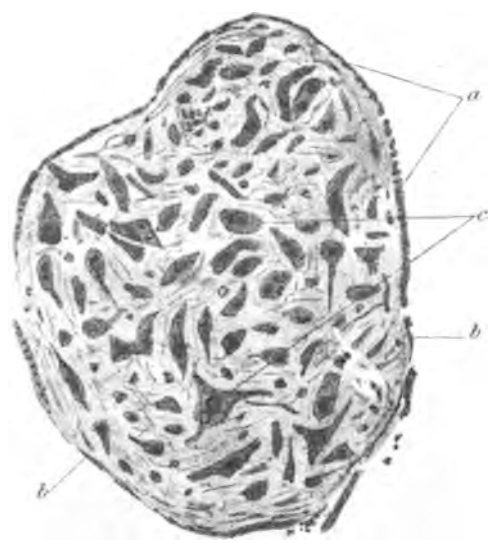


Fig 3

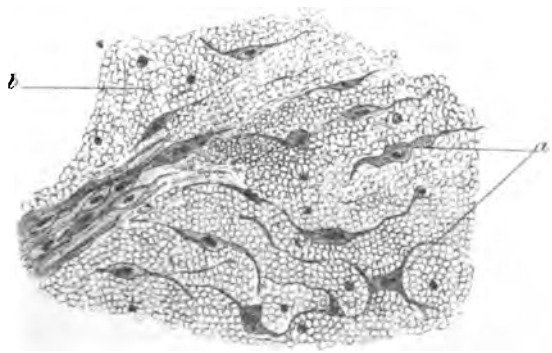


Fig 4

## PLATE IV.

FIG. 1.

A portion of wall showing decidual changes in the mucosa.

- a Marked formation of decidual cells in superficial compact layer
- Spaces in the deep or spongy layer.
- c) Muscle.

x 52.

FIG. 2.

Another portion showing the same conditions.

- (a) Marked decidual formation in two of the simple fringes of mucosa
- (b) Spaces of spongy layer ; in them lies cast-off epithelium.
- (c) Muscle.

x 52.

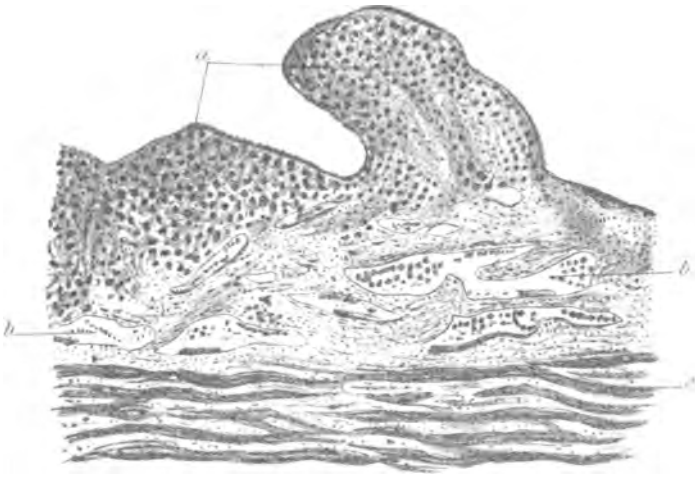


Fig. 1

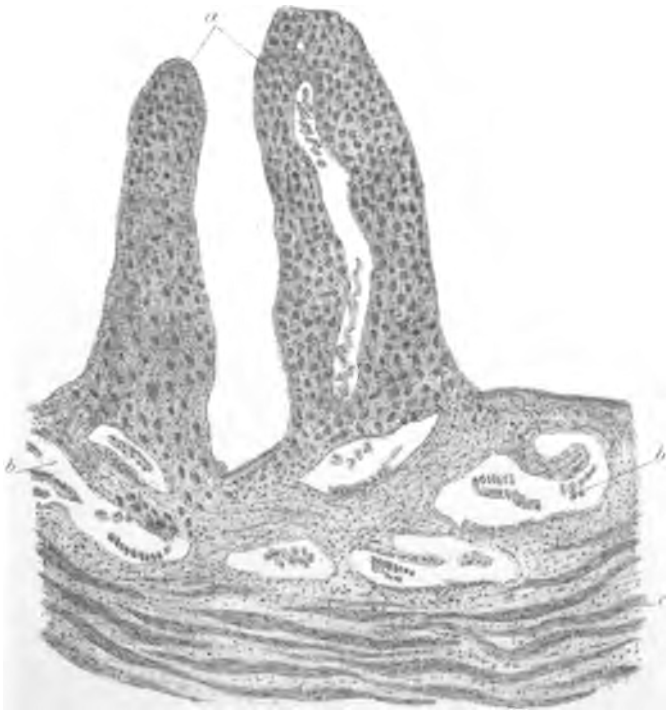


Fig. 2

## PLATE V.

FIG. 1.

Another part of the tube showing the same conditions.

- (a) Decidual changes in mucosa fringes.
- (b) Spaces of spongy or deep layer.
- (c) Muscle.

× 52.

FIG. 2.

This section shows a bit of the spongy layer highly magnified. In the upper part of the section are seen a few decidual cells belonging to the compact layer of the mucosa. The decidual changes have not extended far into the spongy layer.

- (a) Decidual cells of compact layer.
- (b) Spaces of spongy layer containing cast-off and degenerating epithelium.
- (c) Muscle.
- (d) Ordinary connective tissue cells of the mucosa.

× 435.



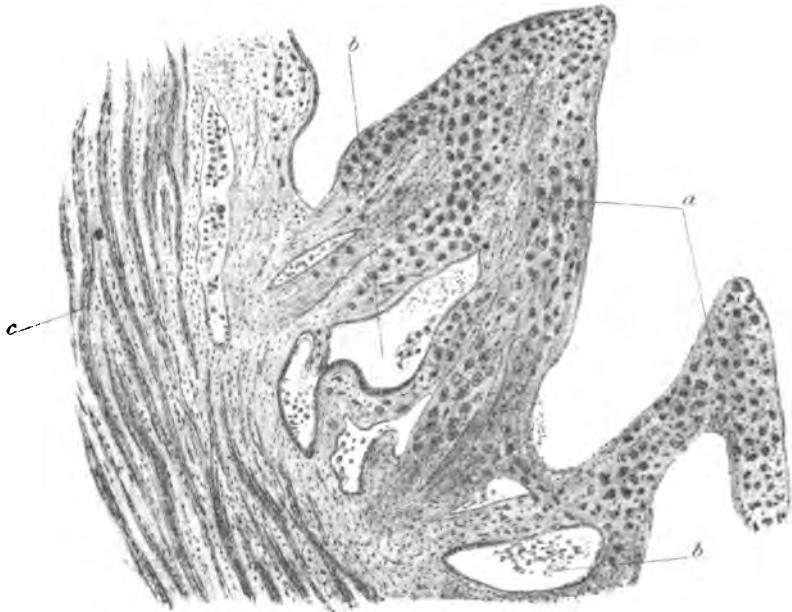


Fig 1

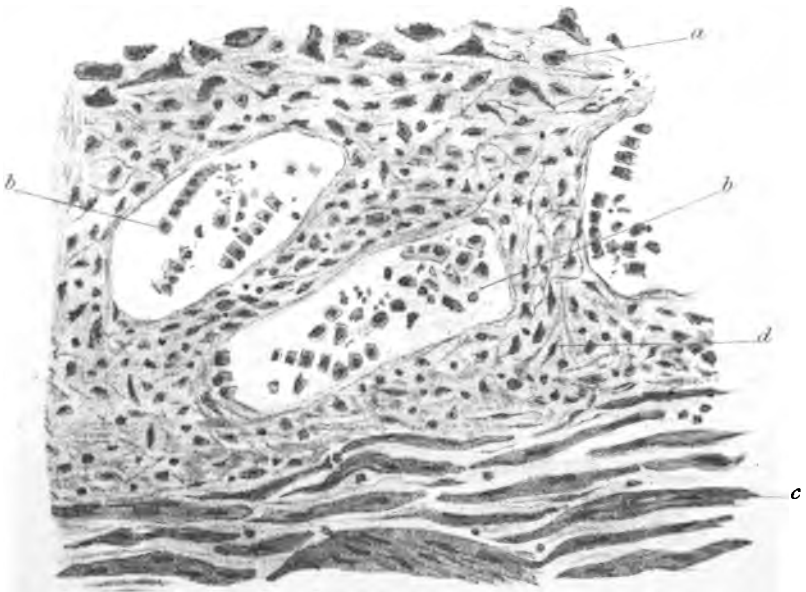


Fig 2

## PLATE VI.

FIG. 1.

Another section showing short projecting folds of mucosa in which decidual changes are progressing.

- (a) Fringes of mucosa.
- (b) Muscular part of tube wall.

× 52.

FIG. 2.

Another section showing a very short broad fringe with decidual changes.

- (a) Fringe of mucosa.
- (b) Muscle of tube wall.

× 52.

FIG. 3.

A portion of the compact layer of decidua, with gland-like spaces. They are either gland-like spaces which have been present from the first, or are artificially formed by the blending of the outer portions of adjacent mucosal fringes, in the process of decidual transformation.

- (a) Connective tissue with some decidual cells.
- (b) Gland-like spaces.

2 mos. × 175.

FIG. 4.

Villus attached to decidua serotina not by its end, but by its side. There is very little proliferation of the epithelial (chorionic epiblast) cells covering it.

- (a) Delicate mucoid tissue of villus.
- (b) Epithelial covering somewhat proliferated in its deep layer.
- (c) Mass of foetal epithelium, remains of original epiblastic proliferation-trophoblast layer, lying on decidual surface.
- (d) Capillary space in decidua.
- (e) Gland-like space in decidua.

2 mos. × 97.

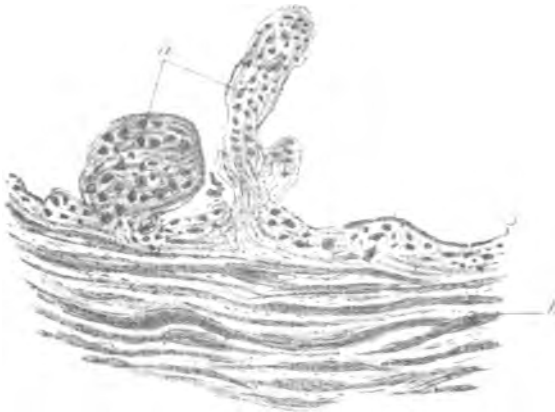


Fig 1




Fig 2

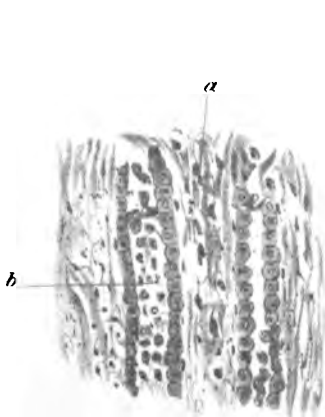


Fig 3

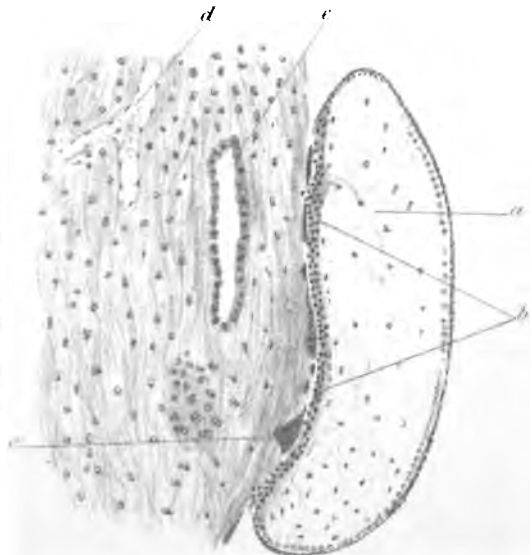


Fig 4

## PLATE VII.

FIG. 1.

Section through compact layer of decidua serotina.

- (a) Villus partly embedded in serotina.
- (b) Row of cubical cells, probably remains of epithelium which lined a gland-like space.
- (c) Decidual cells.
- (d) Another embedded villus.
- (e) Fœtal epiblast lying on decidua.

3 mos. × 52.

FIG. 2.

Compact layer of decidua.

- (a) Superficial mass of degeneration, probably coagulation-necrosis.
- (b) Muscular bundles of tube wall.

Note also scattered decidual cells, and rows of cells which have probably belonged to gland-like spaces.

2 mos. × 175.

FIG. 3.

Compact layer of decidua.

- (a) Degenerated layer in upper part.
- (b) Decidual cells.
- (c) Layer of homogeneous nucleated protoplasm, remains of original fetal epiblast.

2 mos. × 175.

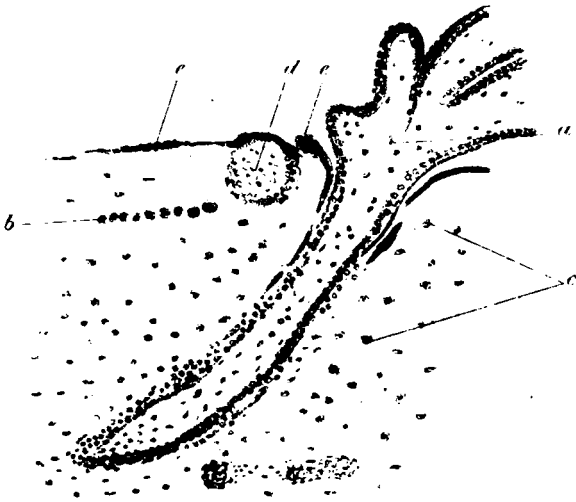


Fig 1

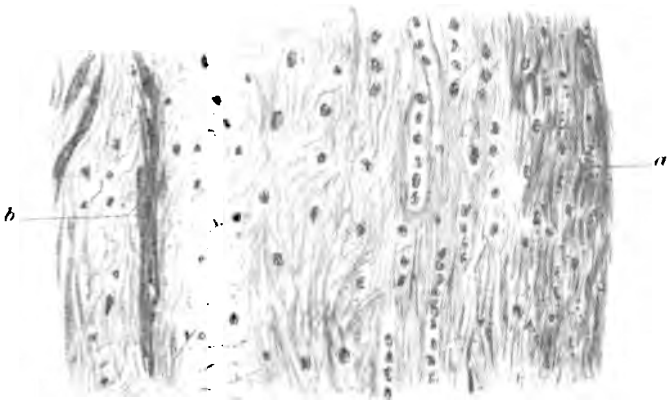


Fig 2

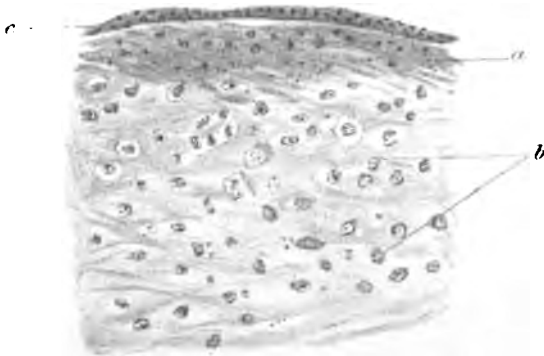


Fig 3

## PLATE VIII.

FIG. 1.

Another of the same.

- (a) Decidual cells.
- (b) Superficial layer of original trophoblastic layer.
- (c) Mass of nucleated protoplasm of same nature as that on the surface of the decidua; this is probably a section through a projection from the surface layer which has extended inwards obliquely.

2 mos.  $\times$  175.

FIG. 2.

Section across wall of gestation sac (tubal) wall at full time.

- (a) Villi attached to serotina.
- (b) Remains of foetal epiblast on surface.
- (c) Thickness of decidua; there are few cells seen.
- (d) Thickness of sac wall; it is made up almost entirely of connective tissue.

9 mos.  $\times$  97.

FIG. 3.

Another of the same.

- (a) Villus.
- (b) Remains of foetal epiblast layer.
- (c) Thickness of sac wall.

Note that the decidual layer has almost entirely disappeared.

9 mos.  $\times$  97.

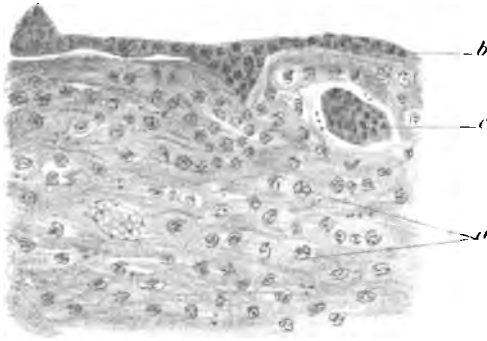


Fig 1

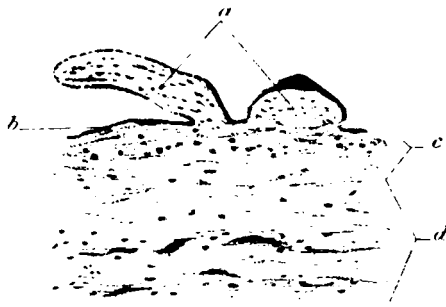


Fig 2

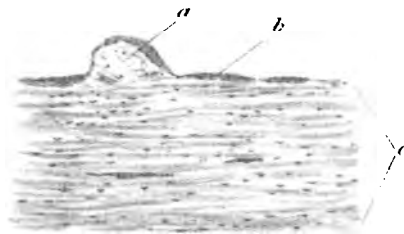


Fig 3

## PLATE IX.

FIG. 1.

Section through part of placenta and tube wall.

- (a) Amnion.
- (b) Chorion.
- (c) Large villus-stem.
- (d) Villi.
- (e) Villus attached to decidua.
- (f) Blood sinus in decidua.
- (g) Decidual tissue.
- (h) Muscular part of wall.

2 mos. × 10.

FIG. 2.

Section through reflexa, amnion and chorion.

- (a) Decidual tissue of reflexa; there are few large decidual cells and many leucocytes.
- (b) Large blood spaces.
- (c) Remains of a villus of chorion lœve embedded in surface.
- (d) Another villus embedded; it is quite degenerated having lost its covering epithelium.
- (e) Remains of fetal epiblast on surface of reflexa.

2½ mos. × 88.



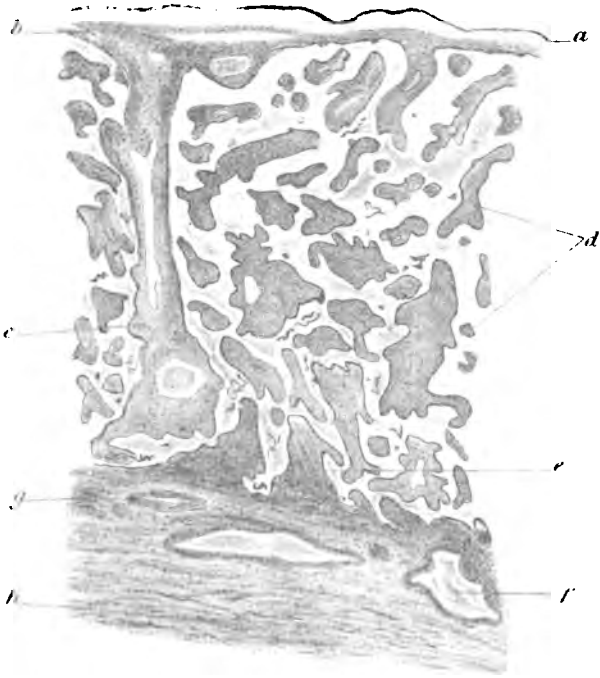


Fig. 1

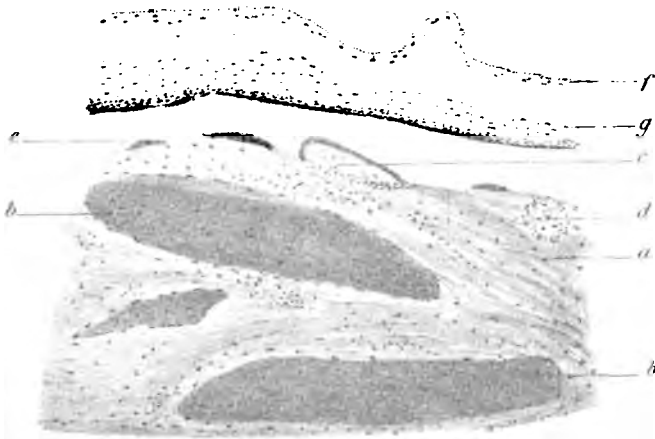


Fig. 2

## PLATE X.

FIG. 1.

Decidua serotina at third month.

- (a) Numerous large decidual cells.
  - (b) Fibrin and blood lying on surface of decidua.
  - (c) Foetal epiblastic remains on surface.
  - (d) Degenerated superficial decidual tissue.
  - (e) Fibrin from blood extravasation in deep layers of serotina.
- 3 mos. × 175.

FIG. 2.

Decidua serotina and part of muscular wall of tube.

- (a) Projecting fringe of mucosa showing marked decidual changes in its connective tissue.
  - (b) Decidual cells in another part of mucosa.
  - (c) Blood sinus.
  - (d) Marked endothelial proliferation—trophospongia formation ; it extends out somewhat into surrounding tissue.
- 5 to 6 weeks × 97.

FIG. 3.

Section through part of decidua serotina.

- (a) Decidual tissue.
  - (b) Large blood sinus.
  - (c) Trophospongia.
  - (d) Extension outwards of trophospongia towards surface.
  - (e) Villus attached to surface ; the proliferated cells of its epithelium join the trophospongia.
  - (f) Remains of foetal epiblast on surface of decidua.
- 3 mos. × 97.

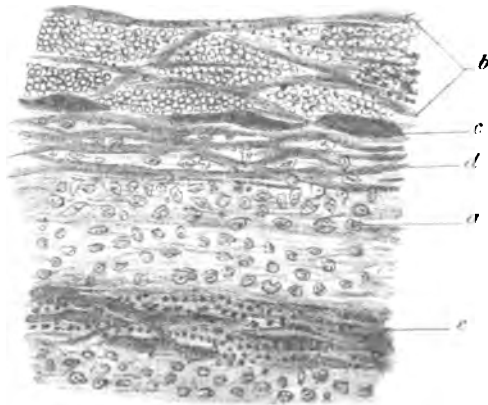


Fig 1

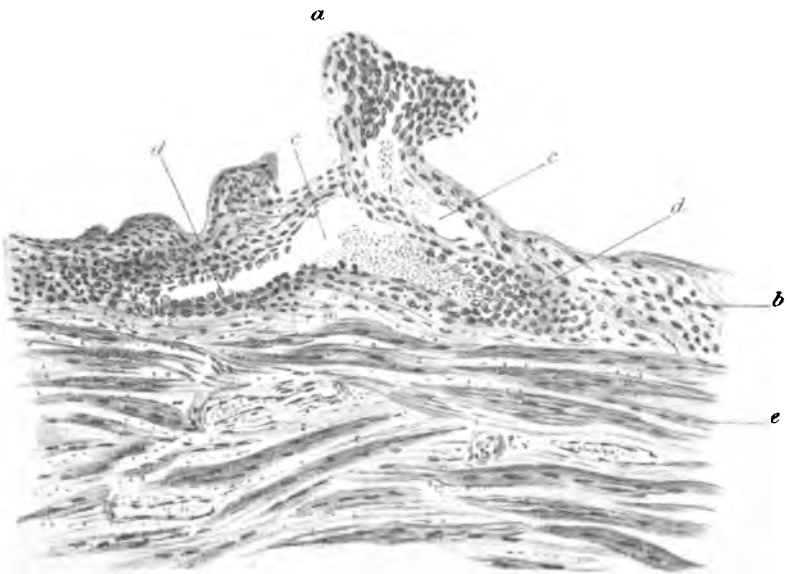


Fig 2

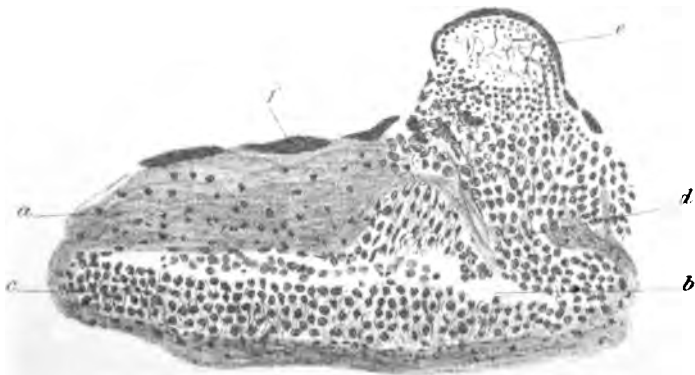


Fig 3

## PLATE XI.

FIG. 1.

Part of decidua serotina.

- (a) Decidual tissue.
- (b) Part of large sinus in decidua opening outwards into intervillous space.
- (c) Blood in sinus.
- (d) Masses of foetal epiblast; they have apparently led to the absorption of decidual tissue so as to open into blood sinus.
- (e) Villus.

2 mos.  $\times$  175.

FIG. 2.

Part of decidua serotina with villus attached by its side.

- (a) Villus.
- (b) Decidua.
- (c) Large sinus in decidua.
- (d) Proliferated endothelium—trophospongia.
- (e) Remains of foetal epiblast on surface of decidua.

3 mos.  $\times$  175.

FIG. 3.

Artery at junction of muscular and decidual part of tube.

- (a) Artery with blood and cast-off endothelium in its lumen.
- (b) Decidua.
- (c) Muscle.
- (d) Proliferated endothelium.

5 to 6 weeks  $\times$  38.

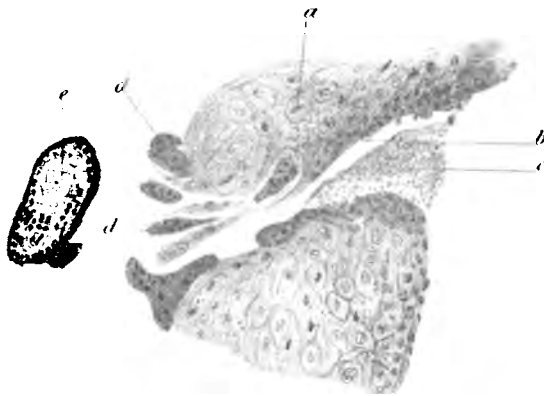


Fig 1

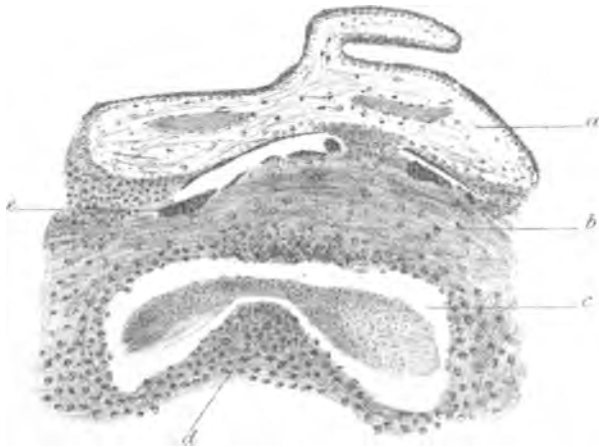

Fig 2

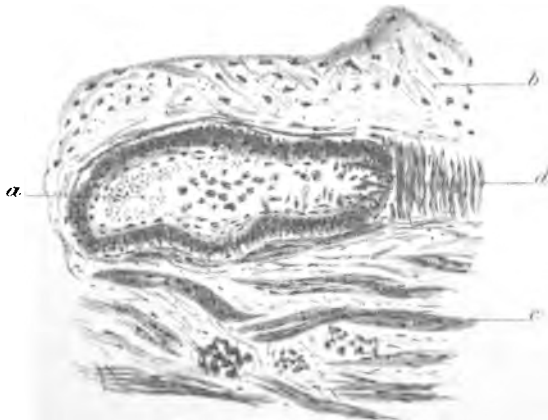

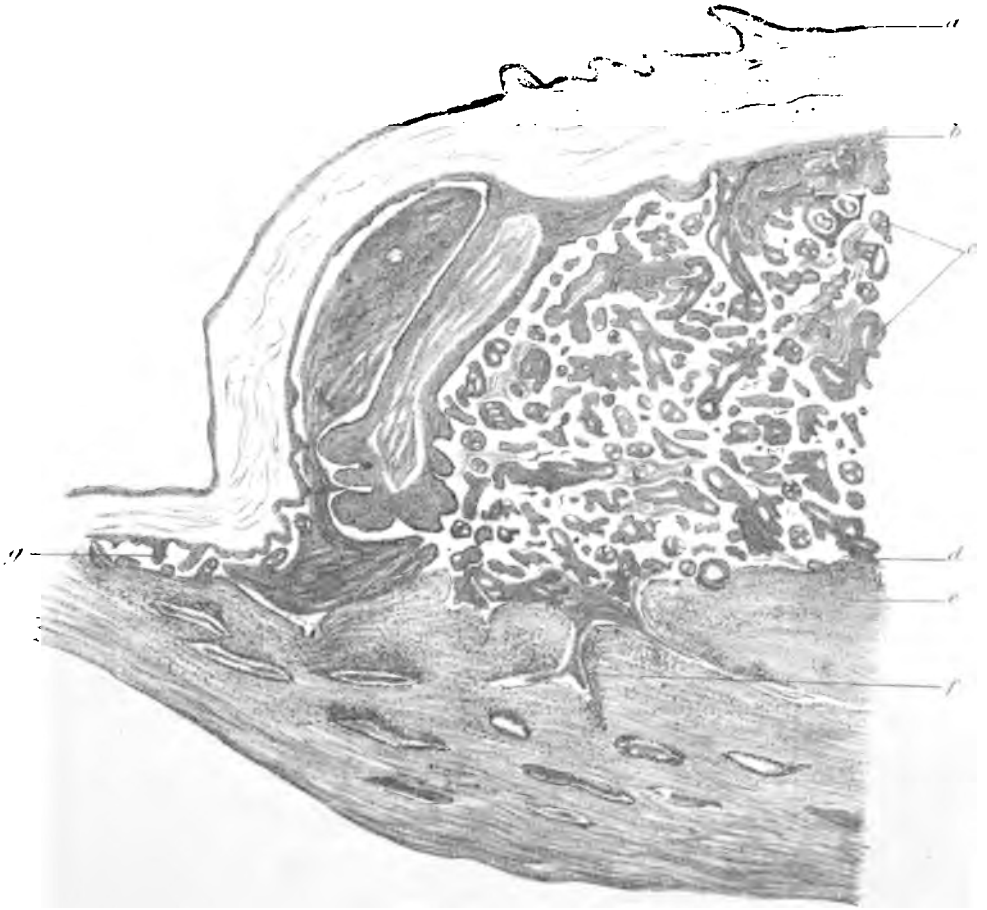
Fig 3

## PLATE XII.

Section through decidua and placenta.

- (a) Amnion.
- (b) Chorion.
- (c) Villi.
- (d) Villus attached to surface.
- (e) Decidua.
- (f) Large blood sinus opening into intervillous spaces.
- (g) Remains of villi between membranes and decidua outside serotina.

3 mos. × 10.



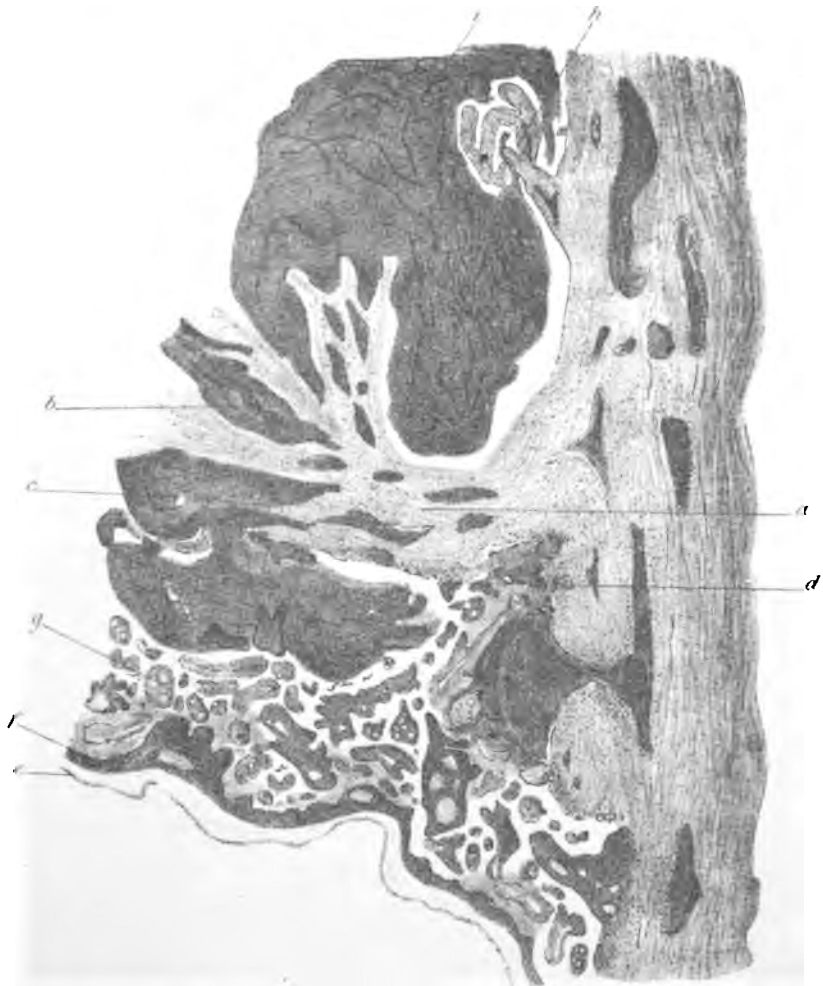
## PLATE XIII.

Section through decidua reflexa and part of tube wall outside it.

- (a) Decidual tissue of reflexa.
- (b) Blood space in reflexa.
- (c) Blood space which has burst through foetal surface, tearing apart villi.
- (d) Villus attached to surface.
- (e) Amnion.
- (f) Chorion.
- (g) Villi.

2½ mos. × 10.





## PLATE XIV.

FIG. 1.

Section through one wall of a blood space in decidua.

- (a) Decidual tissue.
- (b) Endothelial proliferation—trophospongia, extending outwards absorbing decidua.

3 mos. × 435.

FIG. 2.

Section across a blood sinus.

- (a) Lumen of vessel.
- (b) Endothelium unchanged on one side.
- (c) Marked endothelial proliferation—trophospongia.

4 mos. × 435.

FIG. 3.

Section through membranes, blended reflexa and vera, and part of muscular wall of tube.

- (a) Amnion.
- (b) Chorion.
- (c) Villi attached to surface of reflexa; they are fibrous and have, to a great extent, lost their covering epithelium.
- (d) Blended reflexa and vera.
- (e) Muscular part of wall.
- (f) Blood sinus.
- (g) Remains of foetal epiblast on surface of reflexa.

4 mos. × 38.

FIG. 4.

Another of the same.

- (a) Amnion.
- (b) Chorion.
- (c) Reflexa and vera.
- (d) Muscular part of wall.

3 mos. × 38.

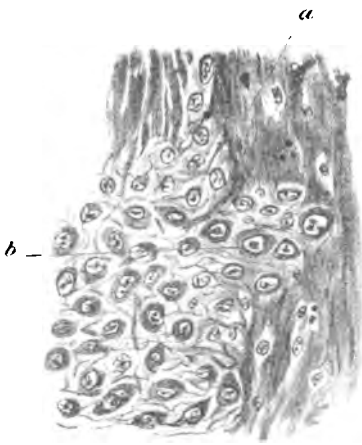


Fig 1

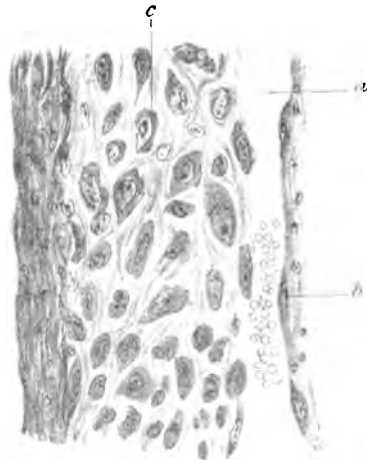


Fig 2

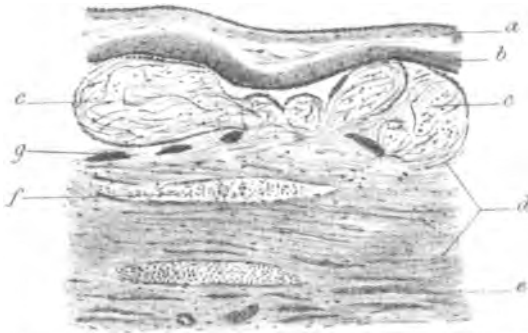


Fig 3

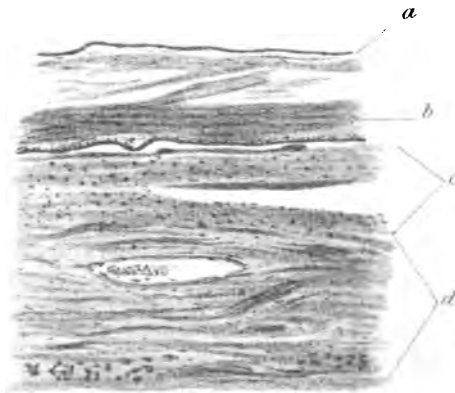


Fig 4

## PLATE XV.

FIG. 1.

Another of the same.

- (a) Amnion.
- (b) Chorion.
- (c) Villi are embedded in the decidua, they have undergone fibrous change, and have lost their epithelium.
- (d) Decidua.
- (e) Muscular bundles of tube wall.

2½ mos. × 38.

FIG. 2.

Villus attached to a decidual hillock; the latter is probably the remains of a mucosal fold.

- (a) Villus.
- (b) Decidual tissue.
- (c) Remains of foetal epiblast on surface of decidua.

2 mos. × 97.

FIG. 3.

Decidua with villi attached and embedded in various ways.

- (a) Projecting mass of decidual tissue.
- (b) Villi.
- (c) Remains of foetal epiblast.

3 mos. × 38.

FIG. 4.

Villus attached to decidua serotina.

- (a) Connective tissue of villus.
- (b) Surface layer of epithelium; note its resemblance to the foetal epiblast found on surface of decidua.
- (c) Proliferated mass of deep layers of epithelial cells on end of villus.
- (d) Remains of foetal epiblast on surface of decidua.
- (e) Decidua serotina.

2 mos. × 175.

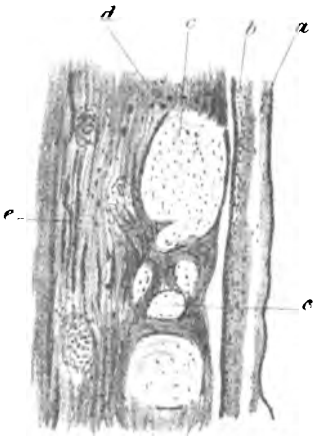


Fig 1

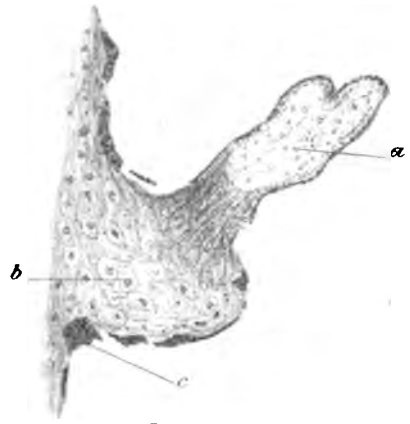


Fig 2

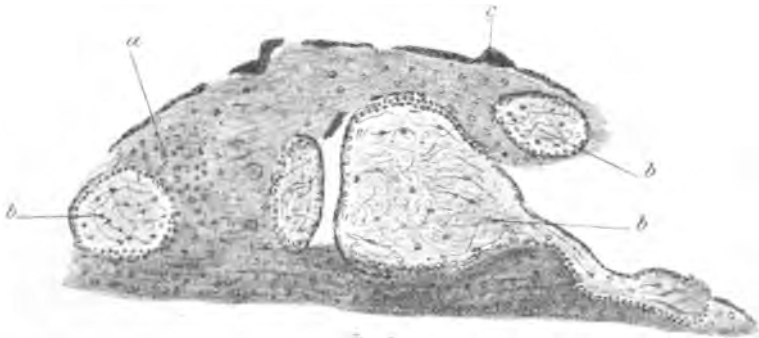


Fig 3

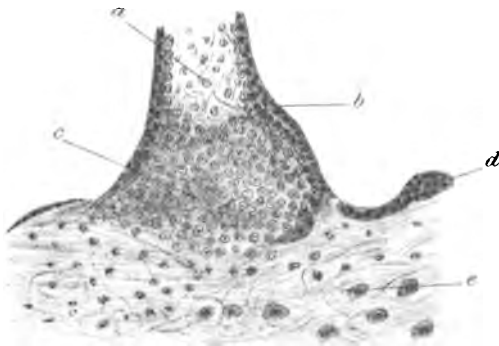


Fig 4.

## PLATE XVI.

FIG. 1.

Serotina and villi.

- (a) Proliferating cells of deep layer of the epithelium covering the villi, before adhesion to the decidua.
- (b) Superficial layer of cells being stretched, broken and cast off.
- (c) Remains of foetal epiblast on surface of decidua.
- (d) Decidua.

2 mos. × 175.

FIG. 2.

Attachment of villus to serotina by a plasmodium-like stalk of foetal epiblast.

- (a) Villus.
- (b) Stalk of epiblast continuous with superficial layer of villus and with that on decidual surface.
- (c) Decidua.

2 mos. × 230.

FIG. 3.

Another of the same.

- (a) Villus.
- (b) Stalks of foetal epiblast.
- (c) Remains of foetal epiblast on surface of decidua.
- (d) Decidua.

2 mos. × 230.

FIG. 4.

Masses of foetal epiblast and early villus.

- (a) Multinucleated plasmodium-like mass.
- (b) Early villus; the epiblast ring has a core of young connective tissue.
- (c) Strands of epiblast.
- (d) Pale hyaline strand with nuclei broken into granules—degenerating.

3 mos. × 500.

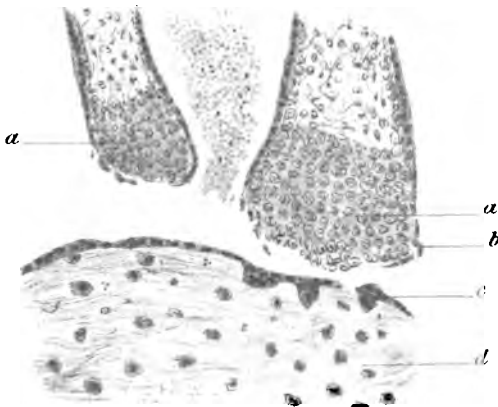


Fig 1

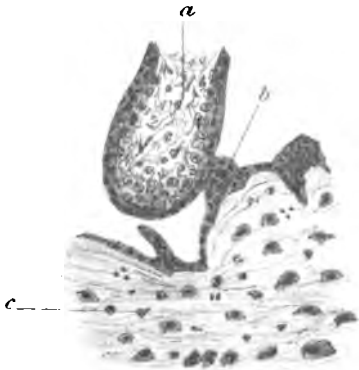


Fig 2

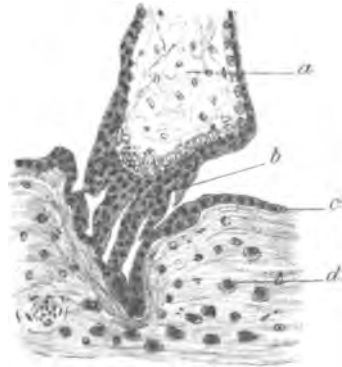


Fig 3



Fig 4

## PLATE XVII.

FIG. 1.

Reticulated mass of plasmodium-like foetal epiblast, probably the remains of early epiblastic connection between ovum and decidua. In one part it is continuous with the layer lying on the decidua.

- (a) Decidua.
- (b) Reticulated epiblast.
- (c) Epiblastic layer on surface of decidua.
- (d) Maternal blood corpuscles.

5 to 6 weeks  $\times$  435.

FIG. 2.

Large blood sinus in decidua opening into intervillous space.

- (a) Sinus.
- (b) Decidua.
- (c) Masses of foetal epiblast which have spread along walls of sinus.
- (d) Maternal blood.

2 mos.  $\times$  38.



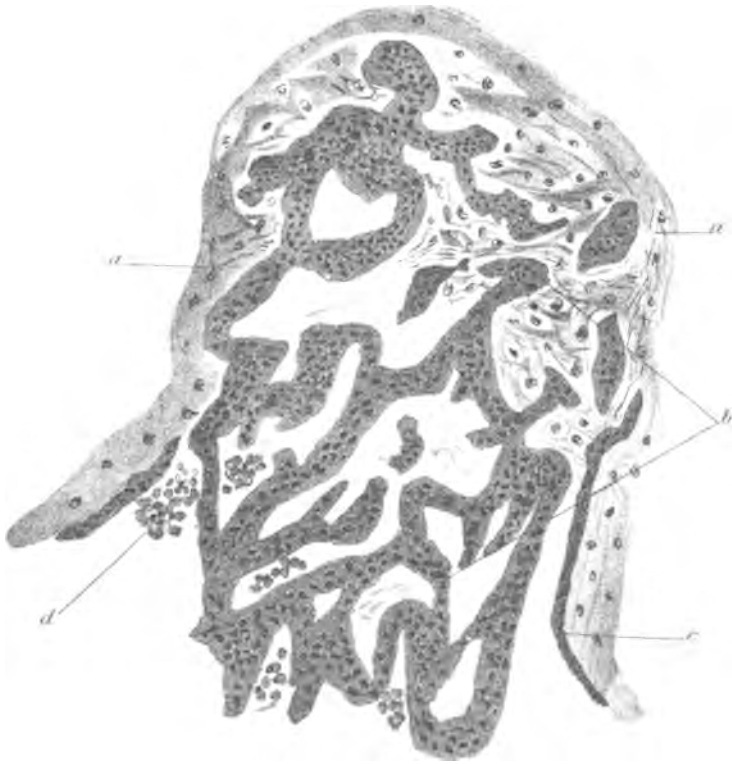


Fig 1

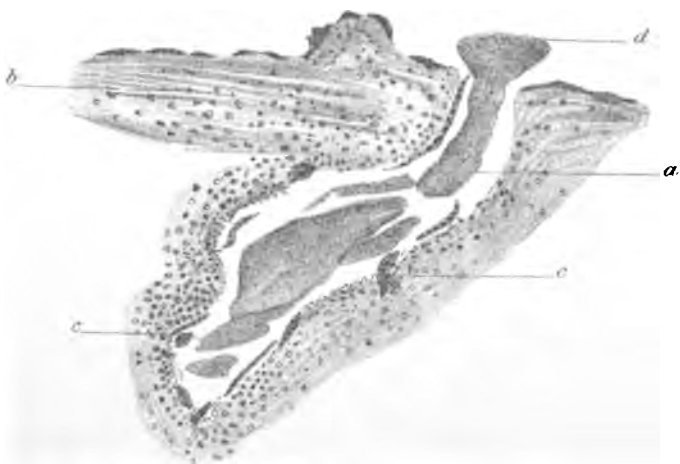

Fig 2

## PLATE XVIII.

FIG. 1.

Sinus in decidua with masses of foetal epiblast attached to its side and lying in its lumen.

- (a) Sinus.
  - (b) Foetal epiblast.
  - (c) Decidual tissue.
  - (d) Muscular bundles of tube wall.
  - (e) A mass of foetal epiblast occupying part of the lumen of a small vessel.
- 2 mos.  $\times$  38.

FIG. 2.

Section through amnion and chorion.

- (a) Amnion.
  - (b) Chorion.
  - (c) Vessel in chorion containing foetal blood.
  - (d) Part of a villus-stem.
- 3 mos.  $\times$  97.

FIG. 3.

Another section of amnion and chorion highly magnified.

- (a) Superficial layer of low cubical epithelial cells of amnion.
  - (b) Connective tissue layer of amnion.
  - (c) Superficial darkly stained epithelial layer of chorion—note a thickening at one part; this layer is the same in nature as that seen on the surface of the decidua and villi.
  - (d) Deep layer of epithelial covering of chorion: it is here several layers in thickness.
  - (e) Connective tissue of chorion.
- 3 mos.  $\times$  400.

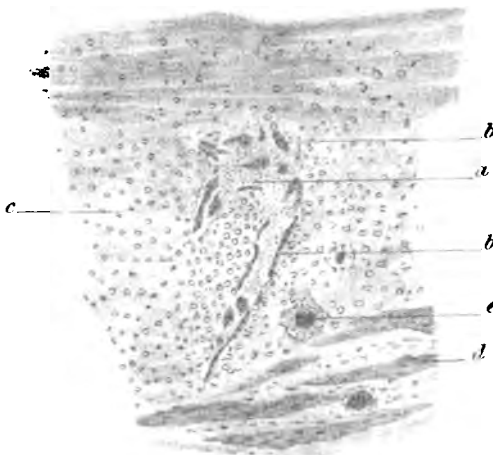


Fig 1

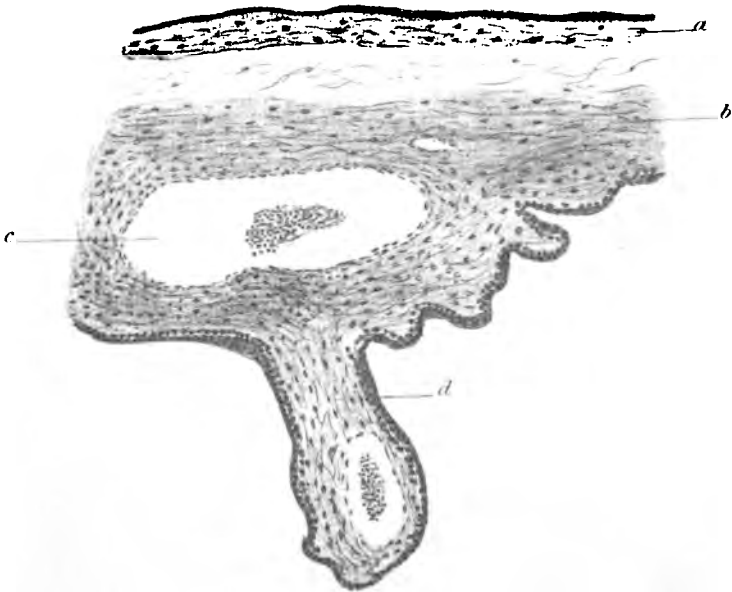


Fig 2




Fig 3

## PLATE XIX.

FIG. 1.

Another of the same.

- (a) Amnion.
- (b) Chorion.

The chorionic connective tissue is thicker, and the deep layer of epithelial cells thinner than in Fig. 3.

3 mos. × 400.

FIG. 2.

Another section of amnion and chorion.

- (a) Amnion.
- (b) Chorion.
- (c) Villus-stem.

Note variations in thickness of chorionic epithelial layer; at one point it is splitting in its superficial part.

9 mos. × 97.

FIG. 3.

Another section of amnion and chorion, highly magnified.

- (a) Amnion; note the small amount of the connective tissue layer.
- (b) Chorion; note the thinness of its epithelial covering.

3 mos. × 400.

FIG. 4.

Another section showing amnion and chorion completely blended.

- (a) Amniotic epithelium.
- (b) Chorionic epithelium; note how this layer varies in thickness and tends to split into layers.

9 mos. × 97.

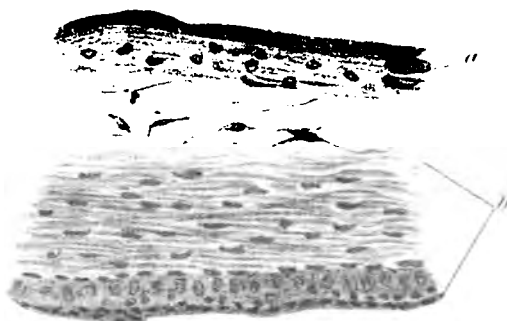


Fig 1



Fig 2




Fig 3.

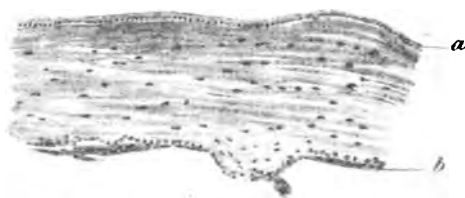


Fig 4.

## PLATE XX.

FIG. 1.

Early villus formation.

- (a) Epiblastic covering.
- (b) Mesoblastic core.

6 weeks × 540.

FIG. 2.

Early villus formation.

- (a) Epiblastic covering.
- (b) Mesoblastic core.
- (c) Large villus-stem from which villus is arising.

6 weeks × 540.

FIG. 3.

Another of the same.

- (a) Villus bud.
- (b) Main villus-stem.

2 mos. × 540.

FIG. 4.

Transverse section of early villus.

- (a) Superficial layer of epiblastic covering.
- (b) Deep layer of cells of epiblast.
- (c) Branching cells of mesoblastic core.
- (d) Capillary of villus.

3 mos. × 540.

FIG. 5.

Another section of an early villus.

- (a) Outer layer of epiblastic covering; note the small number of cells belonging to the deep layer.
- (b) Deep cells of epiblast.
- (c) Connective tissue core of villus.
- (d) A bud of the superficial epiblastic layer.

2 mos. × 405.

FIG. 6.

Another of the same.

- (a) Epiblastic covering.
- (b) Connective tissue.
- (c) Strand of epiblast attached to villus.

2 mos. × 405.

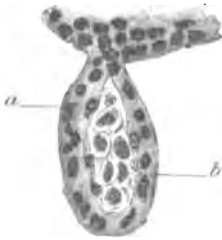

Fig 1

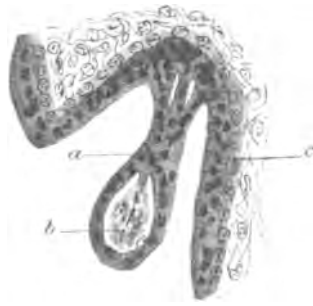


Fig 2

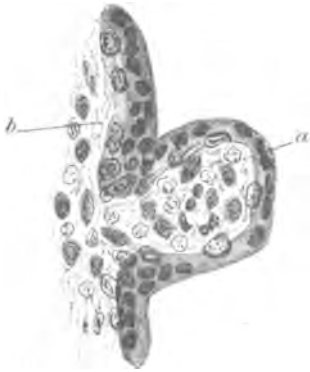

Fig 3

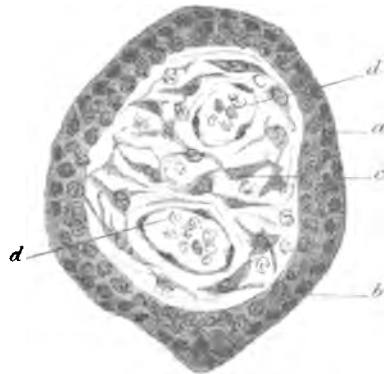


Fig 4

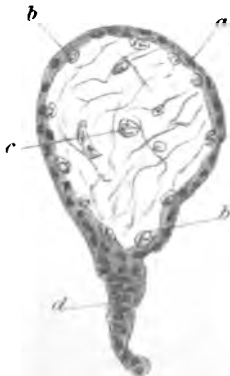

Fig 5

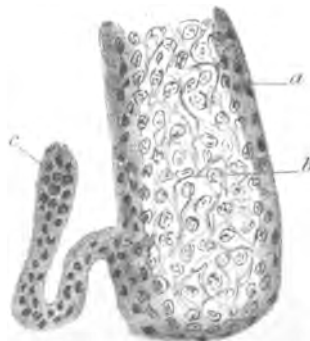


Fig 6

## PLATE XXI.

FIG. 1.

Villi from full time placenta.

Note the condensed fibrous nature of the connective tissue. The epithelial covering is very thin in some parts, split up in others, and in others almost entirely removed.

9 mos.  $\times$  52.

FIG. 2.

Section through a part of the decidua serotina and placenta at full time.

- (a) Decidua ; it is thicker in this section than in any others which I have made in cases of full time ectopic gestation.
- (b) Villi.
- (c) Remains of foetal epiblast on surface of decidua ; very little of this is found at full time.
- (d) Intervillous space in which maternal blood circulates.
- (e) Blood sinus in decidua.
- (f) Well formed decidual cells.
- (g) Degenerated layer in decidua.

9 mos.  $\times$  97.



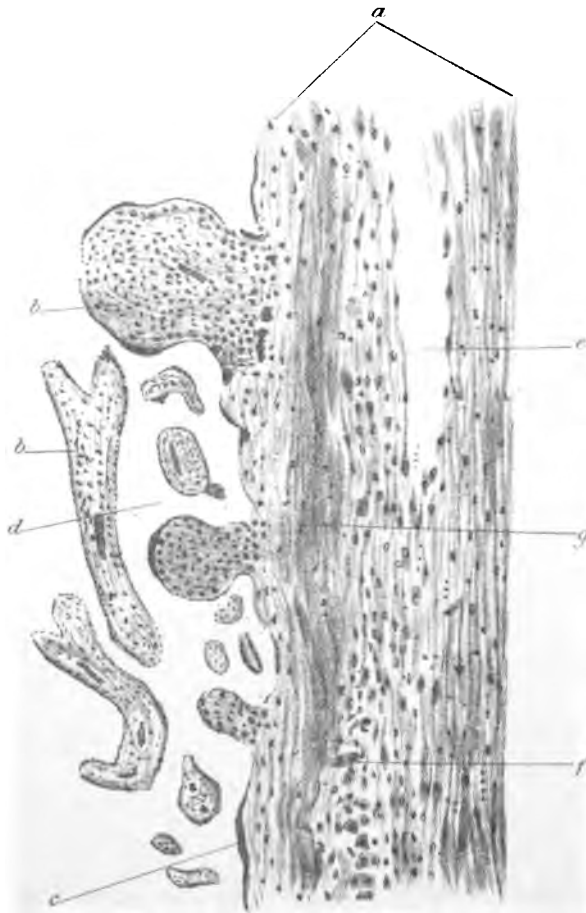
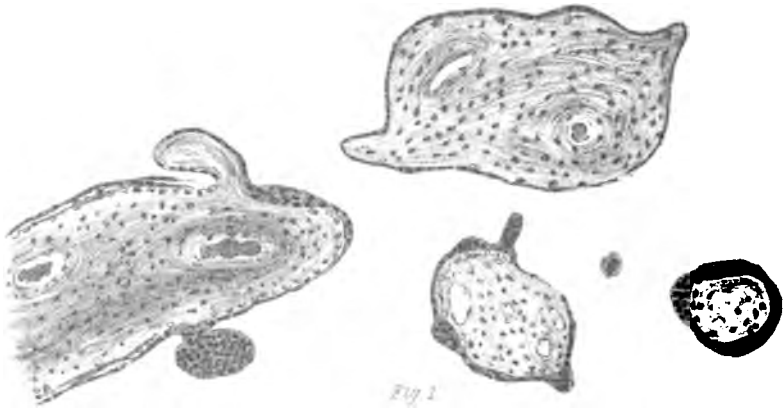


Fig 2

## PLATE XXII.

FIG. 1.

Superficial layer of uterine decidua in tubal gestation.

- (a) Decidual tissue.
- (b) Enlarged blood spaces.
- (c) Degenerated epithelium on surface of mucosa.
- (d) Gland space with epithelium thrown off into lumen and degenerating.  
× 400.

FIG. 2.

Deep or spongy layer from same specimen.

- (a) Uterine muscle.
- (b) Base of gland of mucosa lined with epithelium, which has become somewhat flattened.
- (c) Gland spaces with lining epithelium largely cast-off and degenerated.
- (d) Connective tissue trabeculae between gland spaces.
- (e) Small artery.  
× 60

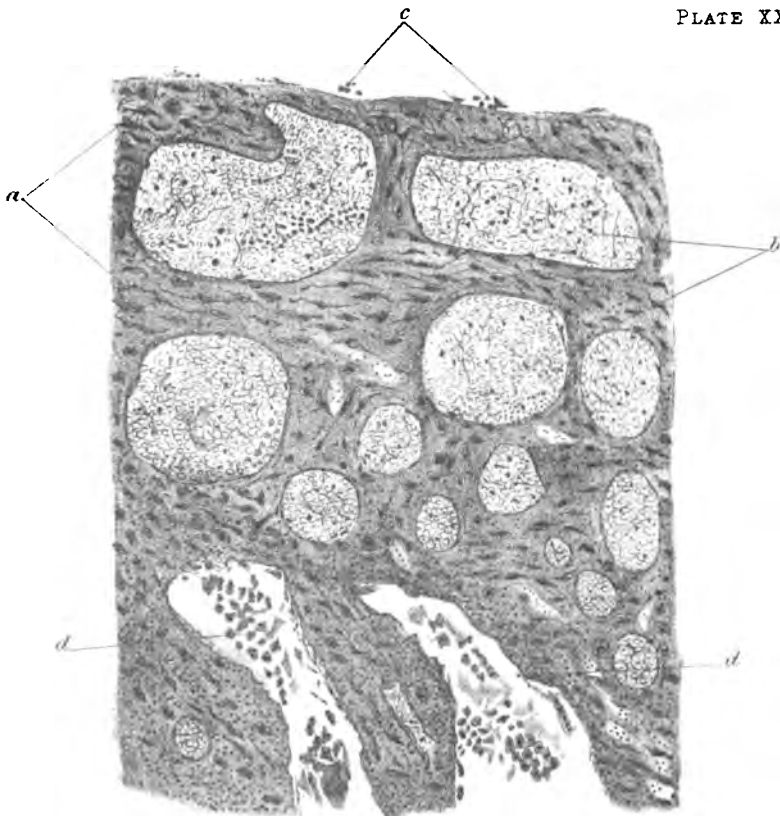


Fig 1.

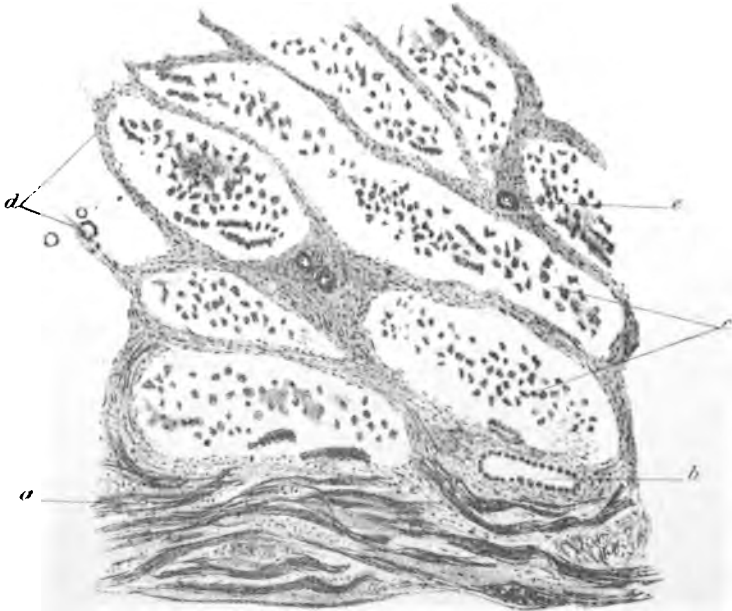

Fig 2.