

ADENOMYOMA OF THE ROUND LIGAMENT.

BY THOMAS S. CULLEN, M.B. TOR.,

Instructor in Gynecology in the Johns Hopkins University; Assistant Resident Gynecologist
to the Johns Hopkins Hospital.

ISOLATED cases of adenomyomata of the uterus have been from time to time reported, and recently our interest in these cases has been awakened by the excellent work of v. Recklinghausen, "Die Adenomyome und Cystadenome der Uterus und Tubenwandung," and within the last few months we have had two cases in the Johns Hopkins Hospital.

While adenomyomata of the uterus are not so rare, similar tumors of the round ligament have apparently never been reported.

Leopold described a cystic myoma of the round ligament, and, after carefully examining the tumor microscopically, came to the conclusion that the cyst cavities were dilated lymph spaces.

Aschenborn, in a patient with phthisis, found a tumor the size of a walnut lying in the inguinal canal and springing from the round ligament. It was a thick-walled cyst, and contained clear, transparent fluid. The microscopic appearances were not described.

Coulson had a case closely resembling that of Aschenborn. Roustan describes a case observed by Duplay. Situated over the external ring was a tumor twice the size of a man's fist. This, on section, resembled a cystic testicle. Microscopically the solid portions consisted of non-striped muscle, adipose, and connective tissue. Some of the cyst-like spaces were traversed by trabeculæ. None of the cavities presented any epithelial lining. The tumor was a myoma undergoing degeneration.

The above are the reported cases which at first sight might bear some semblance to the case I report.

CLINICAL HISTORY.

L.N., æt. 37, admitted in the service of Dr. Kelly, Oct. 18, 1895.

The patient has been married thirteen years; had one instrumental labor seven years ago. Her menses commenced at fourteen, and were regular until the birth of the child, since which time they have occurred every three weeks, have been very copious, and have lasted from four to

five days. The latter part of each period has been accompanied by a good deal of pain, which persists for several days after the flow ceases. Last menstrual period two weeks before admission.

Family history. Her father died of paralysis; one aunt and her grandmother died of carcinoma.

Present trouble. About eight years ago the patient noticed a slight swelling in the right inguinal region. This has gradually enlarged, especially during the last two years. She has experienced severe cutting pain in the nodule. The pain radiated to her back, and was most severe after exertion or at the menstrual period. The patient is debilitated; her appetite is moderate; bowels regular. She has a thick white or yellowish leucorrhœal discharge. This is non-irritative, and is not offensive.

Vaginal examination is negative.

The mass occupies the upper part of the right labium. It is irregularly ovoid, and is firmly fixed in the deep tissue; it is, however, movable to the extent of 1 cm.

Operation by Dr. Kelly, Oct. 19, 1895. An oval incision was made over the site of the nodule. The mass was freed laterally and posteriorly. Above, it was closely connected with a band of tissue 1 cm. broad. This proved to be the right round ligament. The round ligament was traced upward to the internal ring. Midway between the external and internal ring it contained a nodule 1 x .6 cm. in diameter. The round ligament was pulled down, clamped, and cut off at the internal ring. Several enlarged lymph glands were then dissected out. The pillars of the ring were brought together by silver wire sutures. The round ligament was sutured into the canal. The canal throughout its entire extent was closed by mattress sutures of silver wire. The incision was then closed with catgut. The patient was discharged on November 3.

ANATOMICAL APPEARANCES.

Pathological No. 928. The specimen consists of a piece of tissue 7 x 4 x 3.5 cm. One surface of this is covered by normal skin, the underlying tissue is composed of fat, embedded in which is an exceedingly firm nodule 3.5 x 3 x 2 cm., Fig. 1.

This nodule on section is composed of interlacing bundles of fibres which form a dense network. Scattered throughout the nodule are many small irregular, pale, translucent, homogeneous areas. On examining the specimen after hardening in Müller's fluid, some of the homogeneous areas are found to contain round, oval, or irregular spaces. Accompanying the specimen are several lymph glands, one of which is 1x. 8 cm.

HISTOLOGICAL EXAMINATION.

The nodule is to a great extent composed of non-stripped muscle fibres which wind in and out in all directions, but do not show any concentric

arrangement. In many places the muscle fibres are swollen, and the cell protoplasm contains large quantities of yellowish-brown granular pigment. At several points the muscle has undergone hyaline degeneration. This is especially noticeable around blood vessels. The blood supply is abundant. Scattered here and there throughout the muscle substance are small islands of adipose tissue. Traversing the nodule in all directions are glands, Fig. 2. Some of these are small and round on cross-section, others are cut lengthwise. These glands are surrounded by stroma similar to that of the uterine mucosa. It would be impossible to distinguish some of these from uterine glands. A few of the glands present slight dichotomous branching. Some of the glands contain round masses of protoplasm, scattered throughout which are several nuclei. These giant cells appear to be cross-sections of tufts of epithelium.

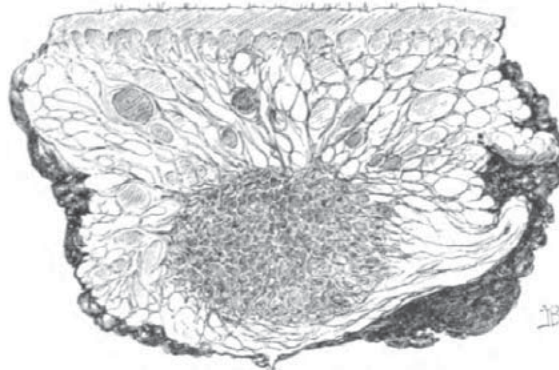


FIG. 1.*—Natural size. Longitudinal section of the tissue removed. The upper portion is skin, and the greater part of the specimen consists of lobules of fat. The round or oval dark areas in the fat are hæmorrhages. Situated in the adipose tissue is the tumor, which consists of muscle bundles. Scattered here and there throughout the muscle are round or irregular dark spaces; these represent the dilated gland cavities. Running into the myoma from all sides are strands of connective tissue.

In many places the glands present a peculiar arrangement, and correspond to v. Recklinghausen's pseudo-glomeruli. These pseudo-glomeruli consist of stroma resembling that of the uterine mucosa. They contain numerous capillaries, and they may have one or more glands situated in their depth. In some places there is hæmorrhage into their stroma. The pseudo-glomeruli are half-moon-shaped, cone-shaped, or irregular in contour. They are covered by one layer of cylindrical ciliated epithelium. What corresponds to Bowman's capsule consists of a layer of cells resting directly upon the muscle fibres. The cells of the capsule opposite the convexity of the glomerulus are almost flat; on passing off laterally they are seen to be cuboidal or cylindrical. The cells of the so-called capsule

*We are indebted to Dr. Henry M. Hurd, editor of the Johns Hopkins Hospital Bulletin, for his kindness in placing these cuts at our disposal.

are directly continuous with those of the pseudo-glomerulus. The space between the capsule and the glomerulus may be empty; many, however, contain desquamated epithelial cells, some of which are vacuolated and contain brown granular pigment. Numerous spaces contain red-blood corpuscles. On tracing one of the spaces laterally it is found to be directly continuous with the lumen of a gland. The capsule forms one wall of the gland and the pseudo-glomerulus the other, Fig. 2. In other words, the space between the capsule and the so-called glomerulus is nothing more than a dilatation of the gland cavity. In numerous places the gland

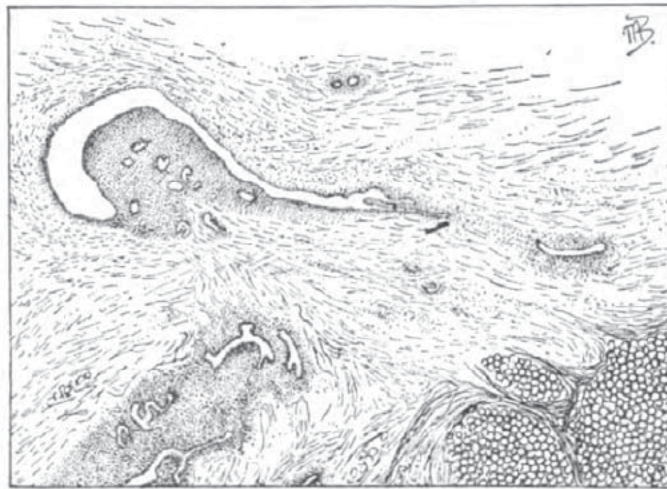

FIG. 2.—Sixteen times enlargement of a portion of the adenomyoma. The specimen consists chiefly of non-striated muscle fibres. In the right lower corner are masses of fat cells, and near the left lower corner are several fat cells. In the vicinity of the left upper corner is a pseudo-glomerulus; this is composed of stroma, scattered throughout which are cross-sections of several glands. The surface of the glomerulus is covered by one layer of cylindrical epithelium, and its capsule is composed of one layer of cells which in places are cuboidal or almost flat. The cells of the capsule have practically no underlying stroma, but lie directly on the muscle fibres. The space between the pseudo-glomerulus and the capsule is, on tracing it to the right, seen to be continuous with a gland cavity, and is nothing more than a dilated portion of the gland. Above and to the right of the pseudo-glomerulus are cross-sections of two glands, below it are several longitudinal sections, one showing dichotomous branching. All of the glands are surrounded by stroma, which separates them from the muscle.

epithelium on one side is found to be cylindrical, on the other side cuboidal or almost flat. On examining this more closely it is found that where the epithelium is separated from the muscle by a moderate amount of stroma it is cylindrical, but that where the epithelium rests directly upon the muscle it is invariably cuboidal or flat.

A few small glands are seen lying directly between muscle bundles. Extending into the myomatous growth from the periphery are numerous bands of connective tissue. The adipose tissue surrounding the myoma shows considerable hæmorrhage. The skin covering the surface of the

specimen is normal. The lymph glands, apart from being somewhat swollen, are normal.

Unfortunately we are not able to obtain the smaller nodule of the round ligament for examination, and cannot say whether it was an adenomyoma or not.

From a clinical standpoint the excessive pain in the nodule at the menstrual period is significant. It leads to the belief that there was some definite sympathetic relation between the uterus and the nodule in the round ligament.

Both v. Recklinghausen and I considered adenomyomata of the uterus non-malignant, and the fact that the nodule in this case existed for eight years and increased very slowly, and at the operation showed no evidence of malignancy, strengthens our belief that these tumors are benign.

The only case in the literature that throws any light on this case is the one reported by A. Martin. A patient, æt. 70, consulted him about a rapidly growing tumor. He opened the abdomen and removed twelve litres of chocolate-colored fluid from a tumor which presented at the incision. This growth sprang from the left round ligament, being connected with it by a pedicle. Pommorsky, who made the microscopical examination, found that the cyst containing the chocolate-colored fluid had very thin walls, and that its inner surface was in places covered by clots. The pedicle of the tumor contained several small cysts which were filled with clear fluid, and which communicated with one another. One of these cysts was lined by low cylindrical ciliated epithelium. Martin says that in this case the structure and contents corresponded to those of tumors arising from the parovarium.

ORIGIN OF THE GLANDS.

The glandular elements in our case correspond very closely to those found by v. Recklinghausen in adenomyomata of the uterus. In those cases he was able to trace a marked resemblance between the tumor glands and remains of the Wolffian body, and came to the conclusion that the glands were derived from this source. While admitting the probability of the glands in our case being due to remains of the Wolffian body, we cannot, from their striking resemblance to those of the uterine mucosa, and from the fact that their stroma resembles that of the mucosa, refrain from suggesting the possibility that they may be due to an abnormal embryonic deposit of a portion of Muller's duct.

LITERATURE.

Aschenborn, "Cystis ligamenti uteri rotundi in canali inguinali dextro." *Arch. f. Klin. Chir.*, Berl., 1880, XXV., 178.

Coulson, "A cystic tumor of the round ligament in a woman." *Lancet*, London, 1859, II., 113.

Cullen, "Adenomyoma uteri diffusum benignum." Johns Hopkins Hospital Reports, Vol. VI. (in press).

Leopold, "Beitrag zur Lehre von den kystischen Unterleibsgeschwulsten." *Arch. f. Gynäk.*, Berl., 1880, XVI., s. 402.

Martin, A., "Zur Pathologie des Ligamentum rotundum." *Zeitschr. f. Geb. u. Gyn.*, 1891, Bd. XXII., s. 444.

Recklinghausen, "Die Adenomyome und Cystadenome der Uterus und Tubenwandung." Berlin, 1896.

Roustan, "Tumeurs du ligament rond." *Montpel. Méd.*, 1884, 2, s. II., 101-121.