

## CASE REPORTS

Association of Thalidomide (Kevadon)  
With Congenital AnomaliesA. E. RODIN, M.D., F.R.C.P.[C],\* L. A. KOLLER, M.D.† and  
J. D. TAYLOR, Ph.D.,‡ *Edmonton, Alta.*

ALTHOUGH the induction of congenital anomalies by prenatal drug administration has been accomplished experimentally,<sup>1,2</sup> the occurrence of this phenomenon in humans has not been proved, even though it has been suspected in the case of tolbutamide and aminopterin.<sup>3</sup> Since December 2, 1961, however, several letters to the editor of the *Lancet* have reported a relatively high incidence of abnormalities in infants of mothers treated with a "non-toxic" sedative, thalidomide (Contergan, Distaval), during the first two months of pregnancy.<sup>4-6</sup> The anomalies include limb defects predominantly, but also cardiac and gastrointestinal anomalies. Recently 10 cases of gross limb defects have been reported from one nursery unit in Scotland in a period of one year.<sup>7</sup> Eight of the mothers are known to have received thalidomide (Distaval), and it was suggested that the other two, as well, had probably used this drug.

The report of one further instance of the association of thalidomide (Kevadon) therapy with congenital abnormality by no means proves the existence of any relationship between these factors, particularly because of the almost indiscriminate use of a multitude of drugs during pregnancy in this case. However, the publication of this case report may further alert physicians in this country to the possible delivery of malformed infants in mothers treated with thalidomide (Kevadon) during their pregnancy. Although the manufacturers, on their own initiative, have recently withdrawn Kevadon from the market in Canada, there have been numerous pregnant women treated with the drug who have yet to come to term.

The mother of this newborn infant was a 31-year-old para 2, gravida 3, whose blood group is O and Rh type positive. She had had rubella as a child. In January 1959, she was admitted to hospital for one week with a diagnosis of cholecystitis. On April 9, 1959, she was delivered of a normal 5 lb. 7 oz. boy. In July 1960, she was again delivered of a normal 7 lb. 7 oz. boy. On April 26, 1961, she was admitted with the diagnosis of acute anxiety neurosis. At that time her urinalysis was normal, her hemoglobin was 12.5 g./100 ml. and

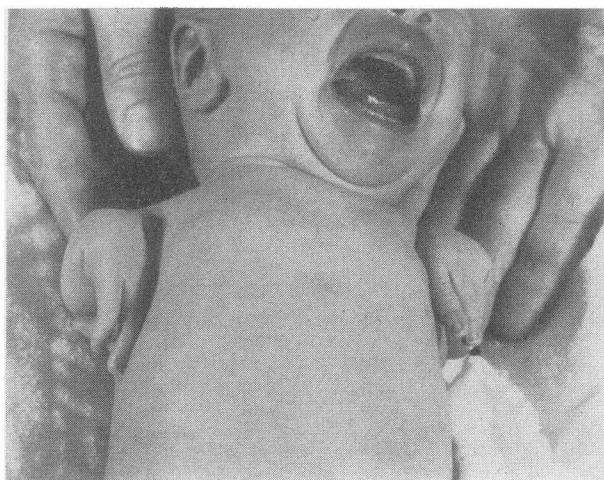


Fig. 1

her white blood cell count was 7821 per c.mm. with a normal differential count. Her basal metabolic rate was minus 13. She was treated with carbromal and pentobarbital (Carbrital), trifluoperazine (Stelazine) and isopropamide and prochlorperazine (Combid Spansule) and was discharged on April 29, 1961.

Her next admission to hospital was on June 1, 1961, for anxiety depression. She received many drugs, including dimenhydrinate (Dramamine), imipramine (Tofranil), trifluoperazine (Stelazine), vitamin B complex (Beminal), amobarbital (Amytal), phenobarbital and insulin. In addition she was given 100 mg. thalidomide (Kevadon) each evening for three days beginning on June 1, with a final dose of 200 mg. During this admission it was discovered that her last

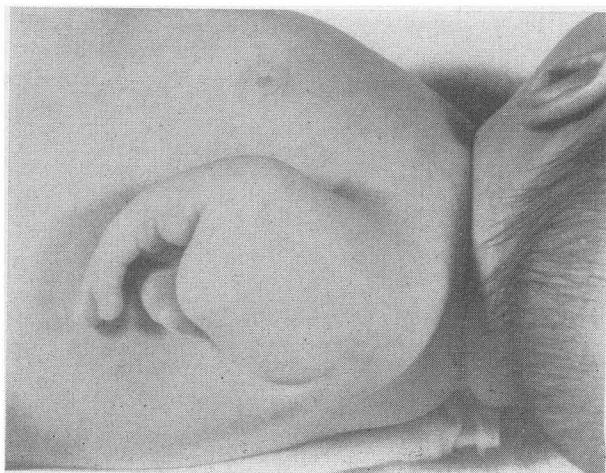


Fig. 2

From the Departments of Laboratory Medicine and General Practice of the Misericordia Hospital, and the Department of Pharmacology of the University of Alberta, Edmonton.  
\*Pathologist, Misericordia Hospital.  
†Member of Active Medical Staff, Misericordia Hospital and M.C.G.P.  
‡Assistant Director, Department of Laboratory Medicine, Misericordia Hospital, and Assistant Professor, Department of Pharmacology, University of Alberta.

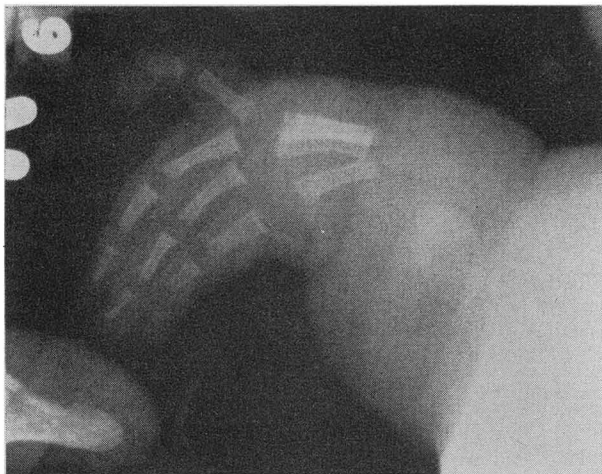

Fig. 3

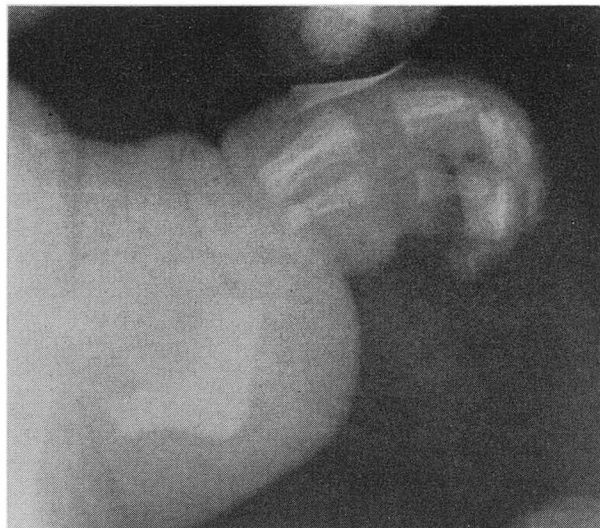

Fig. 4

normal menstrual period had occurred early in April. A frog test performed on June 12 was positive. She was discharged on June 22, 1961.

Her next admission was for labour on January 17, 1962. Meperidine (Demerol) and perphenazine (Trilafon) were given as sedation. After one hour the membranes were ruptured artificially and there was spontaneous delivery in a left occiput anterior presentation of a 6 lb. 2 oz. male infant. During this admission the mother's blood pressure was 125/65 mm. Hg, her hemoglobin was 12.9 g./100 ml. and urinalysis was negative.

The newborn infant was normal in all respects except for absence of a considerable portion of the upper extremities (Figs. 1 and 2). Radiographic examination (Fig. 3) revealed that on the right side the humerus was less than 1.5 cm. in length, the radius and ulna were absent and there were only three metacarpal bones and four digits, the thumb being absent. On the left side (Fig. 4) there were a short humerus, three metacarpal bones and three digits, the thumb and second finger being absent. Both shoulders moved well. The digits of the right and left hand flexed and extended in a normal manner. Radiographs of the vertebral column were normal and no other abnormalities were apparent. Routine serology on the cord blood was negative. The infant was discharged on January 23, 1962, weighing 6 lb. 1 oz.

#### DISCUSSION

Although thalidomide was initially advertised as being a relatively non-toxic antiemetic and hypnotic, there is an increasing body of evidence that points to a causal relationship between its administration during the early months of pregnancy and congenital malformations in the infants of mothers so treated.<sup>8</sup> It would appear that the most hazardous period for thalidomide therapy occurs between the fourth and eighth weeks after conception, at the time when the limb buds are being formed. The dose of thalidomide which is required to produce anomalies is unknown at this time. However, the present case report indicates the possibility that as little as 400 mg. of thalidomide (Kevadon) may be teratogenic if administered during the crucial period of embryological develop-

ment. It is evident that there is no direct proof that thalidomide therapy was responsible for phocomelia in the present case. However, the drug was administered between the fourth and eighth weeks of pregnancy, there are two normal older siblings, and the type of abnormality corresponds with those described in other cases in which its relationship to thalidomide ingestion by the mother during pregnancy was implicated.

The prompt withdrawal of thalidomide from the market by the manufacturers (November 1961 in West Germany, December 1961 in Great Britain, and March 1962 in Canada) may have obviated the birth of many blighted infants, although it has been estimated that about 3000 such incidents have already occurred.<sup>5</sup> However, because of its pronounced initial popularity many women, still pregnant, may be faced with the upbringing of a malformed child. In addition, "samples" of thalidomide (Kevadon) undoubtedly still remain in some physicians' offices and, as such, should be discarded unused. In this way, the modern concept of preventive medicine can be applied to an iatrogenic disease.

By the end of 1962 the problem of thalidomide-induced abnormalities should be resolved because of the rapid world-wide dissemination of information made possible by modern communications. But even more important than the resolution of this one specific example of drug-induced abnormalities is the probability that many congenital lesions may have been related to maternal drug therapy in the past and may be in the future. Although the effects of new products are studied in many animals before release to the medical profession, little consideration has been given to possible teratogenic effects. Unfortunately, physiologic and pharmacologic data cannot be transferred indiscriminately from animal species to the human race. Even more serious is the suggestion that the toxicity of some substances may not become manifested until the second generation.<sup>9</sup> The only reasonable and practi-

cal approach at this time is to withhold all drugs of any description during the first trimester of pregnancy, unless their administration is absolutely indicated.

The authors would like to lend their support to the proposals in a Leading Article in the February 10, 1962 issue of the *Lancet*<sup>8</sup> wherein it is suggested that lists be kept of all drugs given to pregnant women during the first trimester and that these lists be examined critically whenever structural or biochemical abnormalities of the fetus or newborn occur. Furthermore, we would strongly advocate a national or international centre to which such data could be sent by various physicians, for compilation and comparison. This would surely represent an opportunity to apply the non-human electronic computers to a very humane project.

#### SUMMARY

A case of phocomelia occurring in the offspring of a mother who received thalidomide (Kevadon) in the first trimester of pregnancy is reported. Although the association in this case is suspected only, the implications are far-reaching for both present and future generations. A plea is made for the establishment of centres for assimilation of data relating to maternal drug therapy and congenital anomalies.

#### REFERENCES

1. KALTER, H. AND WARKANY, J.: *Amer. J. Path.*, **38**: 1, 1961.
2. WARKANY, J. AND TAKACS, E.: *Ibid.*, **35**: 315, 1959.
3. Leading Article: *Lancet*, **2**: 753, 1961.
4. HAYMAN, D. J.: *Ibid.*, **2**: 1262, 1961.
5. MCBRIDE, W. G.: *Ibid.*, **2**: 1358, 1961.
6. LENZ, W. *et al.*: *Ibid.*, **1**: 45, 1962.
7. SPEIRS, A. L.: *Ibid.*, **1**: 303, 1962.
8. Leading Article: *Ibid.*, **1**: 307, 1962.
9. KALOW, W. AND MARTON, A.: *Nature (Lond.)*, **192**: 464, 1961.